00109545

THE
ASIATIC SOCIETY OF BOMBAY
Town Hall, Bombay.

Digitized with financial assistance from the
Observer Research Foundation
on 25 April, 2019

THE NEW SYDENHAM SOCIETY.

ATLAS OF

CLINICAL MEDICINE, SURGERY, AND PATHOLOGY.

(A CONTINUATION OF THE ATLAS OF PATHOLOGY).

Edited under the direction of the Council

109545
ac

BY

JONATHAN HUTCHINSON, F.R.S., LL.D.

VOL. I.

COMPRISING FASCICULI XIV. TO XX.

TB.d 35

1901—1903.

00109545

LONDON:
JOHN BALE, SONS & DANIELSSON, LIMITED,
OXFORD HOUSE,
GREAT TITCHFIELD STREET, W.

AN

ATLAS OF ILLUSTRATIONS

OF

CLINICAL MEDICINE, SURGERY

AND

PATHOLOGY

COMPILED (CHIEFLY FROM ORIGINAL SOURCES)

FOR

THE NEW SYDENHAM SOCIETY.

PART I. OF FASCICULUS XIV. (DOUBLE NUMBER).

(PLATES A' TO H AND LXXV. TO XCI.)

FASCICULI I. & II. OF ATLAS OF CLINICAL MEDICINE.

LIBRARY OF THE BOMBAY BRANCH OF THE ROYAL ASIATIC SOCIETY

FRAMBŒSIAL SYPHILIS (YAWS AND PARANGI)

WITH DESCRIPTIONS AND A RÉSUMÉ OF PRESENT KNOWLEDGE, WITH COMMENTS.

BY

JONATHAN HUTCHINSON, F.R.C.S., F.R.S., LL.D.

LONDON:
THE NEW SYDENHAM SOCIETY.
1902.

A RÉSUMÉ OF PRESENT KNOWLEDGE

AS TO

FRAMBŒSIAL SYPHILIS, &c.

By JONATHAN HUTCHINSON, F.R.S., LL.D.

THE Coloured Portraits which constitute the second part of this fasciculus are all of them copied from drawings which were executed in Ceylon under the direction of Sir William Kynsey, to whose courtesy the Society is indebted for permission to publish them. They illustrate the conditions which in that island, and also in some parts of India, are known under the name of "Parangi" (= the foreign disease). Those without colour, interspersed in the text or in plates A, B, C, D, E, F, and G, are from various sources, but illustrate the same malady, as it is observed in different regions under different names—Yaws, Frambœsia, Frambœsia tropica, Frambœsial Syphilis, &c.

It cannot be denied that these fasciculi are in some sense a controversial document. They are designed to give to those who may not have seen much of the diseases in question, definite conceptions of their conspicuous features. In addition, however, to the value of these portraits as enabling those who examine them to form their own opinions as to whether or not yaws is to be distinguished from syphilis, they have a high clinical importance. If yaws be not syphilis, they illustrate a disease which is, at any rate, new to our Atlases, and of which but few possess any clear knowledge. If, on the other hand, yaws be simply frambœsial syphilis, they show an exceptional form of this latter malady well worthy of more general recognition. In whichever sense the reader may finally regard them, they must unquestionably supply valuable material in aid of clinical knowledge and accuracy of diagnosis.

To those who are convinced that Syphilis is Yaws and Yaws Syphilis, the present collection of illustrations will be interesting, as exhibiting certain modifications of the latter which are common in the coloured races and not unknown amongst Europeans. To those who accept Yaws as a distinct malady, the plates will be of great value as fixing the type of that disease.

It may be convenient here to state that the opinion that Yaws is a form of Syphilis is not new. It was the doctrine of Sydenham and of most of the older observers, and it is only during the last century that there has been any serious attempt to establish a diagnosis between the two.[1] It may, then, be said that the onus of proof lies rather with those who assert the distinction than with those who deny it. In the following statement the endeavour will be made to hold

[1] Alibert in 1814 wrote of Yaws under the name of Pian. He held that "Pian ruboide" or Yaws of Guinea, "Pian fungoide" or Molucca Pian, and Sibbens of Scotland are "analogous" diseases modified by climate, temperament, &c. The following are some of the opinions he expressed :—

Some forms resemble the more serious results of venereal disease, syphilis, *and this is especially the case with the Scotch Sibbens.*

Pian may affect the bones and cartilages.

There are different varieties—Little Pians, Great Pians, and Red Pians.

Whites are less severely attacked than blacks, and are especially seldom affected by the "Little Pian," which is the most troublesome form.

It is certainly contagious, especially by means of a kind of fly, "the Frambœsia fly."

African negroes are much more subject to Pian than Creole

the balance fairly, and to allow the facts to exhibit themselves and to suggest their own appropriate conclusions.

The New Sydenham Society has already taken some considerable part in endeavouring to supply materials for the solution of this important question. In vol. clxi. will be found reprints of, a "Prize Essay on Yaws," by Dr. Maxwell, published in 1839; an epitome of Dr. Nicholls' "Government Report on Yaws"; an essay by Professor Breda on the Clinical and Bacteriological Study of the Brazilian form of the disease, and lastly, the very important, because experimental, monograph of Dr. M. Charlouis, of Java. This volume contains some good portraits of the skin eruptions, and also a plate from Dr. Breda's paper showing lesions of the mucous membranes, &c. Charlouis' observations, which constitute an epoch in the investigation, were published in 1881, but they were for some years overlooked in England, and the interest which has been manifested in the subject amongst ourselves dates from the publication in 1891 of an essay by Dr. Numa Rat, of St. Dominica, to which the present writer contributed a preface. In 1894 our Colonial Government published a well-illustrated and somewhat voluminous "Report on Yaws," by Dr. Alford Nicholls, then of Dominica. About the same time, and subsequently, many valuable contributions to our knowledge of the subject have been made in the medical journals, and amongst those who have contributed them must be mentioned with honour those of Dr. Daniels, Dr. Powell, Dr. Wallbridge, Dr. Corney, and Mr. Finucane. The last-named observer contributed a most important paper on Yaws as observed in Fiji, to the Standing Committee on Yaws at the Polyclinic. It may be added that, in the Museum of the Polyclinic,[1] a large, and probably almost complete, collection of published illustrations of the disease has been arranged, and is supplemented by many original photographs from various sources.

It may be gathered from what has been said that the literature of Frambœsia is now very large, and, as we have noted, our Colonial Government has felt the great importance of the matter, and has on several occasions procured special reports upon it. It would be much to be regretted if these labours were thrown away, and if we were compelled to record that the solution of the matter appeared to be as distant as ever. But, in fact, it is not so; the issues have been narrowed down and are now quite definite.

It is admitted almost on all hands that if Yaws be not Syphilis it is, at any rate, a specific malady very closely resembling it. It is often suggested that a parallel may be found in the differences between Measles and German Measles, and the controversy concerns the question whether the observed differences in outward phenomena are such as to imply distinctness in nature. That both observe stages which may be suitably named as "primary or local," "eruptive or secondary," and "sequelæ or tertiary," is now determined beyond dispute.

The first subject for our consideration is:—

The Period of Incubation after Inoculation.

From Dr. Mason Good we have the following statement:—

"The time that elapses between the inoculation with Yaw matter and the first appearance of a Yaw tubercle on the spot where the

negroes. Bontius observed it specially in Amboyna and the Molluccas.

It occurs only once in a life-time.

It can be distinguished from syphilitic eruption especially by its "insupportable itching."

When the venereal disease and Pian occur together, however, it may be very difficult to distinguish the two diseases.

Children are more subject to it than adults and old people.

Loeffler observes that persons with open wounds are more likely to get Pian than others, and the negroes are "habitually covered with wounds and ulcers."

Dr. Mason Good in 1822 wrote (p. 431): "It is singular that we have no decided account of this malady among the early writers; nor, indeed, any account whatever till after the appearance of syphilis; whence as several of its symptoms, and especially where the bones become affected, bear a resemblance to those of syphilis, Yaws have been supposed by some writers to be a species of lues, and especially of that which in Scotland is denominated sibbens or sivvens . . . . but the eruptive fever and consequent efflorescence, the indemnity from a second attack, as well as the symptoms, draw a sufficient line of distinction."

[1] This Museum, at 22, Chenies Street, may be visited at any time.

FIG. 1.—The primary sore of Fijian Yaws with satellite eruption. (From a photograph by Dr. Corney.)

FIG. 2.—Three primary chancres from tattooing in an Englishman. They were raised and firm. (From photograph given by Mr. Crossley Wright, of Halifax.)

THE PRIMARY SORE IN YAWS (FIG. 1) AND IN SYPHILIS (FIG. 2).

matter was inserted, was found to be about three weeks. A dry scab was first formed, that remained stationary, and under it the Yaw fungus became perceptible at the end of about three weeks, and soon afterwards other tubercles appeared on the body."

The experiments of Charlouis, who inoculated with yaws secretion a considerable number of Javan natives, put the facts, as regards this period and the primary and secondary stages, in the clearest possible light, and it is to be hoped that they will never be repeated by anyone. It may be best to quote his own words, premising that he is not an advocate of identity. He writes:—

"Undoubtedly framboesia resembles syphilis in many respects.

"(1) Both are contagious diseases.

"(2) Both are due to a fixed contagium.

"(3) In both the incubation[1] lasts from three to six months.

"(4) Both diseases commence with fever and pain in bony structures.

"(5) Both manifest themselves by cutaneous infiltrations.

"(6) General glandular inflammation occurs in both diseases.

"(7) Both are cured by the same drugs."

It may be convenient if we now divide our subject according to the several stages of the disease, and take first

THE PRIMARY SORE.

In many cases this is never recognised, but no one who correctly estimates the bearing of Charlouis' experiments can doubt that it is always present. The patient usually does not come under observation until the eruption is fully out, and in very many recorded cases no attempt appears to have been made to find the site of inoculation. Such terms as the "mother yaw," the "mamma," the "grande," &c., and others which are in popular use in countries where yaws is prevalent, sufficiently attest the observation that a primary sore is usually observed. None of those who have published pictorial representations of yaws have, so far as we are aware, given illustrations of the primary sore. The appended illustration is perhaps the first which has been offered. It is copied from a photograph given to the writer by Dr. Corney, who wrote:—"I enclose you a photograph which I took some years back of a case of primary Coko granuloma surrounded by smaller ones, like hen-and-chickens. It was in a Swede who had acquired it in Fiji."[1] (Fig. 1, plate A.)

Charlouis does not describe the accidental primary sore other than to say that "the names 'mammy' and 'grandy' are assigned to the fungous tumours developed at the seat of inoculation and preceding the general eruption." He adds that Thompson, Paulet, Boyle, and others refuse altogether to admit the existence of the "mammy yaw." He gives us, however, invaluable evidence as to its character when produced intentionally.

His descriptions of the sores which resulted from his experimental inoculations are, *mutatis mutandis*, of course applicable to the primary lesion when produced by accident. He inoculated at the same time thirty-two persons, none of whom had ever had yaws before, and of these only four failed. The following is his description of the results:—

"After the lapse of fourteen days after the inoculation, small papules were always seen (except in four cases) at the seat of injection. These papules had red areolæ, and were very painful, but the temperature of the skin in their neighbourhood was only raised half a degree. Pustules gradually developed from the papules, and this change took place about twenty days from the inoculation. The pustules extended more widely and became so painful that the patient could no longer endure a shirt on account of the friction which it caused. The crusts of the pustules also

[1] By "incubation" is here meant the interval before the full development of the eruption. Charlouis proved that the incubation of the primary sore was usually less than a month.

[1] It may be noted that this development of satellites around the primary sore is not unknown in syphilitic chancres. It sometimes precedes the secondary eruption and sometimes is a part of it.

increased in size, became irregular on the surface, and assumed more the appearance of oyster shells.

"After the crusts had been formed for some time I removed some of them in order to see the underlying condition. Deep ulcers with mottled floors and undermined and thickened edges were exposed. There was little purulent secretion. The appearance was that of an *ulcus molle*. The patients complained of painful glandular enlargement in the axilla of the corresponding side, and the whole region between the ulcer and the axilla was intensely tender.

"Some of the ulcers gradually assumed a fungous character, whilst others again healed, leaving *always a thick, hard, whitish scar*. Those of the first kind, on the other hand, developed into raised tumours, which presented exactly the appearance of frambœsia tubercles. In the majority of patients the earliest appearances of frambœsia showed themselves after three months, but in some instances after four months, and before the initial phenomena had come to an end.

"Of these initial phenomena fever commencing with rigors was the earliest. The temperature rose in the evening to 39°C., but the patients were for the most part free from fever in the daytime.

"The fever began about a week before the eruption and lasted a fortnight altogether. At the same time the pains in the bones appeared, and were of such severity that the patient could scarcely move. The pains were increased by pressure, and were specially localized in the joints, which, however, did not exhibit the slightest swelling. A slight local rise of temperature was in most cases observed. The pains, which never extended along the course of the bones, persisted day and night and lasted until a short time after the appearance of the eruption, but they soon disappeared under suitable treatment. The patients also suffered from gastric disturbances, and got but little sleep.

"The eruption followed one of two courses; the patients either developed small frambœsia tubercles around the tubercle at the seat of inoculation, or completely isolated tubercles were formed. These tubercles gave rise to much pain and acquired the characteristic yellow crusts, spotted with red.

"For three weeks the severe pains and feeling of tension in the tubercles persisted, and afterwards new tubercles were formed in succession, which were quite painless. I am unable to explain why it is that the earliest tubercles are attended by pain whereas the latter are not. I did not observe that the frambœsia tended to make its first appearance on any particular part, but the first tubercles appeared now on one part of the body, now on another. At the commencement of the eruption the patients also complained of tenderness and swelling of the glands. I noticed that, as is the case in syphilis, the lymphatic glands corresponding to the seat of inoculation were the first to swell and become painful and were much more swollen than those in other situations. On the basis of these observations, I have always sought in cases of frambœsia for some specially large gland, in order to obtain a clue to the manner and situation in which the frambœsia poison was originally introduced into the body."

It is impossible to read this description without observing how closely the phenomena coincide with those of syphilis. This is, indeed, fully admitted by the author, although he persists in designating as an "*ulcus molle*" a sore which he himself describes as leaving "always a thick and hard scar." More especially should Charlouis' results be compared with those resulting from the accidental inoculation of syphilitic virus in the course of vaccination.[1] It is a great mistake to suppose that the primary sore which constitutes an erratic chancre—that is, of one occurring on the skin of some part of the body other than the genitals—is usually a typically indurated one. It may vary very much in character, from a small, and quite transitory papule to a large persistent ulcer with much inflammatory swelling, but only in very few cases does it assume the features

[1] See "Illustrations of Clinical Surgery," plates and descriptions.

so well known in the indurated sore as we are accustomed to see it in the mucous membrane of the male prepuce. As is well recognised, it is even rare to see typically hard sores on any part in women. The chancres which occur on the skin, whether from vaccinal or other accidental inoculation, not unfrequently fungate and become raised above the surface. A good illustration in proof of this occurs in Plate XXIII., page 138, Vol. I., and a somewhat similar condition appears to be shown in the fig. 2, plate A, showing three chancres on the forearm from tattooing. It can scarcely be necessary to point out that had such sores as these occurred in a Yaws district they would have been regarded as very characteristic lesions; but they were syphilitic chancres.

Dr. Powell writes of the primary sore: "A papule makes its appearance usually in an old sore or recent scar, such as an ulcer, leech-bite, vaccine mark, or itch pustule. This rapidly develops into a moist yellow fungoid tubercle of granulation tissue. Shortly afterwards, usually within ten days, or possibly *pari passu* with the initial lesion, a similar eruption appears on the body generally."

In 1881, Sir William Kynsey published a Government Report on the Parangi Disease, which contained numerous case narratives, given with the greatest care. These narratives are of not less value than are the excellent drawings with which he has enriched the pictorial literature of this subject.

They were written before the days of acute controversy, and record the unprejudiced observations of one well qualified both to see and to describe. We cannot, therefore, do better than to select from these narratives those parts which mention the primary lesion. They are doubtless equally applicable to the conditions which have been recognised as the initial stage by many other observers in different parts of the world; and which would have been so by all had careful enquiries been made.

From these cases we will select such portions as bear upon our present topic, the illustration of the primary sore. It is to be fully recognised that we can give only detached fragments. The reader who wishes for details must go to the original. Our abstracts are fair ones, but they, of course, omit many details.

In Kynsey's Third Case (p. 37), an infant, 2 years old, suffered from scabies in a village in which parangi was present.[1] At two places, the left great toe and the right knee, ulcers which would not heal were left after the scabies was cured. In this instance the primary sores persisted after the secondary eruption had appeared, and were present, together with the latter, when the child came under observation. The secondary eruption is carefully described. It covered every part of the body except the head and parts of the hands and feet. It had come out in successive crops. It consisted of hard-raised tubercles covered with a very thin scale or crust, which took a long time to peel off. Its earliest stage was "a small, round, solitary papule, white, dry, smooth and glossy."

In Case 4 the child had, as its first symptom, "a small pimple or papule on the back of one knee-joint."

In Case 6 the primary sore was an ulcer on the outer aspect of the upper third of the right leg, which was followed by three successive crops of eruption from which the boy suffered for three years. Twenty years later he had destructive disease of nose and palate, ulcers on both legs and severe pains in various bones.

In Cases 6, 7, 8, and 9, an ulcer on the leg was the first symptom.

In Case 11 there was an ulcer on the inner side of one ankle, which persisted after the secondary eruptions appeared, and "became large and very unhealthy."

In Case 13, a boy, aged 14, said that he had had an ulcer on the left outer ankle, and that when it healed a general eruption appeared. He reported: "About four years ago my younger brother got a sore on his left shin from scratching. This sore got well in due course, and shortly after he became

[1] It may be here remarked that in many places where Yaws occurs scabies is common. The sores caused by scratching appear to be not infrequently the sites of the primary ulcer. This coincidence of the two maladies often causes the belief that secondary eruptions of Yaws are attended by itching.

covered with this kind of eruption. He added that almost all in the village had suffered from the disease.

In Case 14, the father of a child aged 2, was, whilst suffering from the disease, accustomed to carry the child about. "The child made a sore on the outside of the right leg by scratching violently, and it took nearly a month before the sore healed. Directly the sore healed, a crop of eruptions appeared on the nates and in the cleft between them, then the backs of the thighs, the belly, and the face became affected. When the child was admitted at the hospital she was covered with an eruption of the moist variety. About the middle third of the outer side of the right leg there was *a dense reticulated cicatrix which occupied the site of the initial sore*." The child rapidly improved under mercurial treatment.

In the fifteenth Case, p. 45, the description of the primary sore is of exceptional value. The patient was a married woman aged 30. "About eight months ago her child, who was still at the breast, contracted parangi from one of his playmates, and the eruption appeared well developed round and about his mouth. The eruption was partly of the rupial and partly of the condylomatous character. The woman, unmindful of the consequences, although she was well aware what they were, permitted the child to take the breast as usual. After a time a boil, as she calls it, developed about the nipple, broke, discharged matter, and ulcerated. The sore eventually, after a course of native treatment, healed, and its place is now occupied by *a large dense cicatrix*. . . . . It took the sore three months to heal over, and directly this was accomplished a crop of eruptions appeared on the face, preceded by slight fever, loss of appetite, malaise, and pains in the larger joints for a day or two."

The following extract, which describes the early stages in Kynsey's Sixteenth Case, is, like the preceding, of great interest. It concerns a strong, healthy man of about 50 years of age. His youngest child had contracted parangi eight months before from playing with other children who had it. She had an eruption "of the moist, condylomatous kind," which had not wholly disappeared at the date of the notes. The father used to carry the child about. Two months after the beginning of the child's illness he made a sore on the left side of the neck by scratching a pimple which had formed there. The sore got well in about fifteen days, though he took no medicine for it. Just as the sore was healing, he got an attack of fever, attended by pain in the back and large joints, and after this an eruption followed.

We take, lastly, Case 20, recorded at p. 50, concerning which it is stated that the disease "commenced as a papule on the left leg," which, after assuming a tubercular form, underwent changes similar to those described in another case, "ulcerated and left the scar which the patient points to as the commencement of the disease." The scar is described as very distinct and nearly as large as a five-cent piece. It was followed by the usual eruption, which came out in successive crops and on disappearance left stains. The tonsils are said to have been slightly enlarged. Others in the village were suffering from the same disease. Sir W. Kynsey remarks, respecting the case, that it should certainly be placed with the yaws of the West Indies, which it resembles in all respects.[1]

Mr. Daniels writes: "The only case of which I had definite history was that of an incised wound which looked suspicious three weeks after the injury, and was a decided yaws tubercle two weeks later. The general eruption was about a month after that. In two others the period of incubation was under two months." This is a most important statement,

[1] It is somewhat startling to find recorded in Dr. Nicholls' report the following: "Jane Williams, a Creole, aged 16 years, was perfectly healthy, and unexposed to any source of contagion until deflowered by a man in March, 1891. Fourteen days after this she found some tubercles on the vulva and inside of thigh for which I admitted her into the Yaws Hospital."

Dr. Nicholls is not himself responsible for this diagnosis, which is that of one of his correspondents, Mr. W. Boyd, of Grenada. He gives it, however, without any criticism, and it may serve well to show the kind of case to which the term "yaws" is applied in the West Indian Islands and about which he writes. His only motive for printing is apparently that it is supposed to illustrate the period of incubation of yaws. Dr. Nicholls may be assumed to be responsible for the selection of the extracts which he publishes. See Nicholls' Report, p. 178.

FIG. 5.—A copious frambœsial eruption occurring during secondary syphilis in an Englishman. (From a photograph taken for Mr. Hutchinson. See "Archives of Surgery.")

FIG. 6.—The secondary eruption of Yaws (frambœsial). (From a photograph by Dr. Corney.)

FIG. 7.—The frambœsial eruption of Yaws in a European infected in Fiji. (From a photograph by Dr. Corney.)

FIG. 8.—Secondary eruption in West Indian Yaws. (Copied from a photograph given by Dr. Nunns Rat.)

for the intervals coincide exactly with those observed in syphilis.

Thus, then, we have it conclusively established by the experiments of Charlouis that between the date of inoculation and the appearance of a characteristic primary sore there usually intervenes a period of from three weeks to a month, and that enlargement of the proximal lymphatics soon follows. Dr. Daniels corroborates. Sir William Kynsey's cases which concern accidental inoculations are also in accord. In several instances a dense hard cicatrix is described as having resulted from the primary sore, and in several others it is mentioned that this latter was difficult to heal. In not a few the secondary eruption began to appear before the primary sore had gone.

We may now pass to the description of the phenomena of

THE SECONDARY STAGE.

It has been noted already that one of the most recent advocates of the belief that there is a disease which is to be known as "Yaws," and which is distinct from syphilis, alleges that in yaws a generalised eruption is the first stage. Dr. Alfred Nicholls is, however, probably almost alone in his opinion that yaws is distinguished from syphilis by the absence of the primary sore. Most other observers admit that although the infecting sore often escapes observation, we must take for granted its invariable occurrence. Charlouis' experiments are conclusive on this point, and enable us to establish the length of interval between the infection and the appearance of definite characters at the site of inoculation, and also that between the latter and the advent of a general eruption on the skin; the former is about a month, more or less, and the latter two months. We have now to describe the character of the general eruption and its course of evolution and decline. For this purpose we have abundant and trustworthy data, not alone in careful verbal descriptions, but in published portraits. Not a few of the latter are photographs and beyond appeal.

Some of these portraits show the eruption as consisting of papules covered with scale crusts, scattered symmetrically over all the limbs, the face, and the trunk. Others—and these are those which are supposed to portray the peculiar features of the disease—show fungating excrescences on various parts, more especially near the mouth, on the forehead, and on the feet. These granulation-masses may, however, occur anywhere, and entirely replace the original papular eruption. They constitute the framboesial stage, and give a name, or names, to the malady. They are usually covered with a dirty, yellow pus-crust, on the removal of which an excrescence and not an ulcer is revealed. In this feature they differ from all eruptions properly called rupia. It has naturally happened that almost all the photographs and other illustrations of yaws which have been produced exhibit this stage of the eruption and not the earlier one. It is this which is not only the most characteristic but by far the most conspicuous, and lends itself best to the camera and the artist's pencil.

The great gain which will, it is to be hoped, accrue from the present publication of portraits, is that it will henceforth be clear that those who have written about "yaws" in different parts of the world have, for the most part, been dealing with the same class of phenomena. Hitherto it has been possible for an authority in one district to discredit the observations of an observer in another, by suggesting that they were not writing about the same malady. Thus Dr. Nicholls in the West Indies has rejected the descriptions of Sir William Kynsey[1] in Ceylon, and the latter

[1] The following extract is taken from the *Polyclinic Journal* for December, 1901: "Dr. Collingwood next stated his experience of Yaws as observed by himself in Fiji, Samoa and Ceylon. He said that unquestionably most of the phenomena were not to be distinguished from those of syphilis. Tertiary symptoms, lupoid ulcerations, gummata, destructive ulceration of the nose and throat were common. In Fiji the natives imported very large quantities of iodide of potassium to relieve them of the periosteal nodes from which so many of them suffered. He had seen syphilitic teeth. It was true that the primary sore was but rarely recognised, and that the disease was usually contracted in youth. He agreed, however, with what Mr. Hutchinson had just said as to the difficulty of diagnosing primary sores on other parts than the genitals and this, he felt sure, was the explanation of the circumstance that the first stage of 'yaws' was so often overlooked.

"Sir William Kynsey said that after the evidence which had

has been willing to admit that the disease so long accepted as typical "yaws" in Fiji, is not yaws at all but really syphilis. It has even been suggested that Charlouis in his experiments was in reality dealing with syphilis and not with "true yaws." At one time Dr. Nicholls was inclined to think that Fijian yaws was not the "true" disease, but more recently he has been willing to accept it as such. Close on his acceptance, however, has followed certain statements by Mr. Finucane and others, which have induced Sir William Kynsey to say that it must be syphilis.[1] The portraits now given will, we may trust, make it quite evident that the conditions described by Nicholls in the West Indies, Kynsey in Ceylon, and the Fijian and West African observers in their respective districts, are essentially the same in character and that they belong to the same disease. We may therefore safely allow the facts recorded by each observer to supplement and elucidate those of others. We are thus saved from a double dilemma of supposing either that true yaws occurs only in the West Indian Islands, and that the affections mistaken for it in Fiji and Ceylon are really syphilis, or that there exist in each of these localities distinct diseases very like each other and all very like syphilis, but being each in reality *sui generis*.

It will now be convenient to quote some of the descriptions which have been given by different authors of the secondary eruption of yaws.

Dr. Nicholls writes: "The eruption is of three forms, which are now usually designated squamæ, papulæ, and granulomata. They are simply, however, three stages of one eruption, the squamæ developing into the papulæ, which in time becomes the granuloma. But by abortion, one stage may persist as a distinct eruption, or all three stages may be seen in the same individual at the same time, from the commencement to the decline of the disease."[1]

It is surely after such a statement impossible to hold that the eruption of yaws is not polymorphous, or that it is always essentially granulomatous.

FIG. 3.—The early secondary eruption. Photographed from fig. 9 of Nicholls' "Report on Yaws," where it is described as showing "the maculæ or squamæ patches—'Dutroc.'"

Manson (p. 467) writes: "when the eruption is persistently squamous or papular," thus clearly implying that it is not invariably frambœsial.

Charlouis[2] writes: "The skin affection develops gradually; there first appear here and there upon the body, papules of the size of pins' heads, with yellow points at their summits. Later on the papules acquire dark areolæ, which in patients with white skins are red in colour." . . . "The frambœsia

been adduced he thought there could be no doubt that the Fijian disease called Thoko and hitherto confounded with 'yaws' was really syphilis. He held, however, that the Ceylon malady was different.

"Dr. Collingwood replied that he had seen the disease in both countries, and could assure Sir William that it was the same."

Concerning Parangi of Ceylon, Dr. Nicholls thus expresses himself: "On comparing the symptoms as detailed above with those of yaws, it will be seen that the two diseases are totally different. The chief diagnostic sign and one that at once separates yaws from parangi is that of ulceration; parangi is essentially an ulcerative disease, whilst yaws is not. Again, the chief attribute of yaws, the granuloma, is absent in parangi."—Nicholls, p. 298. It is to be observed that the absence of ulceration and the presence of granulomata are facts asserted just as clearly by Dr. Kynsey as to parangi, as by Dr. Nicholls as to yaws. It is probable that in neither case are the conditions invariable.

[1] See *Polyclinic* for December, 1901.

[1] *See* page 318 of vol. xvi. "Twentieth Century of Practice of Medicine."

[2] Page 293, *et seq.*, New Syd. Soc., vol. clxi.

FIG. 9.—Menika; early secondary eruption in Parangi (Vaws of Ceylon). (From a photograph taken for Sir William Kynsey.)

FIG. 10.—Menika; back view of same patient as fig. 9. (Sir William Kynsey.)

FIG. 11.—Protracted secondary eruption in a native of Assam; fourteen months from onset, and after eight months' interrupted treatment (with salivation.) Eruption almost rupial. (From a photograph given by Dr. Powell.)

FIG. 12.—A late secondary eruption in a native of Assam. (Photograph by Dr. Powell.) At the date of report "not a scar was left."

PLATE C.

CASE ILLUSTRATING THE SECONDARY STAGE OF YAWS.

The following case-narrative (which the appended plate illustrates) is of especial value, on account of the fulness of the details. The scar of the original sore is seen. Both the photographs and the description have been supplied by Sir William Kynsey. The patient was a boy named Kiri Banda.

Kiri Banda. 8 years, Sinhalese, male; no occupation. Admitted to the Government Civil Hospital, Kandy, on the 20th November, 1889, for parangi.

Duration of attack, three months previous to admission. In fair health on admission. It is a first attack.

He never suffered from any form of venereal.

He was vaccinated some years ago. The disease appeared long after vaccination.

A well-nourished Sinhalese lad from Tumpane, admitted with eruptions of parangi. The disease commenced with an injury to left side of abdomen, about two inches to left of, and a little below, umbilicus, caused by his falling on a pointed stick six months ago; the wound ulcerated. Three months after, when it was healing, eruptions appeared on left arm and forearm, back, right axilla, left axilla, right elbow, scrotum, and both thighs. On face he had eruptions on right eyelid and upper lip.

On admission he had the following eruptions: On the right side of the chin, a dry, yellowish brown scab; on the right eyelid, two small eruptions like acne; just above fold of left axilla, a yellowish brown scab, tapering to a cone like rupia; a little to the right of this, a soft yellow scab; near the bend of the left elbow, a crop of eruptions, eight in number, covered with soft, yellow scabs. Two eruptions in front of left forearm, about the middle, one covered with a brownish yellow scab; in the other the portion of the scab has dropped off, revealing a pigmented cicatrix. There are a number of pigmented spots on the front of the forearm below these eruptions. There is a brownish yellow scab at the bend of the right forearm. On the front of the right shoulder there are a number of pigmented circular spots. The palms of the hands are quite free from eruptions. On front of left thigh, about the middle, there are three or four scattered eruptions covered with brownish yellow scabs. On the right thigh, about the same level, there are three eruptions, two covered with scabs; in one the scab has almost entirely dropped off, revealing the usual pigmented discoloration. There are three scabs on front of each knee and one on front of left leg, about middle; the feet are free from eruptions. There is a well-marked circular eruption on lower part of scrotum, about the size of a shilling, covered with a soft, yellow scab. There are three yellowish-brown scabs round fold of axilla posteriorily, one on back of right arm, above elbow; a crop of small eruptions like acne round back of elbow, and two eruptions on back of right forearm, about its middle, in which the scabs have partially dropped off.

There is a soft, yellow scab on back, just above right hip. Two eruptions on inner side of axilla posteriorily; in one the scab is dry, in the other partially dropped off. There are also three scabs on the back of the left arm and one on left wrist. One yellowish brown scab on right buttock, with a number of acne-like eruptions round it. A cluster of circular eruptions on inner side of right thigh and two small scabs on back of right knee. A number of pigmented spots on back of both knees and legs.

There is no sensation in the dry eruptions when pricked with a pin, but he feels the slightest touch in the soft, yellow scabs. The soft scabs are itchy and also some of the dry ones. The skin between the eruptions is healthy. The teeth are well formed and white; one of the lower incisors has lately dropped.

There is no sweating of hands and feet. His appetite is good and he sleeps well.

There are several cases of parangi in the village. His father is dead; his mother is living, and he has a brother five months old; they never had parangi. He suffered from pain in the joints before the eruptions appeared. Had no fever.

He ascribes the disease to his having played with boys who had parangi and to having bathed in the river with them.



FIG. 9bis.



FIG. 10bis.

THE ERUPTION OF YAWS (PARANGI). From Sir W. Kynsey's photograph.

papules undergo a gradual increase in size, and especially in breadth. The surface is covered with a honey-coloured crust, which usually shows specks of red. The enlarged papules develop into oval tubercles, and eventually assume the form of the head of a champagne cork." . . . "About the anus, mouth, and penis, and on the fingers and toes the tubercles may coalesce in such a way as to form a raised circular wall." . . . "The appearance resembles that of a raspberry." . . . "After the lapse of weeks, or even months, the tubercles so far undergo involution that there remains nothing visible but a dark spot with sharply-defined furrows, and enlarged orifices of hair-follicles and sebaceous and sweat glands. Later on, within a year at most, these spots also disappear." . . . "Framboesia may affect an individual for a long time and ultimately undergo spontaneous involution. Its course is greatly curtailed by appropriate treatment,[1] and should not exceed a few months. One may speak of the course of framboesia as extending over years, in the sense that whilst one tubercle heals fresh ones are developed in other situations. . . . Framboesia of the toes is attended with softening of the tubercles and fœtid sweating."

Wallbridge and Daniels write: "No doubt most people on seeing their first case of yaws without knowing of its existence in a country would think as I did, that 'this must be a syphilide, though I never saw one like it.' When, however, instead of one you meet with hundreds all alike, its recognition as a distinct disease is easy, and once the characteristic appearance is known, diagnosis is unmistakable in most cases." These statements may be read as implying merely that the framboesial eruption of syphilis is a very definite one, easily distinguished from others, and that it is of common occurrence in the negro races. The authors continue: "The chief distinguishing feature to our minds is the uniformity in all essentials of the eruption all through the disease." This uniformity is denied by Nicholls.

[1] At another place Charlouis writes: "The best treatment is by the combined use of mercury and iodide of potassium."

The portrait copied in fig. 5 of plate B represents an eruption which occurred in a young man who had at the time an indurated chancre. The eruption was most abundant and distinctly framboesial in character. It disappeared under mercurial treatment and left only stains. There could be not the slightest doubt that it was syphilitic, nor any that it precisely resembled the eruption claimed as distinctive of yaws. Another case equally well marked was the subject of a demonstration at the Polyclinic in 1901, and others have been described by Petrini, of Galatz,[1] Amicis, of Naples, and others. It was

Fig. 4.—Note sur une observation des syphilides framboesiformes, végétantes cutanées généralisées (papillomes syphilitiques). Par Prof. Dr. Petrini de Galatz, à Bucarest.

probably cases such as these which gave character to the maladies described as "sibbens" in Scotland, "button scurvy" and "morula" in Ireland.

In order to facilitate comparison we have placed by its side another photograph, which was given us by Dr. Corney (fig. 6). It illustrates a Yaws granulomatous eruption in a native of the Solomon Islands, aged 24, the disease having been acquired in Fiji.

Our next portrait is one which again represents the secondary eruption of Yaws as seen in Fiji. It is from a photograph given to the writer by Dr. Corney. It

[1] See for references New Syd. Soc., vol. cxi., page 298.

represents probably an unusually severe case, and one in which no treatment had been adopted. The eruption is in the main frambœsial. The patient was not a patient of Fiji, but of the New Hebrides. He had, however, contracted the disease in Fiji, where Yaws is but rarely seen in adults Fig. 14, plate E.

It is a matter of general observation that affections of the mucous membranes are much less common in the secondary stage of yaws, as observed in the tropics, than they are in syphilis as seen in Europe. They do, however, occur occasionally, and might perhaps be found oftener if they were carefully looked for.

Thus Kynsey, the accuracy and detail of whose observations are above praise, records in his sixteenth case that "at the base of the tongue among the circumvallate papillæ there were two ulcers exactly like the eruptions on the body."

A few cases occurring in London hospitals have from time to time been somewhat dubiously diagnosed as yaws. They have, of course, all been in those who had resided in the tropics and were of dark skin. In all the symptoms presented were of the late or tertiary class. I am not aware that any cases in the secondary or eruptive stage have ever found their way to England, with the exception of two, which I have myself seen and recorded.[1] Both of these were in Europeans who had contracted the disease in Africa. In one of them the patient, a surgeon, Dr. Hamilton Boyden, had been inoculated by the needle of a hypodermic syringe, and in the other the primary sore had occurred on the wrist, but the source of inoculation was unknown. The two cases ran a closely parallel course. In each there was in the early stage an abundant frambœsiform eruption which had for the most part passed away at the time of the patient's arrival in England. In both this eruption, under interrupted specific treatment, was followed by a mixed one, which showed no granulomata whatever. There were peeling patches in the palms and soles, and desquamations and papules on various other parts. In neither case did I at the time that I saw the patient feel any hesitation in diagnosing syphilis. Mr. W., one of the two, attended at the Ipswich meeting of the British Medical Association, and the President of the Tropical Diseases Section having requested a vote from those present as to whether the conditions then existing should be regarded as syphilitic, it was unanimous in the affirmative. These conditions are somewhat imperfectly represented in plate 91[bis]. This patient had suffered from malaria, and at one time had jaundice and a very large spleen. Owing to interruptions in the treatment, he had several relapses of eruption; but finally, under mercury in combination with quinine, he got rid of all symptoms of his syphilis, and quite regained his health. Dr. Boydon has recorded his own case in detailed narrative in a recent Navy Medical Report, to which I must refer the reader.[1]

During a recent visit to South Africa, I made especial enquiries for cases of yaws. The almost universal testimony was that no disease of that kind existed which could be differentiated from syphilis. The only case which I saw in which the diagnosis of yaws had been suggested was that of a Hottentot man, an in-patient in the Government Hospital at Durban. In this case one medical observer had diagnosed syphilis, and another inclined to name it yaws. The man had undoubtedly a well-characterised and abundant frambœsial eruption, and he had an equally well-characterised scar of an indurated chancre on his prepuce. He was under mercurial treatment, and both the eruption and the sore were rapidly disappearing. I was informed at Durban that an instance had occurred of transference of yaws by vaccination. A large number of the occupants of two adjacent Kaffir kraals who had been vaccinated together from the same source had subsequently suffered outbreaks of yaws. It was the character of

[1] See "Archives of Surgery," vol. ix., p. 193.

[1] A single frambœsiform patch which remained of the ankle in Dr. Boyden's case is well depicted from a drawing kindly supplied by himself in plate 91[bis].



FIG. 13.—Photographed from fig. xii. of Nicholls' "Report on Yaws," "showing large encrusted granulomata about the head and neck."

FIG. 14.—Fijian Yaws, late secondary Eruption. (From a photograph by Dr. Corney.)

the eruption which had led to the use of this name rather than that of syphilis. Many surgeons, both in Natal and Cape Colony, told me that although in their earlier experience they had been accustomed to diagnose certain cases as "yaws," they had since become convinced that they were all really syphilis. Dr. Long, the able medical officer to the Government at Maseru, Basutoland, made this statement with great definiteness. He said that syphilis was common amongst the Basutos, and often of the frambœsial type. He had, however, satisfied himself that the cases which, when he first went there, were usually called yaws were really examples of non-venereal syphilis.

FIG. 15.—Extraordinarily large papillomatous fungus in a case of Yaws. (From a photograph given by Dr. Nunn Rat.)

The papillomatous outgrowth which is such a conspicuous feature in the best marked examples of what is known as yaws assumes in certain cases extraordinary development. Unusually large ones sometimes occur about the feet and ankles. One such is depicted in the appended illustration. It will be remarked that it is distinctly papillomatous rather than granulomatous.

THE INTERMEDIATE STAGE (RELAPSES).

It is well recognised that in syphilis there not unfrequently intervenes between the well characterised secondary symptoms and those of the tertiary class a period during which certain less well-marked conditions may occur. We no longer see copious generalised eruptions arranged with bilateral symmetry and accompanied by superficial filmy ulceration in the tonsils. This stage is past, and as a rule it never recurs. It may, however, still be the fact that there are certain somewhat vague phenomena which have been called "reminders," and which, although not in themselves of great importance, serve to indicate that the cure is not complete. Sometimes these are continuous with those of the secondary stage which has never wholly disappeared, but in others an interval of complete immunity has occurred. It would seem that these intermediate symptoms are often very troublesome in cases which have been diagnosed as yaws. They were so in the two cases just described at page 12, and illustrated in plate 91[bis]. Many authors refer to cases in which reminders of the eruption lingered or continued to recur for two or three years after the first outbreaks. It is, of course, quite impossible to draw any abrupt line of distinction between the symptoms referred to and those of the secondary group on one hand and of the tertiary on the other. No definite period of time separates these two stages, and they not infrequently merge into one another. In particular, attacks of destructive ulceration of the palate, quite distinct from the superficial and non-destructive inflammations which occur in the secondary stage, may show themselves either at short or at very long intervals. Although the secondary affections of the throat have been but rarely observed in "yaws," yet these later ulcerations are mentioned by many. Amongst the more common of the intermediate or persisting symptoms, we have, however, affections of the palms and soles, and the form of multiple periostitis of the digital phalanges, known as syphilitic dactylitis. Concerning each of these, it is necessary to say a few words.

ERUPTIONS IN THE PALMS AND SOLES.

Special attention must here be given to the affections of the soles of the feet which

are common in "yaws." They are described with care by almost all authors, and are figured by several. They have received popular names in several of the districts where "yaws" is common. In the West Indies they are known as "tubboes," and in Ceylon as "dumas," and are alike in all countries. Figs. 17 and 18 in plate G are taken from Dr. Nicholls' work. Plate LXXXVI. of Kynsey's series illustrates them exceedingly well. All these figures show patches on the soles from which the epidermis has been broken away, and some which have degenerated under pressure and irritation into sores. Although none show definite frambœsial outgrowths, yet the descriptions given are unanimous in stating that the early stage is sub-epidermic, or in other words papillary growth, and that it is this growth which breaks through the epidermis and tends to assume more or less of the fungous condition. The suggestion is a very plausible one that they are hindered in their full development by the pressure to which they are exposed. At the same time it is also probable that the frequency and severity with which these affections of the soles occur in yaws, as compared with the psoriasis plantaris witnessed in English syphilis, and with palmar psoriasis in both "yaws" and syphilis, is due to the habit of going barefoot. The palms in yaws are usually affected also, but not to the same extent.

According to some authors these patches on the soles are not unfrequently accompanied by moist sores between the toes (rhagades); although these occur coincidently with the eruption on the trunk and limbs, they are not usually present in its earliest stage, and they persist often long after other symptoms have disappeared.

I would suggest that these affections of the soles and palms do not differ in any respect excepting in frequency and severity from what are met with in English syphilis. It has been abundantly proved that in the latter a tendency to papillary outgrowth is often an element in the secondary eruption. In the case of a patient who had contracted "yaws" in Africa, and who had gone through a well-characterised attack, this affection of the soles persisted after the eruption had disappeared. He was brought before the Tropical Section of the British Medical Association at its Ipswich meeting, and by an unanimous vote those present declared their opinion that the conditions remaining were those of syphilis.

It is to be understood that the symmetrical eruption of discrete patches in the palms and soles here described is a true psoriasis of those parts and belongs to the secondary eruption. It is quite distinct from the peeling serpiginous patches often occurring in one limb only, and usually designated psoriasis palmaris or plantaris. This latter is usually a tertiary symptom, or at any rate it is not part of the secondary group.

Multiple Dactylitis.

The form of dactylitis which sometimes affects the subjects of syphilis amongst white races would appear to be much more common amongst those who suffer from yaws. It is figured by several authors and described by others. It may occur, as we have just seen, in children, but is more common as a late affection in adult life. It is a form of periosteal node, but may involve the joints. It is amenable to specific treatment. It is well represented in several of Kynsey's plates, and from one of these the illustration here introduced is copied. It will be seen that it occurs in association with large and deep scars, which are probably those of ulcerated gummata. Sometimes, however, it is part of the later secondary phenomena.

Fig. 16 in plate G represents multiple dactylitis as it occurred at the same time in the hands of a mother and her child. The mother had suffered from yaws before her pregnancy. The photograph was taken in Fiji by Dr. Daniels. The smaller hands are those of the child, who was about eighteen months old when the photograph was taken.

THE TERTIARY STAGE.

The older writers on yaws made no scruple in admitting that the disease had its remote

FIG. 16.—Multiple dactylitis in a mother and child. (Copied from a photograph given by Dr. Daniels.)

FIG. 17.—Photographed from fig. x. of Nicholls' "Report on Yaws," described as showing granulomata about the heels (tubboes), and dermatitis "crabs" at other portions of the sole.

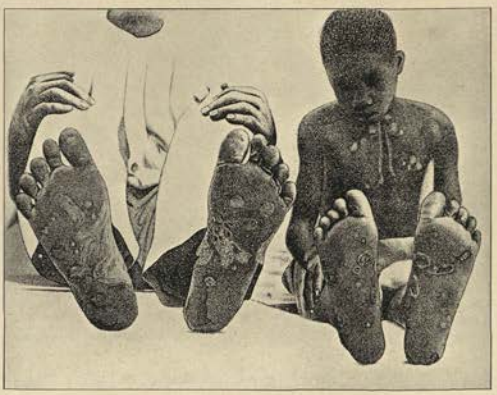

FIG. 18.—Photographed from fig. xi. of Nicholls' "Report on Yaws." Shows granulomata and dermatitis in the soles of the feet. The linear scars in the chest of the right-hand figure were accidental.

sequelæ, and freely described, as such, certain diseases of the skin, throat and bones.

Thus Dr. Good quotes from Mr. Mason: "He [*i.e.*, Mr. Mason] bears witness, however, to the bones of the legs and arms becoming affected with simple enlargement; to the extension of the ulceration down to the periosteum, and to the bones becoming carious. These affections of the bones seem, like those of syphilis, often to continue for years after the other symptoms have ceased, and in some instances to prove fatal. The membranes of the nasal cavities sometimes ulcerate, and the adjacent bones become diseased, followed by frightful and incurable ulcerations of the nose, palate, and throat" (*Ibid.*, note, p. 434).

In more recent times some observers have inclined to dispute this, and to assert that one of the distinctions between syphilis and yaws is the absence of tertiary symptoms. This can be done only by attributing all such symptoms, when occurring after yaws, to some other supposed cause, syphilis and tuberculosis being the most readily available. Thus in the illustrations which are here given, copied from Dr. Nicholls' "Report on Yaws," in which lupoid ulcerations followed yaws, it is suggested that syphilis had been present also. Other authors have supposed that lupoid ulcerations, at first supposed to have been due to yaws, were really tubercular. No one can doubt that symptoms of this class are ominously common after yaws eruptions. In most countries it is exceedingly difficult to exclude syphilis, but here again we may appeal to the experience of Fiji. It is established beyond any doubt whatever that bone disease has been common there from time immemorial, and that at the present all the ordinary external forms of tertiary syphilis not only abound, but are curable in the most definite manner by iodide of potassium.

Dr. Wallbridge, writing of the destructive ulceration of the palate, fauces and nose, states: "I have twice seen this ulceration under 10 years of age, and it is common about 20. In rarer cases it occurs late in life, and in one woman, about 60, on whom I made a *post mortem*, the larynx was involved" . . . "Occasionally on the face, or elsewhere, is a cutaneous affection resembling lupus vulgaris" . . . "All these show a very marked improvement or cure under potassium iodide" (p. 252).

Some observers incline to say with Kynsey that the yaws of Fiji is syphilis and not "true yaws," but in reply to this we have the fact that it is attended by a frambœsial eruption, and has been by all observers hitherto mistaken for "true yaws." It has been denied emphatically that the Fijians have ever had syphilis amongst them. One observer with great candour admits that in Fiji the conditions occur to which we have referred, and even states that he has himself seen cases of inheritance, with notched teeth, &c., but still with courageous consistency suggests that the disease is yaws and not syphilis, and that it is due not to the same, but to a closely allied specific poison.[1] It will be seen that this suggestion narrows the question of distinction down to the frambœsial type of eruption. In all other respects it is admitted that the two diseases are identical.

As regards visceral disease and affections of the nervous system, we have as yet little or no evidence as to their occurrence after yaws. It may, however, easily be the case that future observers will detect them, and it must be noted that although syphilis in its acknowledged form is very common in most communities in which yaws occurs, these affections have been equally unrecognised as resulting from it. What is needed is no doubt more detailed pathological investigation.[2]

The tertiary stage is well illustrated in many of Kynsey's narratives. In one a man of 35 had ulcers on his right hand, wrist, left side and loins. The ulcers had been present a year, but the man had suffered several attacks of Parangi eruptions, the first of which was in

[1] This appears to be a near parallel to the suggestion that the plays of Shakespeare were not written by himself but by another man of the same name who lived at the same time.

[2] For further discussion of these points see *Polyclinic Journal*, vol. iii., p. 188, and Breda's paper, New Syd. Soc., vol. clxi. p. 261.

childhood. It was after the last attack that the "tubercular eruption" ulcerated. It was reported that half the villagers were suffering "from the same disease in its different stages." He denied having ever had any venereal disease. The ulceration of the back of the hand had resulted in much contraction. The author speaks of the case as one in which "like the last ulceration even various parts of the body had followed the third or fourth attack of the tubercular (moist) variety of parangi. There has apparently been so much loss of tissue about the back of the right hand that it has resulted in well marked contraction as depicted in the sketch." The patient was out of health and had been subject to severe pains about the joints, &c., for several years, in fact ever since he had the ulcers.[1]

Exactly the same conditions of sloughing gummata and deep serpiginous ulceration appear to be common amongst the natives of West Central Africa. The appended illustration is from a photograph given to the writer by Dr. Patrick Manson.[2] A glance at the man's nose will probably, to many of our readers, suffice for the diagnosis (see fig. 22).

In Kynsey's case 2 (see p. 36), another excellent example of tertiary symptoms is given. The patient, a lad of 16, had had two attacks of parangi, one at the age of 3, and the other five years later. At the date of the notes, eight years after the second, he had several large cicatrices on his body and limbs, one of which crippled his left elbow. There was "a large node on the back of the left ulna." "The lower ends of both bones of the forearm were much enlarged, hard and slightly painful on firm pressure." "The anterior surfaces of both tibia were similarly affected, the crest of the left one arching slightly forwards." "No history of syphilis."

Sir William has verbally informed me that the sabre-shaped tibia is frequently seen in Ceylon as a consequence of parangi, and Dr. Rockwood of Colombo has also stated that osseous nodes in connection with the same malady are common.

In Plate XC. we have a good illustration of the scar left after lupoid ulceration. It is taken from Sir William Kynsey's atlas of drawings, now in the Polyclinic Museum. It is tolerably obvious that the three belong to one and the same malady, and they may be allowed to prove that in Fiji, West Africa, and Ceylon, the natives are liable to serpiginous ulcerations, with much destruction of cellular tissue, and resulting in large and deep scars. Dr. Corney's case narrative proves that these are sometimes the sequela of what is there called "Thoko" or "Yaws," and the nose in Dr. Manson's portrait supplies a clue as to the real nature of the malady.

In reference to late affections of the mouth and throat, Dr. Daniels in a letter to the writer states: "With regard to the tertiary manifestations of the disease I am in doubt. In Fiji there is a common destructive ulceration of the mouth, fauces and palate, called 'Kanailoma,' sometimes met with before the age of 10, common in early adult life (under 25) and met with occasionally even in old age. This I was inclined to attribute to yaws, but I find a similar ulceration here (British Guiana), where yaws is rare, occurring at similar periods of life, and usually earlier than tertiary manifestations of acquired syphilis."

It may be remarked that the form of phagedænic ulceration here described is fairly common in English syphilis. It occurs sometimes with great severity in the subjects of inherited taint.

I have endeavoured in what has been adduced to enable the reader to judge for himself, by the aid of citations from the writings of those who hold that yaws differs specifically from syphilis, whether this belief is well grounded. It has been shown, if I mistake not, quite clearly that it observes stages to which the terms "primary," "secondary" and "tertiary" are just as applicable as they are

[1] Kynsey on "Parangi Disease," p. 52.

[2] Respecting this latter portrait Dr. Manson has informed me: "I do not know what the nature of the ulceration that produced these contracting cicatrices may have been. It is evidently endemic and very prevalent in the district. My impression is that it was tropical sloughing phagedæna, very possibly supervening on yaws sores. I have more than once seen similar conditions in China." Thus we have evidence of the occurrence of this form of "phagedæna" in Ceylon, China, Fiji and West Africa, and in all it has been thought to be a sequel of yaws.

FIG. 22.—From a photograph given by Dr. Patrick Manson. A West African Negro. It shows the results of deep ulcerations at various parts of the limbs, also depression of the bridge of nose. The conditions shewn are reported to be not infrequent in West Africa.

FIG. 23.—Results of sloughing and deep ulceration after Yaws, with multiple dactylitis, from Fiji. (A photograph taken by Dr. Corney.)

FIG. 24.—Ulcerated gummata and scars, with dactylitis. (From Kynsey's drawings.)

DACTYLITIS, PHAGEDÆNA AND GUMMATA WITH THEIR RESULTS (IN YAWS).

to syphilis. There remain now to be noticed a few more or less isolated topics which it may be convenient to take up for separate consideration. We have to ask whether the two diseases are curable by the same remedies; whether frambœsia is incapable of being transmitted from parent to child; whether inflammations of the eye are common in syphilis and unknown in frambœsia; and whether the microscope gives us help in distinguishing them. After discussing these and a few others, I shall conclude by animadversions on a few popular errors as to syphilis itself.

The Influence of Treatment on Yaws.

Charlouis writes: "The best treatment consists in the combined use of mercury and iodide of potassium." He had in a previous paragraph stated: "Although the course of frambœsia has been differently described by different authors, these are for the most part agreed that the disease yields to mercury. Even Sauvages and Plenck (who dispute the syphilitic nature of frambœsia) state that mercury is the best remedy for frambœsia. . . . . Mercury in the form of a mercurial ointment applied to the tubercles has a very satisfactory as well as a very rapid effect."

In opposition, more or less direct, to these opinions others might be quoted in abundance. Thus, many hold that although mercury may be sometimes useful it is often otherwise, and a few that it is always injurious, and that the disease should be left to itself or treated only by tonics. The state of opinion is, indeed, an almost exact repetition of that which prevailed as regards the treatment of syphilis fifty years ago. It may be assumed with some confidence that all differences will vanish as soon as it is recognised that, in the treatment of yaws, mercury should be begun early, but in very small doses and guarded, when requisite, with opium and quinine; that salivation should be avoided, and that the course should be continued for at least a year. Those who have found it unsatisfactory have usually employed it in far too large doses and have, under necessity, laid it aside much too soon.

The relapses which they record are precisely such as we should expect in syphilis under similar measures. Charlouis, who, as has been seen, speaks most strongly as to the efficacy of mercury, adds "but nevertheless patients treated in this way soon returned with a few fresh tubercles. In such cases I inferred that they were not completely cured at the time of their discharge, although they no longer had any tubercles." Thus it is evident that the remedy was laid aside when the patient left the hospital.

It is not desirable here to discuss the treatment of yaws by specifics any further than it may serve to illustrate the parallelism or otherwise with syphilis. Now, it is one thing to admit that mercury exercises a specific and definite influence in causing the disappearance of the outward phenomena of yaws, and quite another to advocate it as on the whole the best treatment for the disease. The latter depends upon many details as to dose, mode of administration, continuance of its use, and other matters. Without an exception all writers admit that mercury causes the symptoms to disappear, but many doubt whether in the long run it is the best remedy. As regards our present argument, this admission of specific power is all that is desired.

In reference to the iodide of potassium, all agree that it is comparatively useless in the early stages, and that it acts as a specific in the tertiary ones. We are told that the Fijians import it in very large quantities for the relief of their bone pains. Prior to the advent of Europeans and the introduction of this salt they suffered very severely from bone disease, so much so that the very earliest records which we have speak of a peculiar disease of the bones as being almost a characteristic of the Fijian race.[1] Charlouis recommends iodoform in pills as the best remedy for bone pains of yaws.

[1] *Encyclopædia Brit.*, ninth edition, vol. xix. p. 156: "The natives have a bad skin disease, *thako*, affecting also the bones, from which few escape."

Is Yaws Heritable?

Most authors have denied that yaws is transmitted from parent to child. Several fallacies, however, underlie this negation. In the first place it is probable that any symptoms which an infant might display would resemble those of syphilis, and would be diagnosed as that disease. This applies with especial force to the late phenomena, such as interstitial keratitis and notched teeth. In the case of the Fiji natives, amongst whom syphilis is reputed to be unknown, we have the evidence of Mr. Finucane, corroborated by Dr. Corney, that notched teeth are occasionally seen. The former of these adds interstitial keratitis, and further states that he has seen not a few cases in which infants showed the usual symptoms of inherited syphilis. A photograph which we here copy,

Fig. 25.—Photograph of a young child (Fijian) whose mother had suffered from yaws. It shows multiple dactylitis, depressed bridge of nose, and prominent forehead (Dr. Powell).

supplied by Dr. Powell, shows multiple dactylitis in a mother and her infant. Dr. Powell's notes of this case state that the mother had a primary sore in the scar of a breast abscess, and developed an eruption of "yaws." This was in January, 1895, and in April of the following year she bore a child. This child appeared to be healthy at the time of birth, but had "a yaws eruption" seven months later. It was eighteen months old, or more, at the date of the photograph. It seems far more probable in this instance that the disease in the infant was the result of inheritance than of acquisition. The outlines of its nose and forehead also support this supposition.

Dr. Maxwell, after having written "Syphilis is capable of affecting the fœtus *in utero*, yaws has never been known to do so," supplies the following narrative (see page 212): "It is very common to see young children at the breast with the disease, but the earliest case which I have ever witnessed was the following: a young, healthy woman in her second month of pregnancy had a scurfy eruption of a pretty general description, unattended with constitutional derangement, shortly afterwards followed by yaws in a mild form, which spontaneously healed before her delivery. Her infant boy when three months old was seized with stiffness, appeared to be in great pain, and cried almost incessantly. The symptoms were attributed to a fall, when an eruption of benignant yaws suddenly broke out." We are not told what became of the child. The case reads exactly like that of a syphilitic scaly eruption in a pregnant woman, which in its later stage became mildly frambœsial, followed by a syphilitic infant destined to suffer from epiphysitis and a mild eruption of condylomata. Dr. Maxwell suggests that the malady was not inherited, but that the infant was infected in its birth by some remnant of yaws about the mother's labia. This is improbable, and he makes no mention of any chancre on the infant.

Kynsey's nineteenth case reads much like one of inheritance. The girl had her tibiæ arched forwards—apparently the well-known sabre-shaped tibia. The same condition is mentioned in several other cases.

By the side of Dr. Powell's photograph another may be placed which also illustrates the physiognomy of yaws in a young child. The bridge of the nose is depressed, just as in inherited syphilis.

That cases of inherited yaws should be less common than those of inherited syphilis is easily accounted for by the fact that whilst venereal syphilis is usually contracted in adult life, yaws is ordinarily a disease of childhood, and that thus all risk of hereditary transmis-

FIG. 19.—Copied from fig. i. in Nicholls' "Report on Yaws." It is briefly described as "showing Lupus and Yaws," so that there is no doubt that this condition was a sequel of Yaws.



FIG. 20.—Photographed from fig. xv. in Nicholls' "Report on Yaws," where it is described as "showing lupus of the nose and face, which came on during an attack of Yaws."

FIG. 21.—Photographed from fig. xiv. of Nicholls' "Report on Yaws.' It is described by the author as "showing destructive ulceration of the face, nose, and mouth, due to tertiary syphilis that appeared during an attack of Yaws."

TERTIARY ULCERATIONS IN YAWS.

sion is long passed before its subjects become parents.

The Occurrence of Syphilis and Yaws in the same Patient.

To those of us who believe that what is called yaws is simply frambœsial syphilis, and often only a transitory stage of that disease, it is superfluous to entertain the question as to the occurrence of the two in the same patient. Our creed is that although we see plenty of syphilis without frambœsial eruptions, the latter are never seen without the occurrence, sooner or later, of the more usual phenomena of syphilis.

Drs. Daniel and Wallbridge write respecting the occurrence of yaws and syphilis in the same person that "a fair number of such cases are recorded, and in all the syphilis preceded the yaws." The obvious inference from this is that the syphilitic poison caused the "yaws" manifestations. The only instance of this coincident occurrence which had come under Dr. Wallbridge's own observation remarkably confirms this suspicion: "In a European the syphilis preceded the yaws (or 'Coko'), but the latter disappeared during a voyage to England, and on the return of the patient to Fiji he had a well-marked tertiary syphilitic eruption." This may probably be read: "A European had an indurated chancre, followed by a frambœsial secondary eruption which, having disappeared was eventually succeeded by tertiary symptoms."

In most of the countries where cases diagnosed as "yaws" occur there syphilis is also common. It is therefore easy, whenever phenomena of a more definitely syphilitic character follow a yaws eruption, to suggest that the patient has had both diseases at the same time. This is the course taken by those who have recorded several of the cases of which we have given illustrations (see figs. 19, 20, and 21).

It is because this source of fallacy is wholly excluded that the facts which come to us from Fiji are so valuable.[1] It is asserted that from time immemorial there has been in Fiji but one malady, and that malady "yaws," and it follows that all the sequelæ which are observed in Fiji are those of yaws and not of syphilis. What these sequelæ are we have already seen.

We have to deal, however, not only with cases in which tertiary phenomena following

[1] The following statements respecting the disease in Fiji have been supplied to me by a correspondent, and will be read with interest:—

"In the old days, by which I mean from 1648 until Annexation, the natives were cannibals; they did not belong to one tribe, there were many tribes, and each tribe was at enmity with the others frequently. I have heard from old chiefs how their warriors had to watch throughout the night to prevent ambush, and how even their wives in the daytime could not go into their gardens to plant, or gather food, without running the risks of being carried off and eaten; as a result friendship between members of separate tribes was rare and intermarriage between such most exceptional. How could syphilis be communicated to the natives when the only ships that touched there were whalers and sandal-wood traders, who knowing the character of the natives, would certainly not have much communication with them.

"Coko, or yaws, was always more severe in the mountains than on the coast. It was certainly in Fiji prior to Annexation; and yet the Fijians could not have caught syphilis before that time. Since then, it is true coolies have come into the country, and Fijians are now laxer in their morals, and some of the younger men might certainly catch syphilis from the coolies, as they run the risk, and yet neither Dr. Corney, the Chief Medical Officer of the Colony, nor I have met with any case of syphilis in a Fijian. This may perhaps suggest what has been remarked on as possible by my predecessor, Dr. Daniels, that yaws might be a protection against syphilis.

"Mr. Carew, one of the Magistrates of the Colony, who was there long before Annexation, as well as the late Governor, Sir J. B. Thurston, and other old residents, have all assured me that Coko (yaws) was prevalent when they arrived in the group (say 1860), and that then the natives said it was an old disease, or, as I remarked in the letter I wrote you from Rewa 'a disease of the land,' and that Fijians have always had it, not only those of to-day, but their grandfathers and great grandfathers, and probably, too, the ancestral spirits from whom, according to their old religion, they were descended.

"Accepting then, that Coko was prevalent in the old days, and that from want of communication, &c., they could not have caught syphilis then, it consequently follows that they did not have syphilis or that they brought it with them when they came to Fiji, and as to this latter point I am, of course, unable to give an opinion; for the place of their origin is, I understand, still unknown, some say from Malay, others from Central Africa.

"As to inheritance, I have never heard of a child being born with Coko; they usually indulge in the complaint during the first three years of their existence. I have not heard of any child under the age of two and a half months who has had the disease.

"I know of one case of a white adult man who caught the disease through kissing his half-caste children (who had it), the mother sore developing at the point of inoculation—the lower lip. This man had had syphilis some years before. In Fiji, in the country the children of the white residents frequently run about without shoes and stockings; often have sores about their feet and legs; and if, as is the rule, they play with Fijian children then they are victims to Coko, the inoculation probably taking place through flies."

yaws have been attributed to coincident syphilis, but with certain others in which the primary phenomena of the latter have occurred in those who had previously suffered from yaws. These are very few in number. It has been suggested that, as a rule, an attack of yaws is protective against syphilis. Charlouis, however, asserts that he succeeded in inoculating syphilis in a man whom he had previously inoculated with yaws, and one or two examples are on record in which patients contracted venereal chancres after having suffered from yaws. To rightly understand these cases we must bear in mind that second infections of syphilis are not infrequent, and that they occur sometimes after comparatively short intervals. We must also bear in mind that the characters of an indurated chancre and of a secondary eruption are by no means so definite as is generally supposed, and that considerable latitude must be allowed to the preconceptions of the individual observer. It is easy to write the sore was "characteristic" and the eruption "characteristic," when perhaps these expressions may seem in type much more conclusive than they were in reality. To those who believe that the two diseases are one and the same such expressions have no meaning. There are no features which are "characteristic" of either.

Dr. Maxwell, after quoting the opinions of others to the effect that a patient could not contract yaws a second time, has asserted very strongly his own belief that recurrences of symptoms are not uncommon. He holds that relapses or second attacks are rarely exactly like the first. When, further, we recall the results of fresh inoculations in the days of syphilisation, we shall not be disposed to attach much weight to the facts under discussion. On the supposition that Charlouis had, in the first instance, given his patient syphilis there is nothing very exceptional in the fact that he was able, by inoculation from a new source, to induce a fresh sore, and that a recrudescence of the eruption should occur. Such observations must be multiplied, must be recorded in full detail and authenticated by more than one observer, before they can be admitted to prove that syphilis and yaws are distinct, and that the one does not protect against the other.

Is Yaws or Syphilis attended by the Greater Amount of Constitutional Disturbance?

"However long the disease persists, the constitution of the patients is never impaired by frambœsia" (Charlouis).

Whilst Daniels and others support this statement by representing the disease as free from constitutional disorder, Nicholls, from statistics of the Yaws Hospitals of the West Indies, gives it a mortality of 2·5 per cent. Such a mortality is certainly far higher than that of syphilis.

It is to be remembered that in former times a slave who had gone through his attack of yaws and regained his health was much more valuable than one who had not had it—one author says that he was worth twice as much. Dr. Maxwell represents yaws as a severe disease, and not infrequently fatal.

Dr. Nicholls appears to consider the mortality of 2·5 per cent., which he gives as that occurring in the West Indies Yaws Hospitals, as a low one. He thinks that the disease is more fatal in cases treated at the patients' homes (p. 334). In contrasting this rate of mortality with that of syphilis in our own country, it is to be remembered that it concerns for the most part cases in the secondary stage. It is exceedingly infrequent for a patient in England to die in the secondary stage of syphilis.[1]

[1] The following statements by different authors confute each other, and may be allowed to show that but little value is to be attached to them:—

"Frambœsia very seldom undergoes spontaneous cure in a few months, but its course covers a year, whereas the manifestations of syphilis as a rule disappear moderately quickly" (Charlouis, *loc. cit.*, p. 315).

"The constitutional symptoms of the venereal disease are generally progressive, and seldom disappear without the aid of medicines. The yaws generally admits of a spontaneous cure" (Maxwell, p. 208).

Iritis and other Affections of the Eye.

Those who attempt to establish a distinction between yaws and syphilis make much of the supposed fact that iritis does not occur after the former. It would, however, need a large amount of careful observation to prove this. Iritis is a very rare event after syphilis in England. When Lawrence first identified it in that association he described only very few examples of it, although he then had the wards of St. Bartholomew's and the out-patients' room at the Moorfields Ophthalmic Hospital as his fields of observation. I have not myself seen a case for several years. In the *Moorfields Ophthalmic Hospital Reports* for 1901 we find that only two cases of "syphilitic iritis" were admitted during the whole year. That others were treated as out-patients is certain, and of these we have no estimate, but during the same year seven were admitted for "rheumatic iritis," thus showing that all severe cases were admitted. During the same year seventeen cases of syphilitic keratitis (interstitial and hereditary) were admitted. From Mr. Finucane we have had the statement that in Fiji both iritis and keratitis do occur in association with so-called thoko or yaws.

Some Points of Supposed Diagnosis between Syphilis and Yaws.

Maxwell writes: "Syphilis appears in six or eight days after contagion. Yaws takes from six weeks to three months." The answer is obvious that it is now known that the usual incubation period of the syphilitic chancre is about one month, and that of the eruption nearly three months. The incubation periods are indeed precisely the same in the two maladies.

Mr. David Mason (*Edinburgh Medical Journal*, No. cvi., quoted by Good) wrote: "It [yaws] has some resemblance to syphilis, being slow in its progress, and only communicable by contact; but its after effects are not so destructive, and it leaves the constitution invulnerable to future infection." Mr. Mason had had a large experience of yaws, and these were apparently the only distinctive features which he had observed.

Absence of a Primary Sore.

Powell tells us that in fourteen cases inoculated by Paulet, in four a general eruption occurred without any lesion at the seat of inoculation. These occurrences have their parallels in what is known as syphilis d'emblée. I have several times known syphilitic eruptions to follow pricks on the hands from which no sores had resulted.

Second Attacks.

Charlouis writes: "I can safely confirm the statement that frambœsia may attack the same individual more than once, a fact which can be proved not only by observation but also by inoculations."[1]

Dr. Woolridge writes: "The Fijians considered a previous attack absolutely protective. Cases in adult life were extremely rare, and when they did occur were attributed to the fault of the parents, who had not taken care that they should have the disease in childhood."

Maxwell writes: "Syphilis may occur frequently from distinct contagion," and although he admits that yaws may also occasionally do so, he doubts whether second attacks are of precisely the same character as the first.

Kynsey records several instances of second attacks.

We may safely believe that second attacks are equally frequent and equally rare in the two maladies. The same statement will apply to any modifications which may be observed in second infections.

Bacterial and Histological Evidence.

As has happened repeatedly in the case of syphilis, so in that of yaws, observers have

[1] Page 292, New Syd. Soc., vol. clxi.

imagined that they had discovered bacterial organisms which were characteristic of the disease. In no instance, however, has any confirmation, on the part of others, followed, and we may safely assume that nothing whatever has as yet been made in the least probable. Others have sought to find in the arrangement of the cell elements data which might be trustworthy. The histology of the inflammations which result from syphilis is, however, by no means so characteristic as to justify diagnosis, and as to that of its frambœsial forms we have little or no information. There are questions upon which the microscope can give invaluable evidence, there are others upon which its prematurely formulated conclusions amount to little more than scientific dust flung into the eyes of unwary readers.

Some Common Misconceptions as to Syphilis.

It may, perhaps, without the risk of being charged with presumption, be suggested that almost all the difficulty as to the identification of yaws as being really syphilis arises from misapprehension of the facts as to the latter disease. Amongst the prevalent misconceptions as to the latter may be mentioned the following:—

I. That the primary sore is always a well characterised indurated chancre. As a matter of fact erratic chancres, that is, chancres on other parts than the penis, very seldom present characteristic features. They are constantly mistaken in their early stages, and often through their entire course. Sometimes no sore is observed at all, and not infrequently it is insignificant and of brief duration. What Charlouis tells us as to his having been in the habit of searching for enlarged glands in order to discover on what part the primary sore of yaws had been, is exactly what has often to be done in cases of misplaced syphilitic chancres.

II. That the primary sore of syphilis never fungates. It does so not infrequently.

III. That the primary sore of syphilis is never attended by satellites. There can be no doubt that it is so occasionally.

IV. That it is impossible to reinoculate syphilis in those who have had it. Second attacks are not uncommon, and although in most cases a considerable interval must elapse before the subject becomes again susceptible this is not invariable, and second chancres within a year of the first have been observed, attended by recrudescence of secondary symptoms.

V. That sore throats and affections of the mucous membranes are almost invariable in syphilis. In reality they are very often omitted, and their occurrence is probably much influenced by exposure to cold, and personal habits.

VI. That syphilitic eruptions are always polymorphous. We understand by "polymorphous" presenting a mixed character at the same time, not the presenting of different features in different stages. As regards the latter, it is admitted by all that yaws as well as syphilis has its stages, and is papular, scaly, and frambœsial at different periods. The peculiarity of yaws is supposed to be that it finally settles down into the frambœsial type. Now it is quite certain that syphilis often assumes very definite and uniform type forms. Not only may it be papular, or scaly, or lichenoid, but may closely simulate common psoriasis, pemphigus, variola, and all the specialised forms of lichen. Most unquestionably it sometimes shows itself as a well-characterised frambœsial eruption. These differences in type-form of the secondary outbreak appear to depend exclusively on the idiosyncrasy of the individual, and do not imply any difference in the virus.

VII. It is further a mistake to suppose that syphilis is in all cases attended by loss of health in the secondary stage. As a matter of fact many patients pass through it without any recognition of ill health. A remarkable illustration of this will be found in the record of the second series of Vaccination syphilis recorded in my paper in the *Transactions of*

the Royal Medical and Chirurgical Society. In this instance a child was recognised in the out-patients' room of the London Hospital as suffering from a syphilitic eruption consequent on vaccination. From the vaccinator the names of all who had been vaccinated from the same source were procured, and they were all visited at their homes. No fewer than fourteen children were found who bore signs of syphilis, but who were so entirely free from disturbance of health that they had, with few exceptions, not been placed under care and were attending school and mixing with their play-fellows as usual. Thus we have an exact parallel with what is reported to occur in yaws.

VIII. It is also a mistake to hold that syphilis always needs treatment for its cure, and that it is always severe unless treated. In reality both its primary and secondary phenomena are often very slight, and pass away without any treatment. Even in cases in which the secondary stage is well marked the symptoms will in time disappear without the use of specifics. This was made abundantly evident in the practice of the anti-mercurialists, who were able to contend, sometimes with some show of reason, that on the whole it was better not to use specifics. The length of duration of the stages in untreated syphilis would appear to be almost exactly as those of yaws, and the risk of persistence and of relapses is also alike in the two.

IX. The last error which I shall notice is the assumption that all syphilitic parents produce tainted children. Not infrequently children born within very short intervals of the parental disease escape. Inheritance is indeed exceptional and escape the rule. It may not be without its interest to remind the reader that so good an observer as John Hunter denied inheritance altogether, just as some authorities on yaws in the present deny that it is ever transmitted.

Conclusion.

In concluding this *résumé* it may perhaps be desirable that I should state explicitly my own belief. It is the more necessary to do this because it has been impossible in what I have written not to use the words "yaws," "parangi" and "frambœsia" as if they were applicable to diseases distinct from syphilis. This is not my creed. To my mind it seems most probable that the virus—as yet undemonstrated—which causes these affections is one and the same, and that it has had its homes, from times, long antecedent to medical history, in various parts of the world. Amongst these were the West Coast of Africa, the West Indian Islands, Fiji and other islands in the Pacific, China, and possibly India. It was not known in Europe until the end of the fifteenth century, when it was introduced by Portuguese traders from West Africa. Almost simultaneously, but a little later, it was also brought over by Columbus' sailors from the West Indies. It then spread over Europe as "the Neapolitan disease," "the French disease," and finally as "Syphilis." With the progress of knowledge and increase of care it became more and more restrictedly a venereal malady, but in the first instance it was not so, and is still not so exclusively. From the first it occasionally produced, in its secondary stage, a frambœsial eruption, and to cases of this type the names of "button scurvy," "sibbens," "morula," and some others were, in different places, applied. In tropical countries and amongst coloured races the frambœsial type of eruption is much more frequent than in Europe or North America. In tropical countries, also, syphilis spreads very commonly as a non-venereal disease, the primary sore occurring not on the genitals but on some part of the trunk or limbs. Flies are probably very frequently the carriers of the virus, the naked skin, when abraded by accident, offering ready sites for contagion. The subjects of these non-venereal cases are often children, and the primary sore is usually ill characterised and is often overlooked. Hence the confusion which has arisen.

No one would ever have thought of differing from the opinion of Sydenham and his contemporaries had it not been for two circumstances; *first*, that in so-called yaws the primary sore is usually not on the genitals and is there-

fore often overlooked; and, *second*, that the secondary eruption is usually frambœsial. It is the frambœsial eruption which makes such a strong impression upon the minds of observers. But this eruption is really only a transitory stage, and in all other features, both antecedent and subsequent, the disease corresponds with European syphilis. In the latter disease we still see occasionally cases of the most marked frambœsial type. It is, then, simply in the frequency of this type of eruption that the two maladies differ, and this frequency may be reasonably attributed to difference in climate and race.

ILLUSTRATIONS

OF THE DISEASES IN CEYLON

INCLUDED UNDER THE TERM

PARANGI,

ROYAL ASIA

PREPARED FROM ORIGINAL WATER COLOUR DRAWINGS BY A NATIVE ARTIST,

WITH DESCRIPTIVE REMARKS

BY

SIR WILLIAM KYNSEY, C.M.G., F.R.C.P.I.

late Principal Civil Medical Officer and Inspector General of Hospitals, Ceylon.

PART II. OF FASCICULUS XIV. BEING II. OF THE ATLAS OF CLINICAL MEDICINE, &c.

PLATE LXXVI.

THE ERUPTION.

The portrait of a young girl showing the yellow crusted eruption occurring chiefly on the four limbs but to some extent also on the face and trunk. Photographs showing back and front (Menika V.). Views of the same patient are given in Plate D. Figures 9 and 10.

The following are Sir W. Kynsey's notes:—

Menika. 13 years, male, Sinhalese: no occupation. Admitted into the Government Civil Hospital, Kandy, on the 20th November, 1889, for parangi.

The duration of disease before admission was about three months. He was in fair health on admission.

Several people who live in the village suffer from a similar disease; the inmates of about ten houses are affected.

He never suffered from any form of venereal disease. He was vaccinated about five years ago; the disease appeared long after vaccination.

The subject of this report is a fairly nourished Sinhalese lad of about 13 years of age. He states that five months ago he was gored by a cow, on outer side of left thigh, an inch below the left hip. The wound healed in about a month after, and at the same time symptoms appeared round the wound, on chin, left eyelid, and on both arms and forearms, chest, back, scrotum, thighs and legs.

On admission there are eruptions on right cheek, below chin, on right eyebrow, and left eyelid. There are a large number of eruptions scattered over both shoulders, arms, forearms, hands, and front of chest and abdomen, both thighs, legs, and soles of feet, left side of back, and nates. Some taper to a point, like rupia; some are covered with soft yellow scabs; in some the scabs have partially dropped off, revealing pigmented cicatrices; in others there is a raised, circular, yellowish brown border, with a depressed, dark-coloured centre. The dry scabs have no sensation on being pricked with a pin, but the soft scabs are very sensitive. Most of the eruptions are itchy and they are painful at night. There is constant sweating of palms of hand and soles of feet.

The teeth are white and well formed; there is no eruption on mucous membrane of mouth or throat. There is no pain in joints. He says he got the disease by playing with lads who had parangi, and bathing in the river with them.

PLATE LXXVII.

THE ERUPTION.

This portrait represents a very similar state of eruption to that shown in the previous plate, the trunk and face are, however, more copiously affected. A young adult.

Plate LXXXVI. shows the sole of the foot of this patient.

Horatala. 16 years (apparently), male, Sinhalese; labourer. Rambe, a village about twenty miles to the north-east of Kurunegala, on the Dambulla road. Many in the village suffer from the disease.

Both mother and father living. Has two brothers and a sister. Patient is the eldest. Mother and all the children are attacked with the disease. Mother is in hospital under treatment for parangi. Father is a native of Talvitta, about 12 miles away from Rambe, and is free from the disease. He is gone back to his native village.

Patient was perfectly healthy before the present attack. Had a wound below the left inner malleolus about six months ago. The eruptions broke out about one month afterwards, first round the wound, then under the left arm-pit, again over the face, chest, abdomen, the back, extremities, palms of hands, and soles of feet. The disease commenced with pains in the limbs, followed by the appearance of a number of small papules, which were succeeded by tubercles. The eruptions on palms of hands and soles of feet are more or less scaly.

Patient complains of itching all over the body, but not over the eruptions. The number of eruptions over the whole body amounts to nearly three hundred.

Skin dry. Mucous membranes of the mouth and throat normal. Patient complains of running pains in the limbs, which are worse at nights.

PLATE LXXVIII.

THE ERUPTION. A SECOND ATTACK.

The portrait of a man named Sadris, whose case is given in Sir W Kynsey's Report at page 48. He was a married labourer, aged 25. His wife and child had been in the Hospital with the same disease a little previously. The child had it first, next its mother, and lastly its father. It was believed to be in him a second attack but no date of the first is given.

The eruption is seen to be abundantly arranged with fair bilateral symmetry and consisting of yellow crusts which conceal small sores which tend to become confluent. It had been out five months and had been first observed as papules on the right leg. No other primary sore had been observed. The description given of the eruption is: "Primary small papules which are said to have become converted gradually: Secondary: into larger tubercles covered with the characteristic yellowish white discharge." Others in the village had recently suffered.

This plate shows an extensive eruption in the dry stage. The disease had lasted some months; the crusts are dry, shrivelled, and in process of falling off.

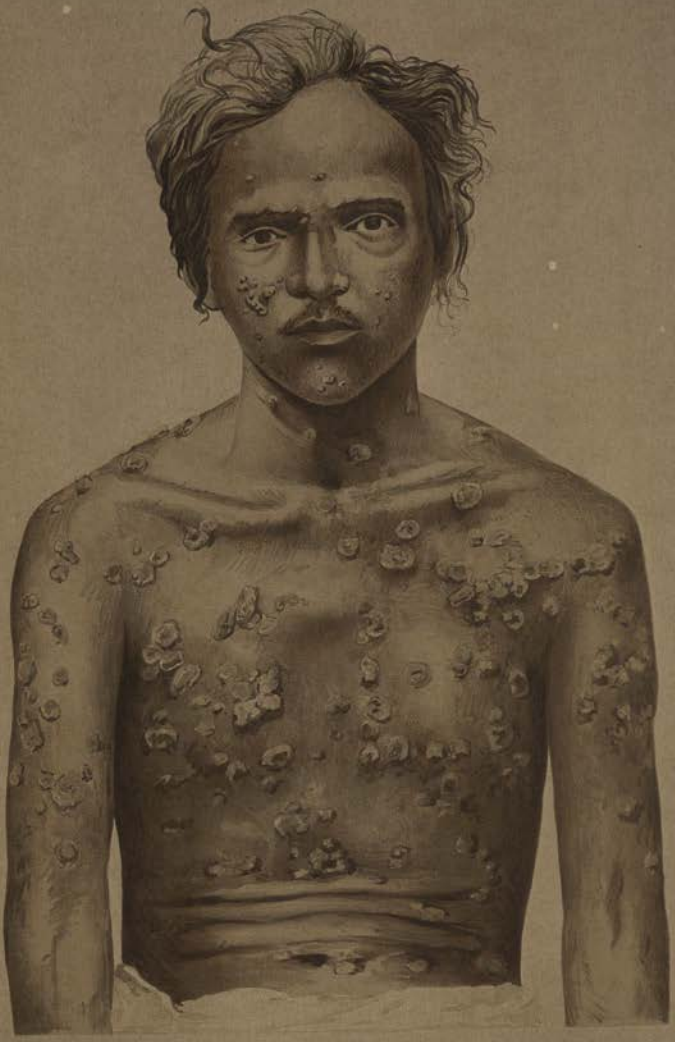

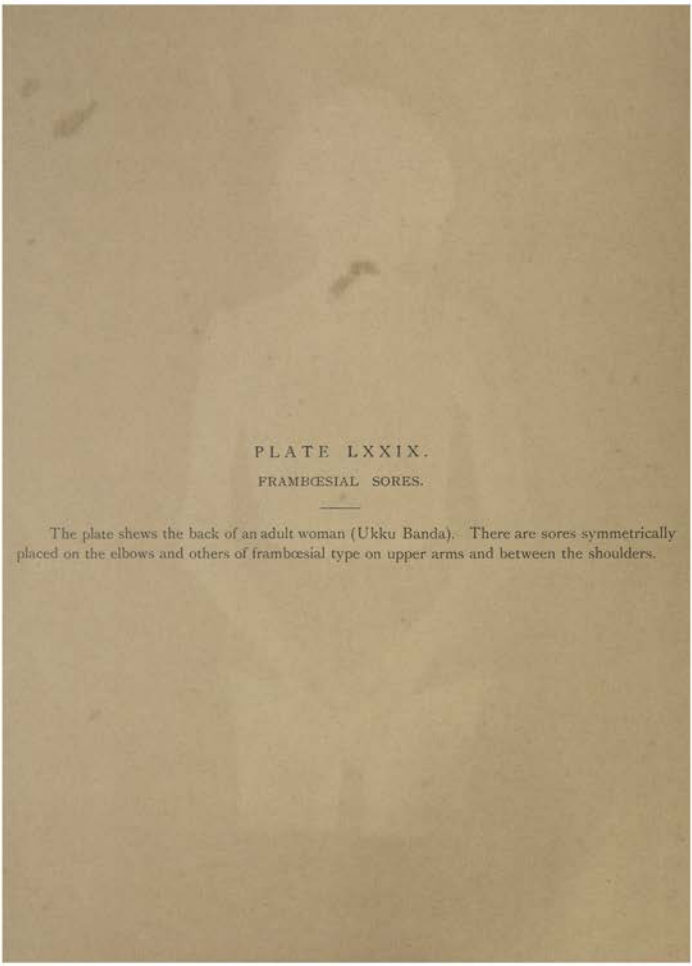

PLATE LXXIX.

FRAMBŒSIAL SORES.

The plate shews the back of an adult woman (Ukku Banda). There are sores symmetrically placed on the elbows and others of frambœsial type on upper arms and between the shoulders.

Dale & Jamieson, Ltd., London.

PLATE LXXX.

THE ERUPTION.

The portrait of a man showing the eruption abundantly scattered over trunk, limbs, and face. The arrangement is symmetrical. The papules are smaller than usual and are more or less grouped.

In the four corners of the plate are represented some individual papules, slightly magnified in different stages.

PLATE LXXXI.

ERUPTIONS IN MOTHER AND CHILD.

A mother and sucking child, both suffering from the eruption.

The following are Sir William Kynsey's notes:—

This plate represents a young Sinhalese mother with a well-marked eruption on her breasts, suckling a child who has very characteristic crusts over his body. The child was first attacked and communicated the disease to his mother. The eruptions round the mouth, on the face, side, knees, and penis are well marked.

Hale & Iddiston, Ltd., London.

PLATE LXXXII.

ERUPTION ON BREASTS OF NURSING MOTHER.

The breasts of the woman represented in the preceding plate. To shew the frambœsial papules of their natural size they have been cleared of crusts.

Hall & Anderton, Lith. London.

PLATE LXXXIII.

ERUPTION ON FACE OF CHILD.

Face of the child represented in Plate LXXXI. It shews well the character of the frambœsial eruption on the face, and the condylomatous excrescences on the lips.

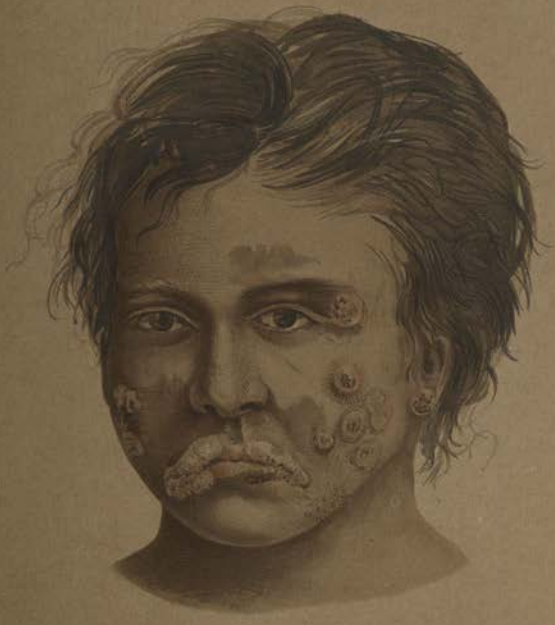

PLATE LXXXIV.

ERUPTION IN A LATE STAGE.

The portrait of a man described as showing "Recent eruption on face and neck with dark stains marking the seat of former eruption."

On the left eye brow there is a very well characterised frambœsial excrescence, and others, only less well marked, on the forehead, eyebrows, cheek, and back of neck. At the outer canthus of left eye is an ulcer without fungation, and on the lower part of neck a larger sore healing in the centre and fungating at its border. There are many dark stains quite round, and most of them smaller, which no doubt represent a former eruption of a milder type.

Sir W. Kynsey's notes are as follows :—

Punchy, 35 years, male, Sinhalese; labourer from the Hanwella district, some twenty-five miles from Colombo. Is in good condition, and general health fairly good. Had a sore on his leg close to left ankle, result of scratching, which would not heal for some months, before appearance of eruption. This is his first attack; others in his village are similarly afflicted. Never had any form of venereal disease. Was vaccinated when young and has satisfactory marks.

Suffered occasionally from ordinary malarial fever.

Before appearance of eruption had pains in joints and bones, and his skin was very itchy. The eruption came out in different parts of his body as small pimples, which increased in size, burst as he describes it, and scab formed. Came out in successive crops. Believes he contracted the disease from other villagers who had similar eruptions.

His food was kurukan* and vegetables, and he obtained his water from a tank.

The eruption is well marked on the neck above the right clavicle, ringworm-like in shape, behind the neck, right cheek, eyelids, eyebrows, and forehead. There are also dark stains marking the seat of previous eruption.

* Eleusine corocana.

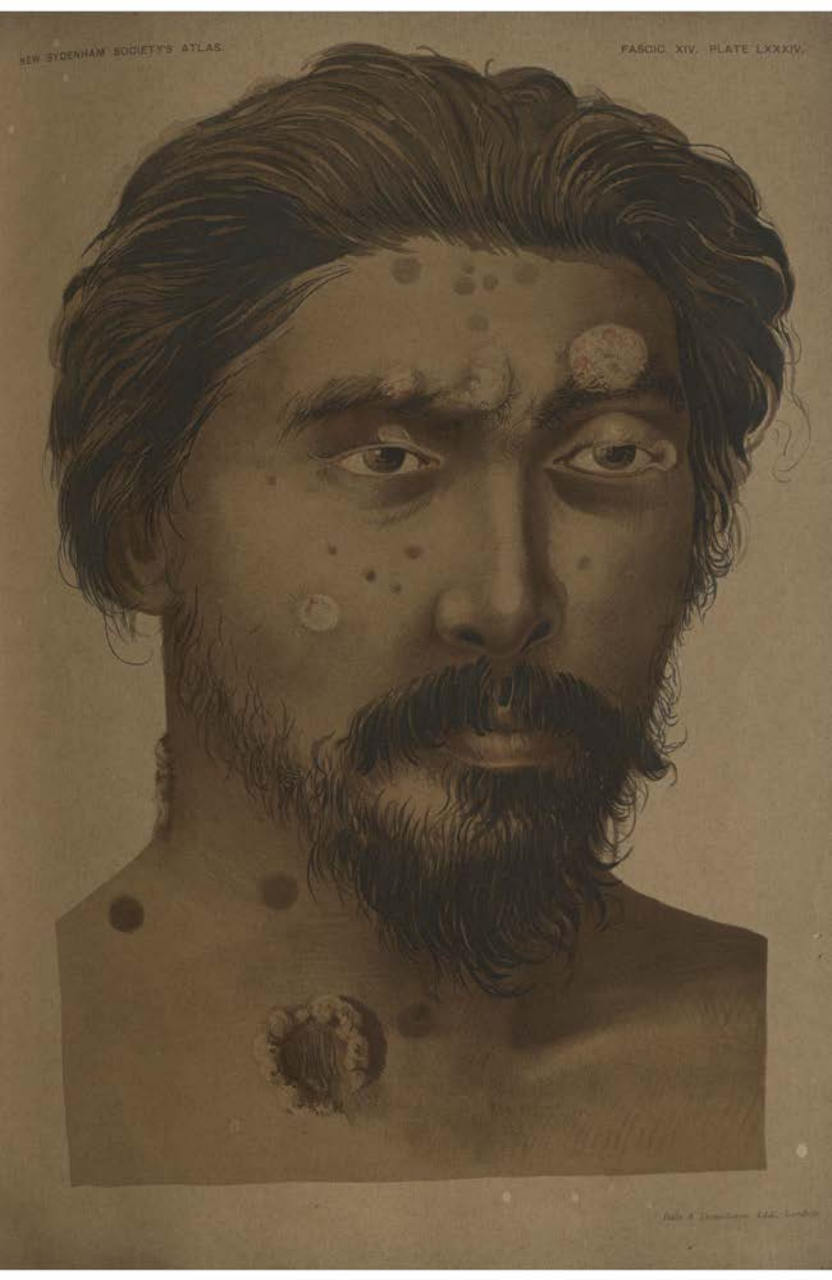

PLATE LXXXV.

STUDIES OF LESIONS.

We have here life-size studies of the lesions of parangi on different parts. Most of them show ulcers with somewhat ragged and very abrupt borders. In some the surface of the ulcer is covered with grey lymph and the conditions suggest spreading, but in others the sore is clean and healing. None of them show any marked tendency to fungate, and it is obvious that all must leave superficial scars.

From the patient Menika. See Plate LXXVI.

The uppermost and the lowest are from near the wrist; the upper one shows the condition of the sore after it had been cleaned by poulticing. The middle figures are from the shoulder and elbow respectively.





PLATE LXXXVI.

ERUPTION AFFECTING THE SOLE OF THE FOOT.

This portrait represents a very common condition in the late secondary period of Yaws. It has been described by many writers and is well figured by Nichols and others, see back Plate F. In Ceylon it is known by the name of Dumas. From the same case as Plate LXXVII., a boy (Hortatula).

Sir W. Kynsey's description :—

This plate illustrates the eruption attacking the foot. It is most painful. The condition is locally known as Dumas. The uplifted, horny cuticle ruptures and gives egress to a characteristic fungoid growth, which becomes covered with a dirty yellow scab.

Some of the sores have healed, others are healing, and others quite recent.

PLATE LXXXVII.

STUDIES OF THE ERUPTION.

The four figures in this plate are studies of the eruption on different parts of the body. All of them show it as producing raised excrescences of a more or less frambœsial type. In one a granulation growth almost blocks one nostril. From the right armpit, the penis, the left nostril and the back of a man named Amaris.

The following are Sir William Kynsey's notes:—

Amaris, a man aged 30 years, residing at Kalugama, eight miles from Kurunegala, on Negombo road. Many people suffering in similar way. Used to eat, drink, sleep, and bathe with people who had similar disease. Single. Labourer.

Had sore on left leg midway between knee and ankle five or six months ago—now healed with raised, dry, healed parangial eruptions around—caused by scratching. His parents, brothers (three), sisters (two), now living, all healthy, at Welhene, ten miles from Negombo, and thirty-eight miles from where he lives. No disease in village where parents now live. Never saw disease until he came to present village.

The eruption first began round the ulcer, then under arms, in armpit, then in nostril, and on penis two months ago.

Mouth and throat normal.

The eruptions under armpit are moist.

Hale & Donaldson, Lith., London.

PLATE LXXXVIII.

ULCER OF LIP.

In this portrait an ulcer with raised, polycyclical borders involves the greater part of the upper lip and border of one nostril. It has a grey, ashy surface.

PLATE LXXXIX.

ULCERATIONS AND PERIOSTITIS. MULTIPLE DACTYLITIS.

In this portrait a full length figure of a boy is given showing numerous scars, some ulcers and enlargements of bones. In Plate XCI. we have a life-size view of the hands of the same patient (Adam, a Moor boy).

The following are Sir W. Kynsey's notes of the case :—

Adam. A Moor boy, three days in hospital. A native of Naramulla, twelve miles from Kurunegala, on the Negombo road.

States that there are many in the same village suffering from a similar disease. "I was told I had eruptions when I was suckling; am 16 years of age; I have no relations living and know nothing of my family history. I live by begging."

There is a lupoid ulcer on the right foot involving the two outer toes.

A cicatrix behind the ankle.

Enlargements on surface of tibia; an abscess in soft parts of leg.

Cicatrices seven in number from the knee to the upper part of thigh.

Cicatrices of old ulcers and three enlargements on the tibia, with a scar on the thigh.

Two scars on abdomen.

Scurfy condition of skin of back.

On elbow and inner surface of forearm there is one large cicatrix.

On the wrist, one large cicatrix.

The thumb, index and middle fingers are normal. The ring-finger is hanging on to the metacarpus by the soft parts only, the proximal phalanx having been absorbed, the result of an abscess without any history of injury. There is a healing ulcer on the little finger.

Scar on shoulder; a healing sore on the elbow with raised edges. A scar with considerable loss of substance and enlargement of the ulna; scar on wrist, and enlargement of both bones; the index finger is enlarged (Dactylitis).

The upper row of teeth projects somewhat over the lower, otherwise normal.

The mouth and throat are normal, with the exception of a little nodular enlargement in the centre of the mouth, over the hard palate.

PLATE XC.

SCAR RESULTING FROM SERPIGINOUS ULCERATION.

The scar is that of a creeping abruptly bordered ulcer, "a typical parangi cicatrix."

Bale & Danielsson, Ltd., London.

PLATE XCI.

SCARS, ULCERS, AND DACTYLITIS.

This plate shows the hands, life-size, from the same case as that represented in Plate LXXXIX. The scars are those of deep ulceration involving cellular tissue as well as skin.

AN

ATLAS OF ILLUSTRATIONS

OF

CLINICAL MEDICINE, SURGERY

AND

PATHOLOGY

(CHIEFLY FROM ORIGINAL SOURCES.)

FASCICULUS XV. (Double Number) OR III. & IV. OF NEW SERIES.

PLATES (WITH COLOUR) XCII. to XCVII.
" (WITHOUT COLOUR) A. to M.

XANTHELASMA AND XANTHOMA

WITH ESPECIAL REFERENCE TO THEIR ASSOCIATION WITH FUNCTIONAL AND ORGANIC DISEASES OF

THE LIVER

WITH PRELIMINARY REMARKS AND ILLUSTRATIVE CASE NARRATIVES.

COMPILED BY

JONATHAN HUTCHINSON, F.R.C.S., F.R.S., LL.D.

LONDON:
THE NEW SYDENHAM SOCIETY.
1902.

102545

XANTHELASMA AND XANTHOMA.

By JONATHAN HUTCHINSON, F.R.S., LL.D.

The present Fasciculus might have been appropriately entitled "**On Disorders of the Liver functions as illustrated by the affections of the skin known as Xanthelasma and Xanthoma.**"

PRELIMINARY OBSERVATIONS.

It would be a great mistake to imagine that the conditions grouped together under these names belong to the special domain of the dermatologist. They are symptoms for the most part of liver-disease, organic or functional, and are of the utmost interest to the general physician. Apart from their chief importance in that connection, they may also, if carefully studied, afford very valuable insight as to the laws of self-infection, of tumour growth, and of the hereditary transmission of germ-material.

The conspicuous feature of all forms of Xanthoma is the accumulation in the meshes of the corium of a fatty material which is usually stained yellow. The staining is probably due to bile-colouring matter, and the coexistence of jaundice—either transitory or permanent—is not uncommon. The fatty material referred to may persist for long periods unchanged, or it may give rise to crystalline accumulations (cholestearin), or it may be re-absorbed and leave no trace. Although it is the essential element which justifies the name, it is not the only one. In varying degrees in different cases there is some overgrowth of the cell-structures of the part affected, and a certain amount of fibroid hypertrophy—in exceptional instances very considerable—is the result. It is by this feature that the disease is brought into relationship with new growths. They are also touched in the fact of heredity, for there is no doubt that quite independently of any personal liver disturbance Xanthoma may occur in several members of the same family, and that it may be developed in several brothers and sisters in their earliest childhood. Some of these cases appear to afford very definite examples of atavism, and, as we here observe the inheritance of a neoplasm without any accompanying derangement of health, we can only suppose that there is actual transference of germ-material. Possibly no other malady approaches so near to a demonstration of this possibility as does Xanthoma, and its evidence is of great value to the speculative pathologist.

The more important conditions which we now know as Xanthoma were originally described by Addison and Gull in the Guy's Hospital Reports under the name of 'Vitiligoidea.' Prior to that observation, the common and slight form, which is almost wholly restricted to the eyelids, had claimed the attention of Rayer,* who had designated

* See Rayer's 'Atlas,' plate 22, fig. 15: "On the eyelids and in their vicinity we occasionally observe little yellowish spots or patches, very much like chamois leather in colour, soft to the touch and slightly prominent, without heat or redness, and often very symmetrically disposed."

it "Plaques jaunâtres sur les paupières." Subsequently the elegant and very suitable name of Xanthelasma was devised by Wilson, and remained in general use for some years, until it in turn was partially supplanted by that of Xanthoma. There are many reasons which might be urged for preferring not to adopt the latter, for the conditions far more closely resemble yellow patches, or plates, than they do tumours; but inasmuch as some relationship with neoplasms must be admitted and the new name has already come into general use, it will probably be convenient not to attempt to recur to the older one as a designation for the whole family. It may, however, be judicious to keep the name Xanthelasma as a designation for the wash-leather patches on the eyelids, to which alone it was originally applied. These never become in any sense tumour-like. They are very different from all the other types, and they are but seldom present with them. When the eyelids are involved as a part of a general eruption, whether in connection with diabetes or with jaundice, the conditions which they present usually differ considerably from the soft smooth wash-leather patch so common as an isolated phenomenon. We shall therefore in the following remarks use the term Xanthelasma as designating the wash-leather patch on the eyelids, and it alone.

Various adjectives—such as 'planum,' 'tuberosum,' and 'multiplex,' referring to the number or condition of the patches; and the epithets 'diabeticorum,' 'palpebrarum,' as defining causation or position—have come into common use in the description and classification of Xanthoma cases. They are of course all more or less applicable to certain states, and will no doubt to some extent retain their position in the future. They must, however, if used at all, be used lightly, and with a clear recognition that the forms so named are by no means wholly distinct the one from the other. Thus 'planum' and 'tuberosum' are constantly met with together; multiplicity is not a feature which differentiates any one form, and the type known as 'diabeticorum' is in a majority of cases unattended by sugar in the urine. These epithets have, moreover, the drawback that they have been used in differing senses by different authorities. For clinical purposes a clinical grouping will be the best, and there will probably not be much difficulty, with those who have had large opportunities of observation, in accepting the following.

Group I.—Xanthelasma (palpebrarum).

The first and by far the largest group is that in which the patches occur only on the eyelids. In these cases the yellow patches are somewhat peculiar. They are soft, flat, and abruptly margined, of a lemon yellow tint, and have been very appropriately compared to chamois- or wash-leather. The thin skin adjacent to the inner canthus of the eyelids is the part usually first affected, and in a large majority of cases the *upper* eyelid of the *left* side leads the way. Later on the eyelids of the *right* side are involved, and patches may occur at the *outer* canthus, or they may become confluent and surround the eye. These patches are usually seen before middle age, and their tendency to increase ceases as years advance. They are often attended by other changes in the nutrition of the skin involved, pigmentation being the most common, but grouped comedones are not uncommon, and serous cysts (sudoriparous?) occasional. Very frequently temporary changes in the pigmentation of the eyelids have been conspicuous long prior to the appearance of the Xanthelasma patches; having occurred either in association with sick headaches, with menstruation, or with pregnancy. Very often the patients are "bilious" subjects. The concurrence of attacks of slight jaundice, or of severe headaches and migraine, is so common that Xanthelasma may be assumed to be almost invariably the result of functional disturbance of the liver. This view of its nature is confirmed by the observation that the patches usually cease to be aggressive, and may even tend to disappear, at the age at which the liability to migraine ceases. They are sometimes, but not often, hereditary, and may then occur in several brothers and sisters.

Group II.—Generalised Eruptive Xanthoma (diabeticorum).

The cases in this group have often a history very similar to that of those in the preceding one. Its subjects are, however, almost invariably of the male sex; sugar in the urine is present in many, the eruption comes out quickly, is generalised and very abundant, and after lasting for some months usually disappears. The patches are also very different from those which are restricted to the eyelids, consisting of little tubercles and not of flat patches. These cases are seldom preceded by Xanthelasma of the eyelids, or by jaundice, and in many features they differ widely from all other forms of the disease. In respect to the regions affected, however, they closely resemble the infantile forms, or perhaps it would be more correct to say the hereditary type resembles them. If, following Murchison and other authorities, we may regard diabetes as implying liver derangement, we may consider Eruptive Xanthoma as revealing the existence of such derangement, and may assume it also in the cases in which no sugar is present.

Group III.—Family Xanthoma.

Xanthoma from inherited tendency.—We encounter inheritance of tendency to Xanthoma under two different conditions. In the first several children in a family may show groups of tumours in certain positions at very early ages, the eyelids being exempt; and in the second the eyelids may be the only parts affected, and the changes usually delayed until adult life. In neither is there, for the most part, any obvious derangement of health, nor any tendency to jaundice, diabetes, migraine, or other of the disorders which appear to evoke xanthoma *de novo*. We are obliged to assume that in some of these cases there is an actual transference of germ material from parent to child, giving a tendency to local changes quite independently of the general health.

It is, however, obviously impossible to assume that liver disturbance has been absent in all these cases on the ground that its indications have not been conspicuous. Children, as well as adults, are liable to disorders which involve the circulation of bile constituents in the blood, and many adults suffer from such occurrences without accounting themselves specially "bilious," or recognizing "sick-headaches."

Group IV.—Icteric Xanthoma. (The Xanthoma of Persistent Jaundice.)

In cases of this group the Xanthoma does not usually begin until some time after the jaundice has been established, and it is usually aggressive. It affects almost all parts of the surface, and produces different local conditions, but it never simulates, at all closely, those usual in the diabetic form. In the soles of the feet and palms of the hands yellow streaks occur, along the natural creases, which are scarcely attended by thickening; whilst on the backs of the hands, on the elbow tips, and other places, thick nodular masses may form. On the eyelids, and at various places on the neck, abdomen, and chest, large groups of small yellow spots may be found. The mucous membranes are sometimes affected, especially those of the mouth; meanwhile the jaundice persists, and the patient's health gradually fails. The subjects of this form are invariably adults, and usually about middle age. There is no preference for either sex. The precise form of liver disease which determines the jaundice has not been sufficiently determined, but it may be assumed to be usually obstructive. It may be doubted whether recovery ever takes place after the condition has been well declared. There are certain cases in which the liver is enormously enlarged and the jaundice very deep. In these, very remarkable approaches to recovery are now and then witnessed, and the liver may return to its normal size.

Group V.—Erratic Forms.

It might perhaps be convenient, though a deviation from arrangement by natural affinities, to construct another group of erratic forms. Certain conditions—for the most part exceedingly rare—have been observed which appear to be in some relation with Xanthoma, but concerning the precise nature of which differences of opinion amongst authorities are more than possible. As our knowledge advances, these will be assigned each to the group with which its ascertained nature most nearly associates it. We may perhaps assume that the comedonous and cystic forms of disease met with in the Xanthelasma positions on the eyelids will be accepted as belonging to the Xanthelasma palpebrarum group. Their acceptance as such is, however, not as yet general. Apart from them, which, in the present summary, I have ventured to assign to the position indicated, we have two other definite conditions, which are illustrated in portraits displayed in the Polyclinic Museum, and which require mention here.

The first of these is an ulcerating form of new growth occurring in elderly persons the subjects of Xanthelasma, and affecting positions near to the eyelids. This condition is chiefly of importance on account of its simulation of malignant action, although susceptible of almost spontaneous cure. It is illustrated by two original portraits in the Xanthoma series in the Museum named. The conditions displayed are very peculiar, and of great clinical interest.*

A second sub-group consists of cases in which children show eruptions not only on the face but also on the trunk, which partake of the features of Xanthelasma and Urticaria pigmentosa. In one instance the conditions of Adenoma sebaceum were also present. The portraits in the museum which illustrate these combinations are four; one is that of a boy under the care of Dr. Barr in the Leeds Infirmary; the second that of a girl who attended some years ago at one of my Park Crescent Demonstrations. The case published by Sir Thomas Barlow, and referred to at page 10, belongs to this group. Of a fourth case, details will be given further on. Although the eyelids are affected, the patches on them are never very closely similar to those of the common type of Xanthelasma palpebrarum. There can be little doubt that inheritance takes a considerable share in the production of the mixed conditions observed in this small group of cases.

* These portraits have been described in 'Archives of Surgery.' Inasmuch as their subjects are still living and might be recognized, their publication at the present time might cause annoyance.

ON POSSIBLE ALLIANCES WITH LICHEN PLANUS, PSORIASIS, AND URTICARIA.

It may seem to some a far-fetched suggestion that there really are some features in certain cases of the diabetic form which might imply that it is a xanthomatous type of Lichen planus. We know little or nothing as to the predisposing causes of the latter, but we know that a symmetrical, monomorphous eruption is rapidly developed over the whole surface, showing remarkable preference for certain parts, and prone, after a certain duration, to disappear spontaneously. These statements are true also of diabetic Xanthoma, and in both maladies we may assume with probability that something of the nature of self-infection occurs, and the first papules are in some way the parents of the rest. There is nothing in the distribution of either eruption to imply that the nervous system is specially concerned. Both eruptions, when they disappear, leave the skin perfectly sound, and the disappearance is absolute and complete. It has been observed respecting Lichen planus that returns of the eruption are apt to occur after many years' interval. This has perhaps never been as yet witnessed in the case of Xanthoma, but this circumstance may be due simply to the fact that cases of the latter are rare, and have not been observed over a sufficient length of time.

The fact that in many cases of juvenile Xanthoma, and some of the diabetic type, a preference is shown for the psoriasis positions—the tips of elbows and fronts of knees —cannot have escaped the notice of any well-experienced observer. This is well illustrated in Plate XCV., and again in Plates A, I, J, and L. It is possible, but by no means probable, that the morbid processes are in each instance located chiefly by local irritation. It is much more likely that some as yet unrecognized influence is at work which is of the same nature in both maladies. It is surely very important to take note of these curious features of similarity between diseases bearing different names, and very different in their general characters. We must not be too eager to erect into distinct species groups of phenomena which may possibly after all have their relationships.

In connection with this suggestion, it is of interest to note that in a case ably recorded by Mr. Malcolm Morris the eruption began by a group of papules on each elbow, and that, after having thickly covered the extensor surfaces of all the limbs, it disappeared under the influence of arsenic from all excepting the localities named. A month or six weeks after this almost complete disappearance "an extensive recurrence of the rash took place," and the eruption became more abundant than ever. It disappeared finally two months later. Obviously we have here facts which suggest relationship both to Psoriasis and Lichen planus.

It is of interest also to note that in some instances it is difficult to dissociate the eruption from Urticaria pigmentosa. So high an authority as Dr. Radcliffe Crocker has used the term "*Xanthelasmoidea*" in application to certain forms of the latter malady.

DESCRIPTIONS OF DRAWINGS AND MODELS.

It may be convenient, before proceeding with further remarks, to introduce here a descriptive list of all the portraits illustrative of the various forms of Xanthoma which have been collected in the Polyclinic Museum, and also of the casts in the Museum of the Hôpital St. Louis, in Paris. We shall thus obtain in some degree a clinical basis for the statements and comments which are to follow.

BRIEF DESCRIPTIONS OF ALL THE ILLUSTRATIONS OF XANTHELASMA AND XANTHOMA IN THE POLYCLINIC MUSEUM.

Adopting the classification proposed, we have the following:—

Series A.—Xanthelasma (palpebrarum).

Definition.—The form occurring as patches on the eyelids resembling chamois-leather. In most cases curving round the inner canthus in the first instance, and only involving other parts of the eyelids in more advanced stages.

No. 1.—*Xanthelasma palpebrarum. The common form.*

This portrait represents the face of a woman, and shows two symmetrically placed yellow patches above the inner canthus of each eye. The patches are about as large as sixpences, and have no satellites. See 'Illustrations of Clinical Surgery.'

(Original, J. H.)

No. 2.—*Xanthelasma palpebrarum. The common form.*

In this portrait crescentic patches curve round the inner canthus, and involve both upper and lower lids equally. They are symmetrically placed and of equal size. At the outer canthus of the left eye there is a small spot.

(Original, J. H.)

No. 3.—*Xanthelasma palpebrarum. The common form.*

A lithograph from Dr. Radcliffe Crocker's 'Atlas,' showing the eyelids of a woman, æt. 38, who had suffered much from migraine. A sister was said to be in a similar condition. The yellow patches are seen almost symmetrically placed above and below the inner canthus, but they are detached and do not meet across it. This portrait is of great value as illustrating a case in which tuberous Xanthoma followed the affection of the eyelids.

The knees and elbows were subsequently affected, and the conditions steadily advanced. Seven or eight years after the patches on the eyelids had been first observed, she became jaundiced, her liver was large, and she had ascites. Sequel not known.

No. 4.—*Xanthelasma palpebrarum. The common form.*

A portrait taken from Kaposi's 'Atlas,' Tafel 36o. The face of a woman. The patches are in the usual positions, but extend over the whole length of the upper eyelids, and consist of grouped spots, many of which have not become confluent with the larger one. (Number 10, Frame B.)

No. 5.—*Xanthelasma palpebrarum. The common form in association with jaundice and tubers on elbow.*

The face of a man of jaundiced aspect. The patches on the eyelids are in the usual positions, but by far the largest are on the lower lids. On the left side there is a small patch on the outer canthus. The elbow of the same patient is represented, and shows a group of yellow spots over the ulna a little below the olecranon. This portrait is labelled by Prof. Kaposi "Xanthoma planum palpebrarum et tuberosum cubiti. Icterus." Probably the Xanthelasma of the eyelids preceded the icterus, &c.

No. 6.—*Punctate form of Xanthelasma followed by jaundice, etc.*

A portrait of Mrs. Smallwood, æt. 60, Dr. Abercrombie's patient. Both eyelids on both sides show large patches of confluent spots. This patient subsequently became jaundiced, and had diffuse Xanthoma of other parts. (See plates in this 'Atlas.')

No. 7.—*Xanthelasma with serous cysts (sudoriparous?)*

The upper face of a woman, æt. 46, in whom cysts (sudoriparous) were present, as well as the yellow patches. The latter are small, but were quite definite. The cysts and yellow patches are arranged in the usual positions, curving round the inner canthus. The woman had experienced severe attacks of liver disturbance. Her case is described in 'Illustrations of Clinical Surgery.' It is perhaps the only extant por-

* It has been proved respecting this form of Xanthoma of the eyelids that it may affect several members of the same family, although not beginning in very early life, and that it may sometimes occur in several generations. In such cases there is usually but little evidence of liver disturbance. In some cases there is hereditary gout. See Report in 'Transactions of the Royal Medical and Chirurgical Society.'

trait showing the cystic complication of Xanthoma, but several others have been under observation. The cysts were excised, and some small ones were reproduced. A detailed report on Xanthelasma palpebrarum, details of cases, &c., will be found in Hutchinson's 'Illustrations,' vol. i. p. 145. An earlier report on the same subject is in the 'Medical and Chirurgical Transactions,' vol. liv., 1871. See case, p. 15 in Medico-Chir. paper.

[Original, J. H.]

No. 8.—*Xanthelasma with comedones.*

The upper face of a woman, showing in the usual Xanthelasma positions groups of isolated yellow spots. Most of these contained yellow sebum, and in some the blackened orifice is depicted; others, however, consisted of the usual yellow wash-leather structure.

No. 9.—*Grouped comedones in the Xanthelasma positions.*

The left eyelids of a man showing the comedonous form of Xanthelasma arranged in the ordinary positions curving round the inner canthus.

[Original, J. H.]

No. 10.—*Xanthelasma with a single comedo.*

The left eyelids of a man showing a single spot of comedonous Xanthelasma, with a black spot in its centre, situated just above the inner canthus.

[Original, J. H.]

No. 11.—*Grouped comedones in Xanthelasma positions in a young girl.*

A coloured photograph, life size, representing a group of comedonous spots just above the inner canthus in a girl aged about fourteen. There were none on the other side.

[Original, J. H.]

No. 12.—*Grouped comedones in Xanthelasma positions in a woman.*

The face of a woman, æt. 53, showing grouped comedones in the Xanthoma position on both sides. She was of dark complexion and sallow, with deep pigmentation of her eyelids, and had suffered much from migraine and rheumatic gout.

Dr. Radcliffe Crocker's 'Atlas.'

No. 13.—*Grouped comedones in Xanthelasma positions in a woman.*

An oil painting, with also a coloured photograph, representing the face of a woman of about 50. Both eyelids on both sides are occupied in the Xanthoma positions by grouped comedones. These are most extensive on the upper lids. None of them are yellow, and all show black points.

Given to Mr. Hutchinson. From a patient who was an inmate of the Halifax Infirmary.

No. 14.—*Grouped comedones near the Xanthelasma positions in a man.*

The full face of a man showing large patches of grouped comedones curving on the lower lids and just below the inner canthus. The patches have yellow borders, but they consist solely of associated comedones, all of which show black points.

[Original, J. H.]

Series B.—Xanthoma juvenile.

The term congenital has sometimes been used in reference to this form, but it is seldom actually present at birth. It begins in young children, and is—in some instances at least—aggressive through life. Our collection contains some most interesting illustrations of it. In some instances it may be that the disease is acquired and not inherited.

Nos. 1, 2, & 3.—*Xanthoma juvenile in a young child.*

Three water-colour drawings from the same case. One represents the heel and the back of leg, another the knee, and another the elbow. In all these positions there are groups of little yellow papules, some of which have become confluent. Those on the elbow are the largest, and may be described as tuberous. The patient who was the subject of these sketches was a healthy little girl of five or six, the daughter of a Norfolk farmer. She was sent to Mr. Hutchinson by Mr. Cadge, of Norwich, in May, 1891. There was no evidence of liver disease. She was seen only once.

[Original, J. H.]

Nos. 4, 5, & 6.—*Xanthoma juvenile in an adult.*

Side by side with the above are three photographs taken from the Saint Louis Hospital collection (in Paris) from a patient under the care of Dr. Thibierge. These photographs are from an adult, and are most interestingly supplementary to the preceding ones. They show on the knee, elbow, and heel exactly in the same position as in the preceding—thick tuberous masses of large size. The growths appear to be, in places, at least half an inch thick, and are almost as large as the palm of the hand. Another photograph from the same case shows a group of papules still discrete on the left buttock. This portrait is perhaps the only one in demonstrative proof that the papules of the juvenile form of Xanthoma may grow indefinitely. It had generally been believed that they grew during the first few years of life, and were then arrested.

No. 7.—*Xanthoma juvenile in a child.*

A lithograph representing the buttocks of a girl whose case was described by Mr. James Startin at page 373 of the 'Pathological Transactions,' vol. xxxv. The disease had begun at the age of two, and a brother showed similar conditions. Both buttocks, both elbows, and both popliteal spaces were affected. There was also

a patch on the calf of one leg, and one on the nape of the neck. There was gout in the family.*

A committee on this case, consisting of Dr. Crocker, Dr. Sangster, and Mr. Hutchinson, reported that the malady in children appeared to have no connection whatever with jaundice, or any other form of ill-health, and that it was probably hereditary. Evidence was obtained that, in one instance, a paternal grandfather had suffered from the same affection.

No. 8.—*Xanthoma juvenile in a boy.*

The portrait showing the eyelids and arm of a boy aged 7. He had typical chamois-leather patches irregularly placed. One was near the right external canthus, and another just over it. There were patches also on the left eyelids, on one ear, and on one shoulder. It was said that the patches on the eyelid had been noticed directly after birth, but that they had increased latterly. The boy was pallid and poorly developed, but he had had no special liver symptoms. There was gout in the family, and his father suffered from psoriasis.

(Sir Thomas Barlow. Full details in 'Pathological Transactions.')

No. 9.—A mixed form in association with Adenoma sebaceum.

A portrait of considerable interest in connection with the preceding, as illustrating an erratic form of xanthoma in childhood, is that of a girl whose case was published by Mr. Hutchinson in the 'Archives of Surgery.' The portrait shows the girl's face, life-size, and her back, by Miss Green. On the face were many spots not unlike those of Adenoma sebaceum; but on one eyelid, on the forehead, and on the back, there are others which resemble Xanthoma. On the back the patches were arranged somewhat in streaks; nowhere were they symmetrical.

No. 10.—*A mixed form in association with Urticaria pigmentosa.*

A porttait given me by Dr. Barrs, of Leeds (see 'Lancet' for May 12th, 1888). The patient was a boy of seven, in good health. The eruption had first been noticed when he was a year old, and had been subject to some variations. It was strictly confined to the trunk and scalp. There were five patches of some size and with very distinct thickening, and around them were a number of smaller ones, varying from a pin's head to a lentil. They were of uniform wash-leather tint. Nothing of importance was elicited in the family history.

No. 11.—*Xanthoma juvenile in a child.*

A portrait of the upper arm of a child aged 3—Dr. McCall Anderson's case.† The portrait shows a large group of discrete yellow papules over the upper arm from the shoulder downwards. The child was an orphan, and it was not known how long the eruption had been present. The eruption was symmetrically placed on the face, neck, shoulders, arms, and legs. The general health had not failed. The case is described in detail in the 'British Medical Journal' for Dec. 3rd, 1892. No details as to the sequel are obtainable.

Series C.—Eruptive Xanthoma (often in association with diabetes).

In the cases of this class the eruption frequently comes out very rapidly, and may affect the surface of the body very extensively, and without special regard to localisation. It is never preceded by Xanthelasma of the eyelids, nor is it ever attended by jaundice. There is, however, frequently the history of migraine and sick headaches. A definite tendency to spontaneous cure, so that within a year or less the disease may entirely disappear, is often observed. It does not appear to pass into any of the other forms of Xanthoma, but may be attended by striæ in the palms.

We have excellent illustrations of this form of the disease from six cases. The Continental Atlases do not afford any portraits of this form, but several have been published in foreign journals, and some in America.

Nos. 1, 2, & 3.—*Eruptive Xanthoma without diabetes.*

The portrait of an adult man, whose case is given in detail in 'Archives of Surgery,' vol. i. p. 361.

The scalp, nose, and adjacent parts of cheeks, the chin and upper part of chest, are covered with lemon-yellow papules, varying in size from a sixpence to a split pea.

A photograph represents the conditions on the upper parts of the thighs and adjacent part of scrotum; in this region the papules had become confluent. The patient was a man who was sent to Mr. Hutchinson by Dr. Williams, of Barrow-in-Furness. He had suffered severely from bilious attacks, but had never been jaundiced. The eruption had developed quickly, and subsequently in the course of about two years it wholly disappeared. His urine was repeatedly examined, and never contained sugar.

[Original, J. H.]

Nos. 4, 5, & 6.—*Eruptive Xanthoma with saccharine urine.*

Three coloured lithographs illustrating a case published by Dr. A. R. Robinson, of New York. The portraits show discrete yellow tubercles with vividly congested borders, but upon pale skin. They are scattered in great abundance over the buttocks, abdomen, and thighs, occurring in little groups and lines. A few are shown on the front of a forearm.

Microscopic examination showed that the papules had a structure like that of the wash-leather patch.

British Journal of Dermat., April, 1891. Extract book, p. 71.

* A full report of these and some similar cases under the care of Dr. Stephen Mackenzie and others will be found in the volume of the 'Transactions' referred to.

† The epithet "multiples," which is given to this case and some others, appears to be useless, since all cases of Xanthoma are multiple.

No. 7.—*Eruptive Xanthoma with saccharine urine.*

A portrait of a man, æt. 52, who was under the care of Dr. Barratt, of St. John's Hospital. The eruption had been out about six weeks. It was almost confined to the limbs (including in that term the haunches and shoulders). It consisted of little firm papules about the size of peas, of a dull but deep yellow colour. There was not the slightest congestion of the intervening skin. Most of the spots were slightly umbilicated, and many showed a peculiar 3-lobed form. It appeared probable that they had formed around hair follicles. His urine was of high specific gravity, and contained much sugar, but he asserted that he was in good health, and had never in his life been bilious. There were no Xanthoma patches on the eyelids.

No. 8.—*Eruptive Xanthoma with saccharine urine.*

A coloured lithograph from a case published by Dr. Bristowe in the 'Pathological Transactions.' The patient was a tailor, æt. 43, in whom the eruption occurred on the hands, wrists, feet, ankles, elbows, knees, and buttocks, the rest of the skin being everywhere quite healthy. The patches consisted of aggregations of tubercles from two or three to a great number. The patient complained of painful pricking sensations. On the hands and feet the patches were present both back and front. The disease had first made its appearance four and a half years before, beginning on one elbow, and next on the knees. The patient had previously enjoyed good health, but he subsequently began to complain of pain in the loins, and to pass an excessive quantity of urine. The urine had a specific gravity of 1040, and contained a large quantity of sugar. There was no emaciation, and the appetite was not excessive.

This case is important as supplying in some respects a connecting link between the Xanthoma of diabetics and the more chronic form. The spots had not developed with the profusion and rapidity which is usual in the diabetic form, and had persisted with steady aggravation for several years. Subsequently, however, the disease did undergo great improvement, and many of the tubercles and patches disappeared, all of them having become less prominent and less distinct. Dr. Bristowe did not think that the medical treatment had had anything to do with the improvement. The diabetic condition persisted, but the patient retained good health, having neither excessive thirst nor appetite.

No. 9.—*Xanthoma with diabetes.*

A portrait copied from Dr. A. R. Robinson's paper representing the distribution of the eruption in his case of Glycosuria with Xanthoma. The abdomen shows small papules very rarely confluent in great numbers over its lower half. Papules, all of small size, are also seen over the front of the thigh, and a few isolated ones on that of the left upper extremity. The small size and uniformity of the papules and their tendency to remain discrete are noteworthy features.

Another portrait from the same case shows the arrangement of the eruption on the back and buttocks. It is abundant on the latter. To this is appended a study of the eruption in the case published by Dr. Robinson. (See Plates C, D, and E in this Fasciculus.)

No. 10.—*Eruptive Xanthoma in a boy.*

An almost full-length portrait, showing the arrangement of the eruption on the front aspect of the trunk and all four limbs. It occurs in grouped patches of small papules which are often confluent over the sides of the trunk and all parts of the limbs, avoiding the middle line of the trunk and the genitals. It is very abundant about the axillæ. The apparent exemption of the neck, wrists, and parts below knees must not be trusted, as the portrait is not from a photograph. (See Plate B in this Fasciculus.)

Series D.—Xanthoma with jaundice.
(Obstruction of Bile Ducts, or Organic Disease of Liver.)

Some of the cases in this series were originally described under the names of Vitiligoidea and Keloid. Not infrequently in the same patient the conditions are both tuberous and flat. The term linear is sometimes applied to the latter when occurring in flexures of the hand, &c. In this form of Xanthoma the eyelids are almost always affected, and very often the changes begin on them.

Nos. 1, 2, & 3.—*Persisting jaundice with Xanthoma.*

Life-sized portrait of an elderly woman who was under the care of Dr. Abercrombie in the Charing Cross Hospital. She was emaciated, had for long been deeply jaundiced, and had an indurated liver.

Three portraits in our collection show her face, the side of the abdomen, and the palmar aspect of the right hand and forearm. On both eyelids on both sides, covering almost the whole of their extent, there are light yellow groups of Xanthelasma spots, which have become confluent. On the side of her abdomen, on skin of a dark mahogany tint, there is another large group of similar spots, which may be taken as representative of others in other parts. Almost the entire surface of the palmar aspect of the digits, the palms, and wrists were occupied by these light yellow streaks and patches. Their tint was everywhere much lighter than that of the jaundiced skin.

Nos. 4, 5, & 6.—*Persisting jaundice with Xanthoma.*

A hand in a very similar state to that just described (Dr. Abercrombie's patient) is depicted in Dr. Radcliffe Crocker's 'Atlas' (see Frame A, 1, 2, & 3). With it also are given portraits of one knee, and of the eyelids. On the knee the condition is a group of small papules, some of them confluent, but for the most part discrete. The eyelids have been already described.

These portraits, with several others, are of much value in proving that the terms "tuberosum," "planum," "lineare," "striatum," &c., designate different conditions of the same disease as modified by the part affected.

Nos. 7, 8, 9, & 10.—*Portraits of jaundice with Xanthoma, from Kaposi's 'Atlas.'*

From Kaposi's 'Atlas' we have several portraits illustrating Xanthoma with jaundice, but, as no details are given, it is difficult to know whether or not they all belong to different cases. Tafel 364 is named Xanthoma striatum, and shows streaks of yellow along the flexures of the palm and digits.

Tafel 363 shows more extensive diffusion of the disease, and is named "Xanthoma planum et tuberosum." The knee, possibly of the same patient, is depicted in Tafel 362 as Xanthoma tuberosum. It shows a large group of discrete yellow papules on the front of the knee.

Tafel 365 shows a large group of small papules, almost black in colour, on a deeply jaundiced abdomen. "Xanthoma tuberosum confertum abdominis."

Tafel 366, on a skin almost black with jaundice, shows very large patches of small papules on both buttocks.

Nos. 11, 12, & 13.—*Jaundice with tuberous Xanthoma.*

Three coloured lithographs taken from the 'Pathological Transactions,' vol. xix., illustrating a case reported by Dr. Hilton Fagge. A figure in plate xvi. shows a tuberous mass over the olecranon, while plate xv. shows similar tubers on the back of the hand of the same patient. They were very firm and hard, but freely movable. Some had developed on the extensor tendons. It is stated that about the finger joints they bore a strong resemblance to gouty enlargements. They were of a reddish colour, and usually very tender. Other yellow tubercles are seen near to the principal ones. The left eyelids are shown in fig. 3. Two patches are seen, one on the upper and one on the lower lid in the usual positions, and a third at a little distance near to the outer canthus. In fig. 2 the everted lower lip of the patient is shown, with yellow deposit in it, close to its junction with the gum. [Refer to a report by Dr. Pavey upon the same case in the Guy's Hospital Reports. Mrs. L. L. 1866.]

Nos. 14 & 15.—*Black jaundice with Xanthoma.*

Two woodcuts without colour, illustrating a case reported by Dr. Stout in the 'American Journal of Cutaneous Diseases,' June, 1894. The patient was a woman of 50, who had suffered for four years from jaundice. Although she retained fair health, she was the colour of a mulatto, and it was believed that a gall-stone could be felt in the gall-bladder. Xanthoma had first appeared symmetrically on the upper lids in the usual positions. Next the palmar surfaces of both hands had suffered, and subsequently papules in groups had been developed on the trunk and various parts of the extremities. There were some between the toes. They exhibited bilateral symmetry. On the limbs the little tubercles had for the most part remained discrete.

No. 16.—*Xanthoma of the palms with jaundice.*

The palms of hand from one of Dr. Radcliffe Crocher's cases showing striæ on the lines of flexure of palm and digits, and also groups of papules on the intervening surfaces of the latter.

No. 17.—*Xanthoma papules on the knee with jaundice.*

A portrait showing a large group of papules on the front of an adult knee. From Kaposi's 'Atlas.'

No. 18.—*Xanthoma of the palm with jaundice.*

A portrait showing striæ of yellow deposit in all the flexures of the palm and digits. Crossing the wrist transversely are lines of small papules arranged exactly as such are often seen in lichen planus.

No history is forthcoming with this plate, which is Tafel 364 in Kaposi's 'Atlas,' with the designation "Xanthoma striatum palmæ manus."

No. 19.—*Xanthoma of the palm with jaundice.*

The palmar aspect of a large adult hand, showing not only striæ on the lines of flexure, but large patches of yellow discoloration. These patches involve almost the whole palm and much of the digits, but with the exception of the thumb they avoid the terminal pulps. Jaundice was present, but no further particulars can be given. The original is Tafel 363 in Kaposi's 'Atlas,' with designation, "Xanthoma planum et tuberosum palmæ manus. Ikterus."

Series E.—MIXED FORMS.

No. 1.—*Tuberous Xanthoma in exceptional position.*

A coloured lithograph published by Dr. Prince Morrow, showing a tuberous form of Xanthoma affecting the soles of the feet. Numerous patches are seen on those parts chiefly exposed to pressure, the hollow of the arch being exempt. Some of the patches are inflamed and superficially ulcerated. The chains do not run in lines, as usually seen in the palms of the hands, but occur in quite isolated groups. The eruption consisted of pale yellow nodules, hard and shotty to the touch, and deeply set in the skin. The condition extended on the back of the heels, producing protuberant broad masses. The growths were hard and corneous. There were groups of similar nodules on the fronts of both knees. It is stated that there had been some on the backs of the hands. The conditions had been present on the feet about three years, and on the knees about two years. Those on the sole of the foot had been very painful. The patient was a man æt. 45. There was no jaundice, nor any diabetes.

No. 2.—*Xanthelasma following jaundice, with Xanthoma on elbows, and swelling of tendons.*

A portrait showing the elbow of a man æt. 44. He was of dark complexion and of rich brown skin. He inherited gout, and had suffered from it on several occasions. He had very conspicuous patches of the chamois-leather Xanthelasma symmetrically placed in the usual positions on the eyelids. These had followed a slight attack of jaundice eighteen years ago.

He had curious enlargements of many tendons, and above his heels, symmetrically placed, were bossy projections, which involved both tendon and skin. The portrait shows a swelling as large as half a pigeon's egg on the back of the olecranon, at the base of which and

surrounding it is a yellow wash-leather tissue, quite definitely of the nature of Xanthoma. The greater part of the swelling is, however, not yellow. On the other elbow there was a similar condition of things on a much smaller scale.

This portrait illustrates, as do many others, the association of Xanthoma with gout. The greater part of the lesions of tendon, periosteum, &c., were probably gouty, though possibly not wholly so. The condition of the skin above the heels somewhat resembles that shown in the Paris photograph. The case is detailed in the Clinical Society's 'Transactions' of 1889.

[Original, J. H.]

The following is a list of the Models in the Museum of the Hôpital St. Louis, in Paris, which illustrate Xanthelasma and Xanthoma :—

123. Vitiligoïdea, Molluscum cholestérique. Bazin, 1869. — Main (même malade que le no. 124). Xanthome; Inv. 1889.

124. Vitiligoïdea, Molluscum cholestérique. Bazin, 1869. — Régions fessières (même malade que le no. 123). Xanthome; Inv. 1886

366. Xanthome; Xanthélasma. Vitiligoïdea des Anglais. —Mains. Lailler, 1875.

1090. Xanthome. — Main gauche, face dorsale et palmaire (voir le no. 366, même malade). Lailler, 1885.

542. Xanthome; Xanthélasma. Gland. Hillairet, 1878. — Paume de la main gauche (voir les nos. 543 et 544, même malade).

543. Xanthome; Xanthélasma. Paume de la main gauche (voir les nos. 542 et 544, même malade). Hillairet, 1878.

544. Xanthome; Xanthélasma. Main gauche, face dorsale. Variété tubéreuse (voir les nos. 542 et 543). Hillairet, 1878.

654. Xanthome multiforme. Coude (voir les nos. 655 et 656, même malade). Besnier, 1880.

655. Xanthome multiforme. Main gauche, genou (même malade que les nos. 654 et 656). Besnier, 1880.

656. Xanthome plan. Régions fessières (même malade que les nos. 654 et 655). Besnier, 1880.

1043. Xanthome. Main gauche; région fessière; genoux. Besnier, 1885.

1393. Xanthome tubéreux, chez un glycosurique. Genou, main gauche. Fournier, 1888.

The portraits illustrating Xanthelasma and Xanthoma which are to be found in Kaposi's 'Atlas' have been included in the list of those in the Polyclinic Museum Collection. It is of interest to note that, whilst this extensive and invaluable series includes good illustrations of Xanthelasma (of Eyelids) and of the Xanthoma of Icterus, it gives none of the diabetic form, nor any of that which occurs in children. There is, however, in Tafel 30, the portrait of an adult man covered by an eruption of yellow spots arranged exactly like that of Xanthoma of diabetics. It is named "Favus universe dispersus incipiens," and we must not presume to doubt the diagnosis. There are, however, possibilities of mistake in the course of passage of an original drawing through the printer's hands, and it is difficult not to suspect that one has here occurred. We in England, at any rate, know nothing of an "incipient" form of "Favus" which should break out over the whole body and limbs of a grown-up man, and we know well Xanthoma diabeticorum, which does assume these conditions. It would be curious if no single instance of this malady had ever presented itself in the Vienna Clinic.

ON THE MUTUAL RELATIONSHIPS OF THE SEVERAL FORMS.

At first sight it might appear that the differences between the several forms of Xanthelasma and Xanthoma are such as to separate them into distinct maladies. Nor can we wonder that not a few observers have been anxious to assert this distinctness. A comprehensive view of the whole facts—such as will, it is hoped, be afforded by this memoir—will convince anyone of adequate patience for the task that it would be an arbitrary and wholly mistaken procedure to attempt such separation. The various conditions comprised under these names have, it is most true, very marked features of difference, but they have a bond of essential connection. That bond is their association with disturbed function of the liver, and the fact that their colour, which is their most peculiar characteristic, is in all probability in all cases derived from bile constituents. Links of connection between even those forms which appear most widely apart are to be found on all hands. Thus in some cases of diabetic Xanthoma the eyelids are affected, and in many there is a history of liability to liver disturbance precisely similar to that usually met with in cases of simple Xanthelasma limited to the eyelids.

The cases of diabetic Xanthoma further show their relationship with the persistent form which accompanies jaundice by exhibiting occasionally the streaks in the flexures of the palms and digits, and by the development of tubers on the elbows and knees. Nor has it by any means been proved that in all cases of this form the eruption tends to disappear.

The common wash-leather patches on the eyelids—for which it is here proposed to retain the name Xanthelasma—undoubtedly differ more in clinical history and in usual course of development from the other forms of Xanthoma than do any of the latter from each. It is on account of this marked difference that the retention of the old name is advocated. Yet it is not difficult, even respecting them, to discover facts which clearly denote relationship. They are not infrequently preceded by attacks of actual jaundice, and yet more commonly by repeated attacks of illness which closely approached to jaundice. The relatives of those who show them are frequently very definitely the subjects of liver disturbance. These patches sometimes precede the generalised Xanthoma of jaundice, and are at others a part of the eruption which follows jaundice.

Messrs. Malcolm Morris and Dr. Jackson Clarke write respecting Xanthoma diabeticorum that "sugar in the urine is a constant feature." This is certainly not true, unless we refuse to place in this group any case in which sugar is absent. Out of five cases recently demonstrated at the Polyclinic—all of them exceedingly well-marked examples of the malady—the urine contained sugar in only one. In the patient, whose portrait is given in 'Archives of Surgery,' vol. vi., p. 270, and in whom the eruption was perhaps more abundant than in any other recorded case, the urine was examined repeatedly, and no trace of sugar ever found. It may be added that in this case the eyelids were affected, though not by patches at all closely resembling those of Xanthelasma.

Dr. S. Pollitzer, of New York, has described a remarkable case, in which a lad of 15 became the subject of epilepsy and diabetes, which proved fatal. The whole duration of his illness was from three to five years. The quantity

of sugar in the urine was large, and there was also a small amount of acetone. His eruption consisted of nodules varying in size from a millet seed to a bean, which had yellow centres, but were surrounded by red borders. Some of them projected strongly, or were almost mushroom-shaped. They occurred in the usual positions, and were most numerous on the knees and elbows. On the buttocks and backs of thighs they constituted by coalescence an unbroken sheet. In the soles and palms were deeply placed painful nodules. Nothing is said as to the eyelids, and presumably they were free.

Dr. Pollitzer has also recorded another case which in all respects fits with Xanthoma diabeticorum, with the exception that there was no sugar in the urine. The patient was a bilious man, aged 31. "The rash" had attained its then present condition two years before the observation, and had since remained unchanged. It consisted of lemon-yellow nodules, from a mustard seed to a lentil in size. It occurred on the elbows, knees, hips, and buttocks, having begun on the feet. In some instances the yellow nodules were placed on reddened skin. A few nodules occurred over the tendo Achillis. The man had been liable to severe attacks of hypogastric pain, possibly implying the passage of gall-stones. There was gout in the family. There were nodules in the soles. Inasmuch as no sugar was present, this case is designated "Xanthoma tuberosum multiplex."

It would seem that in Xanthoma diabeticorum the early stage of the papule is not attended by any elements of a yellow colour. A yellow nodule appears in the centre of a papule, which at first showed only the red tint of vascular congestion. This nodule in most cases soon occupies the whole papule, but not infrequently to the last there is a somewhat red border.

The changes in this form begin more deeply than in Xanthelasma, and advance to the surface.

The best description of the histology of the diabetic Xanthoma is that given by Dr. J. Jackson Clarke in the 'British Journal for Dermatology,' August, 1902, p. 246. Dr. Clarke dealt with recent specimens from a well-diagnosed case, in which sugar was present in the urine, and in which ultimately the eruption wholly disappeared. The clinical narrative is by Mr. Malcolm Morris.

Dr. Clarke writes concerning Xanthoma diabeticorum:—"Sections of such a ripe papule cut fresh, and mounted either unstained or stained in picro-carmine, presented the same appearance as ordinary Xanthoma palpebrarum similarly prepared. The small veins and capillaries of the affected part of the corium were surrounded by small round cells, and formed the centres of collections of bright globules and granules."

Dr. Prince Morrow has published a somewhat exceptional case, in which, as in Dr. Pollitzer's, the eruption began on the feet, and was throughout most abundant on them. It had been present four years when the notes were taken. Both knees were covered with papules about nine months from the beginning, and somewhat later the eruption appeared on the back of the left hand. The papules varied in size from a millet seed to a peppercorn, but were often grouped so as to form large patches or even protuberant brawny masses. They were of pinkish yellow tint, but yellow only when compressed and emptied of blood. The feet were disabled by the pain caused by pressure. There were superficial ulcerations on some of the papules. It may be noted that similar superficial excoriation occurred also in Dr. Pollitzer's diabetic case. There had been neither jaundice nor diabetes.

Several authors have mentioned affections of the nails in connection with Xanthoma. In Pollitzer's diabetic case, the nails had at one time been detached. In a case of Kent Spender, in which the palms and soles were yellow, the nails of the left thumb and right great toe were detached by the accumulation of dry chalky material. In Morrow's case there was "an agglomeration of neoplasms" under the nail of one toe, and isolated growths under the free edges of other nails.

Xanthelasma with Xanthoma in a Child.

Dr. G. T. Jackson's case, a report of which is given in the description of Plate B, affords a very remarkable example of the coincident occurrence of Xanthelasma of the eyelids in association with a general eruption resembling that of the Xanthoma of diabetics. These conditions occurred in a young child in good health, and had been noticed during the first few months of life.

Unfortunately no facts were obtained as to the patient's progenitors, and we can only conjecture that it was inherited.

As in all the other cases in which young children have shown Xanthelasma of the eyelids, the conditions deviated somewhat from the usual type. Thus the chamois-leather patch occupied the whole length of the lower lid, and did not, as usual, curve round the inner canthus. On the upper lid nothing is described but "a small tumour."

Xanthoma diabeticorum possibly with Inheritance.

A coloured portrait in illustration of Xanthoma and diabetics is given in a paper by Dr. Toepfer in the 'Archiv für Dermatologie,' 1897. It represents the arm of an engineer, aged 42. His father had died of some liver affection. In the boy, at the age of ten years, some little tumours had been observed. The man had been for some years the subject of diabetes. The portrait represents small discrete Xanthoma nodules scattered over the back of the upper extremity. They are grouped in a patch, apparently with considerable thickening of skin, over the olecranon, but, as usual, although they touch they do not coalesce.

The narrative is accompanied with good details of description, and some excellent microscopic illustrations.

CASE-NARRATIVES

IN ILLUSTRATION OF XANTHOMA PALPEBRARUM, AND OF THE NERVOUS, BILIOUS, AND OTHER PHENOMENA WHICH OFTEN PRECEDE IT.

Xanthelasma in both upper and lower eyelids on both sides.

An old lady of dark complexion was the subject of Xanthelasma in both upper and lower eyelids on both sides. The disease consisted of groups of isolated flat-topped papules. None of them were larger than peas. Some were yellow, and others greyish white. They were placed in the usual positions above and below the inner canthus. Their subject was apparently in good health. She had never been the subject of jaundice. She considered that all her life she had been very bilious, but never liable to sick headaches. When asked what she meant by being bilious, she stated that she had been liable to sickness from slight causes, and was obliged to be very particular as to what she ate. (*Case 20 in Table. See Clinical Illustrations*, vol. i.)

Two brothers of dark complexion affected alike. Both liable to temporary pigmentation of eyelids.

Dr. Langdon Down, many years ago, kindly supplied me with the particulars of three cases of Xanthoma palpebrarum, himself and his brother making two of them.

Dr. J. L. D. was then about 42 years of age, and of a somewhat anxious temperament. He had, however, an excellent digestion, and never suffered from sick headache. He inherited a tendency to gout. He was, as all his friends knew, of very active habits and of an abstemious mode of life. He had had a xanthelasmic patch in his left upper eyelid for two years, and a very small one was just appearing over the right one. Dr. D. was of very dark complexion, and was getting grey rather early. He had a very dark areola round his eyes, especially marked, as usual, on the inner halves of the lids. He told me that for many years his friends had been accustomed to recognize the fact, when he was feeling tired, by observing the peculiarly dark areola which formed around his eyes. His patients even had sometimes noticed this, and no doubt this condition had been far more marked in him than it usually is. It had been produced by mere nervous fatigue, want of sleep, over anxiety, &c., and had never been attended by any disorder other than is included in the popular expression of "feeling seedy."

Dr. D.'s brother was twenty years older than himself, and had suffered much from headaches. He was also of very dark complexion. He had large patches of Xanthelasma on his eyelids on both sides. It is to be noticed that Dr. D. and his brother were the only dark complexioned members of their family, all the rest being fair. Neither of them had suffered from any special nervous phenomena, but Dr. D. himself used this expression to me: "I dare not drink wine, on account of the gout; if I were to take a few glasses, I should be sure to have an attack of numbness in my hands."

Dr. Langdon Down also mentioned to me the particulars of a patient of his, Lady ——, aged about 60, who had patches of Xanthelasma over each eye. She had for many years been liable to terrible headaches, and of late had suffered from attacks of "epileptiform abstraction," during which she would forget what was going on about her, and what she had just done. Her headaches were described as paralysing. Two years ago she had experienced an attack of epilepsy.

Xanthelasma in association with almost life-long history of severe dyspeptic and nervous troubles.

The following notes were written out more than twenty years ago:—

Mr. E. G——, aged 60, is a dark-complexioned, fresh-coloured man, with patches of Xanthelasma on the lower lid of each eye, near the inner canthus. His case is of great interest, because he has suffered since the age of twenty-four from a variety of very troublesome and severe nervous symptoms and gastro-intestinal troubles. He has at length found a dietary, by strict adherence to which he can keep off his sickness, headache, &c., but any indiscretion is still severely punished. Mr. G. wrote

out for me a very full account of the history of his complaints, the substance of which is given below.

At the age of 24 he was first attacked, while out walking, with severe pain in the pit of the stomach, which lasted a few hours, and got well after the use of hot fomentations. A year later he had a similar but more severe attack, which lasted two or three days, and during which his urine "was like brown stout," and was said by his medical man to be "very acid and full of lithates." From a few months after the first seizure he began to suffer much trouble with his food, and he mentions tea, coffee, beer, wine, eggs, salt meat, and rich soup as articles any one of which would bring on an attack of the abdominal pain. He has been obliged from that time to abstain from them all. Ten years later he was ill for twelve months with "dysentery," passing "blood and matter." This illness reduced his strength greatly, and he lost three stones in weight (reduced from ten to seven stones). He was told by his doctor that the alimentary canal was ulcerated. He has since then been able to keep off these attacks only by the strictest attention both to the kind and quantity of his food. He now eats nothing but lean mutton and beef, stale bread and butter, a small quantity of potatoes, and occasionally rice pudding; he drinks nothing but cold water. He eats no supper. Living in this exceedingly abstemious way, he often, when fatigued or exhausted, feels very faint and in need of a glass of wine; and if he gets over-tired for two or three days in succession, he gets an attack of his epigastric pain, with great flatulence and nausea, and intense headache. He says that in these attacks the pit of the stomach becomes so tender that he cannot bear the clothes to touch him. He gets almost immediate relief by free vomiting, induced by drinking warm water. During the headache he is "nearly blind for the time," and the sight remains dim for a time after it has passed off.

In addition to the above very curious and distressing symptoms, he has also complete paralysis of accommodation in the left eye.

Mr. G. has been accustomed to broken rest for more than thirty-five years, and during the same time has passed much time "in the foul atmosphere of a distillery, breathing carbonic acid gas and fumes of spirits and fusel oil"; and is it fair to remark that these conditions of life began at about the time when he first became subject to the attacks of abdominal pain, &c. Mr. G. lives in a warm, damp climate near the sea-coast in Devonshire.

Severe jaundice, with extreme enlargement of the Liver: perfect recovery, and return of the Liver to its normal size. Subsequent formation of incipient Xanthelasma spots on the right eyelids. History of headaches and dyspeptic troubles.

I give the following notes of a remarkable case just as they were written out many years ago:—

The following case will scarcely make its full impression unless I relate the circumstances which brought it under my notice. In connection with my enquiries as to Xanthoma and liver disorders, I asked my colleague, Dr. Andrew Clark, if he was familiar with a condition of very great enlargement of the liver from which recovery might occur. He said at once that the most remarkable instance of this which he remembered occurred in the person of one of the hospital nurses, who four years ago was under his care for severe jaundice, with a liver which "nearly filled her abdomen," and who afterwards got quite well. He kindly gave me the patient's address, and I subsequently saw her. She was a thin woman, of about 48 years of age, and prior to her illness had been for twenty-five years a nurse in the hospital. In the Xanthelasma position on the right side are a number of white spots, chiefly milium, but around one of them there are some pale deposits. Their positions make it, I think, extremely probable that they are due to the same causes as Xanthelasma, and are really of the same nature; she has no such spots elsewhere. Although the xanthelasmic changes in this woman are as yet exceedingly slight, I think that they are of importance when taken in connection with the fact that she suffered several years ago from a severe attack of jaundice, during which her liver became enormously enlarged for a short time, and afterwards regained its proper bulk.

Four years ago (at the age of about 44), she was under Dr. Andrew Clark's care for a severe attack of jaundice, which lasted four or five months. The jaundice was of the ordinary yellow colour, but attended by extreme darkness around the eyes. During the attack her liver enlarged prodigiously, so that, as Dr. Clark says, it nearly filled the abdomen. She recovered perfectly, and has now no trace of jaundice.

She has been liable to headaches all her life, but not of any unusual severity; she says that they were attended rather by swimming in the head and inability to see well, than by extreme pain. Latterly she has suffered from cold feet. She has always been obliged to be very careful about her food. Menstruation has been regular until within the last

few years. Through life she has been prone to display a dark areola about the eyes when ill.

*Symmetrical Xanthelasma in a lady of middle age, who had all her life suffered severely from headaches and various forms of Liver disturbance. Great susceptibility to drugs, &c.**

It is perhaps scarcely needful to make the remark that the liver must not be regarded as a part of the system which can be isolated. It is in its turn under the influence of nerves, and is in close organic sympathy with other organs. More especially during the period between puberty and the grand climacteric it is in very close relation with the sexual system. This latter exercises a most powerful influence upon the circulation, and through it, and possibly in more direct ways, also upon the activity of the liver. It is in many patients difficult to distinguish the results of disturbance of one or the other of these important systems, and very often those results are inextricably intermingled. In a large majority of these, however, the liver stands as a most important link in the chain of causation, and it is only through disturbance of its functions that the symptoms of which we have to judge are brought into existence. Whilst freely admitting that we must take the whole body into our consideration, the foremost importance of this viscus may yet be reasserted.

In illustration of this subject we may suitably, in rough detail, study the case of Mrs. P——. This lady's chief objective symptom was the possession of large patches of Xanthelasma palpebrarum of the ordinary wash-leather type, curving round her inner canthi in the usual fashion. She was married, of great energy of character, and was very clear in her descriptions. She was 52 years of age, and rather stout, but scarcely looked her age. Respecting her family, she stated that her relatives "suffered dreadfully from their livers, and consequently from their nerves." Her mother and a maternal uncle had symptoms just like her own, and two uncles had passed gall-stones. She was not aware, however, that any had ever had actual jaundice, nor had she herself, though she had been near it. She did not marry until rather late in life, and had borne no children. In girlhood there had been a suspicion of chest disease, but it passed off. She had never under any circumstances been liable to catch cold. There was gout in her family, and she had herself had joint pains.

A chief trouble of her life had been the liability to headaches, and of these she counted six different forms. It may be sufficient, however, to particularise two—"the nervous headache" and "the sick headache." The former, she said, is often curable by tea, but the latter is made worse. "If I take tea when I have a real bilious headache, it makes me more sick, and does nothing to relieve the pain in the head. These headaches are overpowering, and there is nothing for it but to go to bed, have the room darkened, and lie perfectly still." She had tried antipyrine and other remedies of that class, but with no great encouragement. "My only real friend is a purgative." To tonics and all forms of stimulants she was extremely susceptible. "The smallest dose of quinine," she said, "will give me a splitting headache and buzzing in the ears." Wine also always gave headache, but she could sometimes take a little whisky at bed-time with seeming advantage.

Mrs. P——, who was sent to me by Dr. Gooding, of Cheltenham, came not on account of her headaches, but for two forms of skin disease. She had for fourteen or fifteen years been the subject of psoriasis of the usual type, and affecting her finger-nails. She had also been liable to very peculiar recurring attacks of erysipelas-eczema of the face. The first of these occurred at the age of ten, and the second at sixteen, and both were then called "erysipelas." Both these were of short duration, and subsided completely. After them no attacks occurred until the year 1897, and from that time until the date of my consultation in July, 1899, there had been three. Two of these, with precisely a year's interval, occurred on May 19th. The attacks began, as she described them, by streaks and patches of redness on the face, which were soon followed by swelling which almost closed the eyes. At the same time the hands also would swell, but not higher than the wrists, and the feet also to a slight degree. The skin of the face sometimes vesicated. The attacks were always of short duration, and, when they subsided, passed off completely.*

For the benefit of her psoriasis I prescribed small doses of arsenic—a single minim of Fowler's solution—with three of the tincture of nux vomica. These she continued some weeks, and her nails rapidly improved, as also the psoriasis patches. She suffered, however, from severe headaches, with buzzing in her ears, and was persuaded by a surgeon, whom she consulted at Harrogate, to leave off the mixture. The result was a mitigation of her headaches, but a relapse of her psoriasis. It

* Taken from 'Archives,' vol. xi., January, 1900.

* It has occurred to me that these attacks may possibly have been due to arsenic, as that drug had often been prescribed for her psoriasis.

appeared that not only was her nervous system very susceptible to the drug, but her psoriasis also. I had also advised her to take calomel in three-grain doses at bed-time occasionally for her headaches, each dose to be followed by an aperient. She reported that the effect of this was a day of perfect freedom from distress, invariably followed by one of increased headache of a different form.

It is needless to say that Mrs. P—— had been under many doctors. Several of them, Sir William Jenner amongst the rest, had taken great interest in her case, but her extreme susceptibility to all drugs has disappointed every one. It had been observed that her urine often deposited white phosphates when a headache was threatened, and at other times was clouded with lithates.

There is a peculiar form of pigmentation of the eyelids in which both the upper and lower lid become almost black, the pigmentation being diffused and not in patches. It begins, I believe, usually in early life, and is slowly progressive, becoming really conspicuous chiefly in later years. I have seen several examples of this, perhaps many in minor degrees, for it is an affection which can be recognised as a disease only when exaggerated.

Deep pigmentation around the eyes in association with severe and long-continued bilious attacks. Cataracts.

A Mrs. P——, a tall, thin, somewhat gaunt lady, had become the subject of peripheral cataract at the early age of 37. She gave me some interesting facts as regards the history of her health. At the age of 9 she suffered from diphtheria, after which she had paralysis of the palate and loss of accommodation. From the age of 13 to 20 she had very severe sick headaches regularly every week. Subsequently she was strong enough to go out as nurse in one of the London hospitals, from which she married. In spite of her bearing children, she remained liable to severe bilious attacks. These would begin with hemiopia, during which she lost the sight of objects to her left. She would also see zigzags, fortification lines, &c. These symptoms were always introductory to a very severe headache. For long she had been liable to have her left hand die and become white; the other hand never being affected. She was accustomed to put her hand into hot water to relieve this condition. Of late this symptom had a little changed in character, for, although the hand would become pale and numb, it did not lose its colour.

Mrs. P. had become deeply pigmented around her eyes. There can be little doubt that the severe attacks of nerve disturbance from which she had suffered had not been without their effect in predisposing to the premature changes in her lenses. I may venture to remark that her case is just one which would in early life have probably been very much relieved by a year's course of mercurial treatment.

January, 1889.

Case illustrating the relationship of abruptly limited pigmentation of the eyelids to Xanthoma.

A surgeon who consulted me for another matter attracted my attention to his face by the peculiar limitation of discoloration of his eyelids. Extending from each inner canthus downwards, and outwards to the outer one, was an area of deep brown discoloration, the lower edge of which was over the border of the cheek-bone. Below this edge—which was as abrupt as possible—the skin was quite pale. Near the inner canthus the skin was almost black.

"Have you been bilious?" I asked. "If you mean by that, have I been sick to vomit, No, never; but I have been liable to headaches when tired, and when I have headaches the darkness of my lower eyelids is always increased. They are darker now than usual because I have been put out of sorts by coming up to London, and have had a bad night." "Then you had yourself noticed the discoloration?" "Oh, yes, and friends frequently tell me of it. It is a family matter, and several of my brothers and sisters have their eyelids almost as dark as mine." "Have any of them got Xanthelasma palpebrarum?" "No; but my mother had it, and she had also passed biliary calculi, and had once had jaundice."

It will be seen that this case supports the belief that physiological and variable pigmentation of the eyelids belongs to the same category of symptoms as Xanthoma itself. Both depend upon the united influence of the blood condition, of defective bile elimination, and the nervous disturbance resulting from liver attacks. It also implies, what is probably well recognised, that many bilious persons never get sick headaches, but suffer only from very minor forms of recurring nerve disturbance.

The case may be suitably compared with those of Dr. Langdon Down and his brother, given at p. 17.

Xanthoma palpebrarum occurring in association with a peculiar form of neoplasm.

The Clinical Museum possesses two original life-size portraits which illustrate a form of disease of the skin of the face hitherto undescribed, and which somewhat simulates rodent ulcer. In both, the

disease was in association with Xanthelasma. These portraits cannot as yet be published, as the patients are living. They will probably be given in a future fasciculus. The following are the notes respecting one of them.

Mr. W—— was brought to me by Dr. M——, of St. C——, as a case of much difficulty in reference to the diagnosis of rodent ulcer, and such indeed it proved. Our patient was aged 71, but looked ten years younger, being a stout man of erect gait who still kept some black hair. He had always enjoyed good health and said that he had only had one headache in his life. This statement was of some importance because he was the subject of Xanthelasma palpebrarum in its ordinary form of yellow wash-leather patches curving round the inner canthus on each side. He did not consider that he had ever been a bilious subject. He had, however, suffered from gout. His father had done so yet more severely than himself. A near relative had died of consumption. On his left temple he had for some years had a blue-black little growth as big as a cherry-stone, the senile form of melanosis of the skin. Hairs grew on this patch, and although it had increased in size it showed as yet no malignant proclivities. The condition for which the consultation was sought may be described as follows:—

On the right side of the bridge of the nose, and passing outwards towards the canthus, was a patch the size of a shilling, but not so round, which was elevated the eighth of an inch above the surrounding skin, and everywhere abruptly margined. Its surface was level and quite sound, showing only a little desquamation in its centre. This patch was of a dusky-red tint, and, although moderately firm, was not hard. It implicated the whole thickness of the skin, and shelved off slightly at its edges. There was not the slightest approach to the hard rolled border which characterises rodent; on the contrary, it was rather thicker in the middle than at its edges, and nowhere really indurated. The history was that it had been first noticed about a year and three months ago, and had been supposed to be caused by the pressure of his pince-nez. It had been slowly increasing ever since, but had never been in the least sore. Mr. W—— had long been the subject of acne tuberosa of the end of the nose, and on the left side of the nose there was an ill-defined patch of thickened and congested skin. With this exception he had no other affection of the skin.

This case is an exception to rule, in that the patient had not recognised any definite tendency to bilious disturbance. I have met with a few others in which similar statements were made. Very probably they are instances of inherited proclivity, and would, if the whole family history could be obtained, prove much less exceptional than they look.

A case illustrating the comedonous type of Xanthelasma palpebrarum.

In the case of Colonel S——, some comedonous patches simulated Xanthoma so completely that at first sight I took them for the ordinary form. There were two on each side, placed as usual above and below the inner canthus, and they were of a lemon-yellow tint, without any trace of a comedonous plug. On looking at them carefully, however, and especially on touching them, I felt sure that they consisted really of sebaceous accumulations. Each patch was made up of several spots, which touched at their edges, but did not actually coalesce. These were distinctly hard, and had a thickness of an eighth of an inch. Although looking like the chamois-leather patch, they were both harder and thicker. Near to the principal patches were some single isolated spots of the same character. Some of them had an indistinct depression in the centre, but none showed any approach to the formation of a comedo. They bore, I believe, the same relation to comedones that the spots of milium do; that is, they were retention-accumulations of sebum, but in glands which had no external outlet. It was their position and arrangement which proved their alliance with Xanthoma. To this it may be added that their colour, seen through the epidermis, was distinctly yellow. It would have clenched the diagnosis to have snipped one of them out for examination, but to this my patient was disinclined. The history of liver disorder was not very strong. Colonel S—— was the subject of rheumatic gout, and in early life he had suffered much from headaches, but he had never been jaundiced.

I may add to this narrative that in several cases I have seen the ordinary chamois-leather form of Xanthoma coincident with these sebaceous accumulations, but never to any great extent. If the tendency is to one of the forms of the disease, there is not usually any free development of the other.

Pigmented patches on the eyelids in the Xanthelasma positions. History of violent attacks of migraine.

Mr. B——, whom I saw in February, 1887, had on the upper and lower eyelids coal-black patches of pigment arranged like Xanthelasma, but more abundant on the right than on the left side. He was subject to violent headaches, always attended by the phenomena of migraine, *e.g.* dim vision, &c. He often had temporary loss of speech, and sometimes numbness of one or other lower limb. His mother had had similar attacks.—*February 21st*, 1887.

Pigmentation of eyelids with Xanthelasma. Tendency to Xerostomia. History of jaundice in youth, and liability to sick headaches.

Mrs. W——, 56; four children; youngest 18. I saw her some six or seven years ago for rheumatism. She is liable to become dark around her eyelids; and now, on the left side, has almost black stains, and a single patch of Xanthelasma. She complains of dryness of the tongue. She is liable to flush, and "to get perspirations and heats." She says that her eyelids puff a little when they are darkest. Her husband noticed the other day how black her eyelids were. She has a tendency to dry mouth. It is dry now, but she describes it as much worse at night. She is of a bilious family. Has suffered from piles; and had an attack of jaundice when a girl. In the night her body perspires, and her mouth gets dry.—*November 4th, 1890.*

February, 1891.—Reported to be very much better under treatment by mercury in small doses.

Xanthelasmic patch on one lower eyelid. History of dyspepsia and very severe sick headaches. Inability to digest beef.

On July 23rd, 1869, I saw Mr. A——, in consultation with the late Dr. Stone, of Christ's Hospital. Our conference was in respect to another malady, but in the course of it I observed that our patient had a Xanthoma patch on the left lower eyelid. It was a small patch, not more than half an inch long and a quarter broad, but it was perfectly characteristic. It was smooth, soft, and but slightly elevated. I enquired as to sick headaches, and he told me that he had through life suffered dreadfully. The headaches had been both frequent and severe. Dr. Stone confirmed this statement, and said that he had often attended him for them. Of late years the headaches had been much less frequent, and our patient referred his comparative exemption to the influence of a large serpiginous ulcer which had formed in one arm. He still, however, suffered occasionally, and was liable also to severe fits of indigestion. Amongst other things, he mentioned that he could not eat beef without having an attack of dyspepsia and headache. He was a stout man, aged 50, of dark complexion, and rather sallow. He had never been jaundiced. During his indigestion attacks, "swimming before the eyes" was usually a marked symptom, but he had never had any other indication of special derangement of the nervous system.

The xanthoma, in this case, was as yet unsymmetrical, and on the lower eyelid only. It was in the usual position near to the inner canthus.

It is possible that the improvement, as regards headaches, which had been observed, had been induced not by the sore on the arm, but by a long course of iodide of potassium and mercury employed for its cure.

Xanthelasma at an early age, and almost confined to the left side. Bad sick headaches. History of sick headaches in the patient's father.

Mrs. ——, aged 33, was of very dark complexion and bilious aspect. She was sent to me by Mr. Sturges on account of abscesses in the cellular tissue of the orbit, and I then noticed that she had some thin and superficial patches of Xanthelasma in the upper and lower lids of the left eye near to the inner canthus; they were of considerable size. On the corresponding parts of the right side there were some very slight yellow marks. She stated that she was liable to headaches accompanied by nausea, but not such as to produce vomiting. The headache began in the forehead, and afterwards fixed itself in the occiput; the pain was sometimes prolonged and fearfully severe. Her mother had suffered much from sick headaches all her life.

Premature cessation of menstruation. Liability to attacks of numbness in the hands, followed by sick headache.

The following was the history given by a patient who was the subject of the ordinary form of Xanthelasma of the eyelids:—

Miss —— was a florid, healthy-looking woman of 46. She was of active habits, and had never suffered, as far as she knew, from liver disease. She had ceased to menstruate at the early age of 25, and had never since had any menstrual discharge whatever. She had not since been liable to any disturbance at her monthly periods, and the only symptoms which could be supposed to have had connection with her ovaries or liver were the following:—For many years past she had been liable to occasional attacks of numbness, during which her hands became useless, because she could not feel anything in them. After lasting about an hour this numbness would pass off, to be followed by a short sick headache, not usually lasting longer than an hour, and in its turn followed by abnormal hunger. She spoke very definitely about these "numb-attacks," and mentioned them repeatedly. They are of interest to us in relation to the sudden losses of vision experienced in many other cases. The attacks did not occur regularly once a month, indeed not oftener than two or three times a year; but they were always severe enough to require that she should lie down for a time. During the last

twenty years her hair on the vertex of the head has been falling, and she is now bald in the middle region from forehead to occiput.

Xanthelasma of eyelids, with striæ in the palms, also at bends of elbows. Jaundice persisting for eight years.

The following letter, which I received many years ago from a well-known surgeon, will be read with interest:—

7, Great Charles Street, Birmingham,
September 10th, 1876.

My dear Sir,

I had such a singularly interesting case at the Hospital for Women yesterday from Coventry, that I venture to write you about it. I know you will be pleased with it, and perhaps you can help me to work it up.

Eight years ago a young woman, just menstruating, got very wet, shivered, and fevered, ceased mens. suddenly, and had a long illness, from what her attendant called inflammation of the bowels. After that she jaundiced, and had "an abscess on the liver." She has been deeply jaundiced ever since, and has never menstruated. The fundus uteri is large, heavy, and somewhat fixed; ovaries can be felt and seem normal. Hepatic dullness five inches, and liver tender. Occupying the hollow above the inner canthus of each eye, and traversing round two-thirds of both upper and lower lids, is a most beautifully pronounced patch of Xanthelasma. The patches are *absolutely* symmetrical. Between the fingers and on each side of each finger are guttations of the Xanthelasma, and each line of the palm of the hand is bordered with a stripe, or rather the stripe has the line in the middle of it. In the flexures of the elbows are similar lines, and all these are almost absolutely symmetrical! What can you tell me about this?—Yours truly,

Lawson Tait.

P.S.—Was the hepatic condition due to a thrombus from the uterus?

The reply which I made to Mr. Tait was that it seemed probable that his patient was suffering from obstruction of the common duct, very probably caused by gall-stone. The history given does not enable us to date the occurrence of the Xanthelasma. It may have occurred, and very probably did so, in connection with attacks of liver disturbance long prior to the development of jaundice. To the latter we must probably attribute the striated Xanthoma of the palms.

The preceding case-narratives illustrate phenomena, many of which are by no means rare. It has been thought worth while to give them place here since they enable us to more nearly complete the picture of the clinical relationships of the maladies under consideration. They show us the influence of recurring attacks of liver disturbance in producing various changes in the state of the eyelids — 1st, pigmentation more or less persisting but prone to temporary increase in those parts of the lids now known as the "Xanthelasma positions"; 2nd, the development of grouped comedones in these positions; and 3rd, the formation of the patches of yellow fatty deposit which constitute Xanthelasma in its typical form. Illustrations of these various conditions will be given in a future Fasciculus.

CASES OCCURRING IN CHILDREN.

Certain facts would suggest that the so-called juvenile cases may, in some instances, be the sequelæ of infantile jaundice. This disease, as is well known, often occurs in several children in succession.

In reference to this, an important observation has been recorded by Dr. Lehzen and Dr. Knauss (Mozling).* They deal with the cases of two sisters, aged respectively eleven and nine. The elder had passed through jaundice shortly after birth, and at the age of four had Xanthelasma patches *on both eyelids*. A year later she had patches on knees, elbows, hands, gluteal regions, and heels. The left heel preceded the right by one year. There were no subjective symptoms. The girl died of heart failure whilst under observation, and a great number of xanthomatous nodules were found about the heart and great vessels.

The younger sister had a similar state of skin, but no heart disease. Her skin disease had begun in her third year.

Xanthoma juvenile.

It would appear indeed that, putting aside the cases of inherited Xanthelasma, there are two somewhat distinct types of the Xanthoma juvenile. In the one the eruption resembles that which occurs in diabetes and allied conditions, whilst in the other the locations are somewhat different, the elbows, knees, and heels being the parts affected, and there is no general eruption. It may be conjectured that in the one form the inheritance is from some diabetic progenitor, whilst in the other the germ-material may have been derived from the more common xanthelasmic or icteric form. The two, however, must not be too widely differentiated, for they have much in common. In neither of these does there appear to be any special tendency to aggressive changes excepting a very remarkable overgrowth, in certain instances, of the local patches. The patches never increase in number, and the general health does not suffer. The majority of the cases upon record illustrating the juvenile or congenital form of Xanthoma are examples of the disease in young children, and without any subsequent record of progress. It happens, however, very fortunately that other records of the disease in adults enable us to complete the picture. Dr. Stephen Mackenzie has recorded in the 'Pathological Transactions' for 1882 cases of two brothers and a sister who were all affected by a form which most nearly resembles that of diabetes. They were all past middle age, and in all three was a history of its having been been present from the earliest childhood.

The final result in the second group of cases in which tuberous growths are developed on the elbows and knees is well illustrated in some remarkable photographs preserved in Paris at the Hôpital St. Louis. These are reproduced in Plates I, J, K, and L in the present fasciculus. Dr. Mackenzie's cases, together with others by Mr. James Startin, were the subject of careful investigation by a Committee of the Pathological Society, and it seems worth while to reproduce here the full details.

A very important (because extending over twenty years) case of the juvenile form is given by Dr. Colcott Fox.* The first papules were observed when the child was little more than a year old, and were near the anus. At the age of ten she had nettle-rash, and at fifteen swellings appeared about the hands.

* See 'Archiv für Path. Anatom. und Phys.,' 1869.

* See 'Lancet,' Nov. 8th, 1879.

At seventeen "a tuberose xanthelasmic patch as big as a florin appeared on each great toe," and subsequently patches showed themselves in the webs between the fingers; and later still tuberose patches on each elbow. There were no patches in the palms, or soles, or on the eyelids. The girl had never suffered from jaundice. There was much gout in the family, and several of its members had died of cancer. Some of the patches were excised at the patient's wish, as they caused disfigurement. The characteristic conditions of Xanthelasma were disclosed. The tendency to the production of new patches appeared to have ceased.

Dr. Thebierge showed at the Paris Society of Dermatology two young brothers who had typical xanthomatous tumours on elbows and buttocks. No facts as to family history could be obtained.

Dr. Blaschko presented to the Berlin Medical Society in 1894 a most important case. The patient was a child not four years old, in whom nodules of Xanthoma had recently developed. They occurred first in the ear, and had invaded the axilla, back, palm of hand, sole of foot, groins, and pharynx. The nodules varied from a pin-head to a pea, and were yellowish in colour. They were symmetrical, but for some months at first there had been only one (near ear?).

In Sir Thomas Barlow's case, in a boy of seven, the eyelids were affected. He had no obvious signs of liver disease, but had suffered from renal calculus.*

FACTS ILLUSTRATING HEREDITARY TRANSMISSION.

The three following cases are from my own note-books:—

In the case of a lady, aged 64, who had very large patches on her eyelids which had been present thirty years, three or four of her children were reported to show the same. She had suffered much from sick headaches, and had twice been threatened with jaundice. ('Archives,' vol. v. p. 275).

Mr. H.——, at the age of 50, had the usual form of Xanthoma palpebrarum. He stated that his mother also had had them. ('Archives,' vol. ix. p. 92.)

Mr. William K——, aged 50, who came to me in June, 1884, with a rodent ulcer on the side of the nose, had a patch of Xanthelasma on the left upper eyelid. He had often been nearly jaundiced, but did not know of any special liability to liver affections among his relatives. His mother, a brother, and a sister were also the subjects of Xanthelasma, and his brother had had the patches excised.—*June 10th*, 1884.

The following notes by Dr. Stephen Mackenzie refers to an important group of cases published by him in the 'Pathological Transactions' for 1882:—

June 19th, 1882.

My dear Mr. Hutchinson,

I think there is no doubt whatever that the grandfather (paternal, I believe) of my Xanthelasma cases suffered from the same disease, and probably with somewhat similar arrangement. There is strong circumstantial evidence of this. The grandfather was a "top sawyer," and my patient Samuel worked *under* him in the saw-pit. He says his grandfather used to work with his shirt widely opened, and the eruption in the neck was very distinct. This is confirmed quite independently by his sister.—Very truly yours,

Stephen Mackenzie.

Dr. Nevins Hyde, of Chicago, has described an interesting case which occurred in a young Jew, aged 20. He was apparently in good health, and had never suffered from jaundice. His mother, who was seen by Dr. Hyde, had small patches of Xanthelasma near to the inner canthus of each eye. There was no history of the affection in other relatives. In the patient the disorder was said to have commenced in his tenth year, and to have first shown itself as yellowish points on the extremities and near the inner canthi of the eyelids.

In all positions the lesions had continued steadily to increase.

The lesions on the eyelids at the time of

* See Pathological Soc. 'Transactions.'

inspection were symmetrical, but only of small size. Dr. Hyde described them as "split-pea-sized xanthomatous nodules." The lesions of the skin were distributed with fair symmetry, and occurred on the knees, elbows, and backs of hands. Everywhere they were more or less tuberous. They were few in number, but those on the elbows especially were large. There were no striæ in the palms.

See 'American Journal of Cutaneous Diseases,' vol. v., for September, 1887, p. 329.

The cases which occur in children, or if not in actual childhood, at any rate seemingly by inheritance, are, as has been already hinted, of great interest in reference to the laws of hereditary transmission.

We may, in the first place, suppose that the offspring inherits from the parent a proneness to disorders of the liver, and that the production of Xanthelasma-patches on the eyelids is in the case of offspring as much secondary to hepatic disturbance as it was in the parent. In favour of this view is the fact that in most examples of Xanthelasma of the eyelids in several members of the same family the production of the patches is usually delayed until adult life. Against this is, sometimes, the statement of those who in the second generation show them, that they have been quite free from symptoms of bilious disorder.

We have next the suggestion that under the law of pangenesis the structures of the eyelids in offspring are constituted with precisely the same liabilities which those of the parent possessed. Thus, without any liver disturbance or blood disorder, the skin of these special regions tends to undergo changes of the same kind as those which had been manifested in the parent.

A third suggestion is that a xanthelasmic parent may transmit to offspring germ-material from the morbid patch capable of generating its like. This would bring the process into line with what we suppose to occur in at any rate some of the instances of the hereditary transmission of cancer and new growths. There are many reasons for believing that both in Xanthelasma and Xanthoma the new material may possess infective qualities. The patches of the former almost always advance at their borders, and in the eruptive form of Xanthoma it is impossible not to believe that infective germs are distributed by the blood. Now some of the examples of these affections in young children would appear to require both these two latter hypotheses for their explanation. They deviate a good deal from all the types of the malady met with in adults. In Sir Thomas Barlow's case, a child had Xanthelasma patches on the eyelids, but they were not in quite the usual positions, and there were others on the upper arm near the vaccination scars, a position very unusual in adults. In the case described as No. 9 on page 34, the child had patches on the eyelids, but some others which were scattered irregularly on the back. Nor did the patches reproduce exactly those of either Xanthelasma or Xanthoma. Similar remarks apply to Dr. Barr's case, and also to a case which has come under observation whilst these pages were passing through the press, in which a girl whose eruption began in infancy shows symmetrically grouped spots on the cheeks much like Adenoma sebaceum, but arranged on the eyelids just like those of Xanthelasma. In all these cases the suggestion that some infective material was taken over by the child offers the most plausible explanation of the phenomena. This group of cases is of great interest, and must receive further investigation. It is not to be expected, in diseases so easily overlooked as Xanthelasma of the eyelids, and so transitory as Xanthoma diabeticorum, that the history of the affection in progenitors will often be known to the patient, or even to the patient's parents. Atavism is probably of frequent occurrence, and we can expect but seldom to find evidence of inheritance other than that which the existence of the disease itself implies. In a few cases, however, such history has been forthcoming.

The following case, taken from 'Archives of Surgery' for January, 1892, is of much interest in this association :—

Nodular thickening on hands, elbows, heel, &c. Inherited gout. Alliance with Xanthelasma. History of jaundice in several relatives.

Miss U——, aged 18, had not suffered from any particular disease except quinsy. Eighteen months ago patches were observed on her elbows. Her hands soon afterwards became affected with little indurations in the skin. She also had patches in the psoriasis positions on the fronts of the knees. A lump also formed on one heel. Thus far the elbows, hands, knees, and one heel have been the only parts affected. She is one of twelve, all living; *two have suffered from infantile jaundice.*

The family history is of strong inheritance of gout, and of torpid livers. Many members of the family have suffered from the latter, and her paternal grandfather died of gall-stones, *having suffered from jaundice.*

Present condition.—On the elbows and knees there are groups of ill-defined papules on congested skin. On one knee there is little more than a patch of congestion, the tubercles being very ill-marked. On the heel there is only a patch of inflamed and thickened skin. It is just over the the attachment of the tendo-Achillis. The hands present conditions which are almost symmetrical; lumpy and nodular thickenings are seen in the skin of all the fingers. Some of these lumps are quite isolated, glossy, and semi-transparent, but others are more deeply placed and less defined. In both hands the ring finger has almost wholly escaped. The symmetry is not, however, exact, for in the left hand the middle, ring, and little fingers have almost all wholly escaped.

In the right hand the little finger is severely affected. The right thumb, middle and index fingers, and left index finger are those most affected, and in these the cutaneous nodules are so numerous that they are almost confluent. None of the nails are in the least affected. In each hand, a patch passing up from the base of the palm to the index finger is very conspicuous. In the left hand, on the ulnar border just above the wrist, is a large thick induration which has no representative in the other. There is no yellow Xanthelasma-deposit in connection with any of the growths. With the exception that this feature is absent, they much resemble what is seen in tuberous Xanthelasma.

Miss U—— says that her hands frequently burn and smart. She has recently been advised to take port wine, and says that it distinctly makes the lumps worse. She is a tall, well-grown girl, but pale and of a somewhat feeble circulation. Her case is evidently a partnership of tendencies to gout and Xanthelasma, with possibly a tendency to psoriasis also. The nodules are in the positions, in part at least, which are affected by psoriasis and also by Xantheloma. The severity with which her fingers have suffered must probably be attributed to her feeble circulation.

CASE-NARRATIVES

ILLUSTRATING XANTHOMA OCCURRING AS A GENERAL ERUPTION, AND OFTEN ATTENDED BY DIABETES.

Xanthoma diabeticorum.

Cases of Xanthoma in association with Diabetes, recorded by Dr. Addison and Dr. Bristowe (the earliest cases of the kind).

Dr. Addison recorded, under the name "Vitiligoidea tuberosa," the case of a man, aged 27, a tailor, who was under Dr. Hughes's care in Guy's Hospital for diabetes. He was treated for diabetes for about six months, when he became suddenly the subject of an eruption "of a lichenous character." In the course of ten days it had extended over his arms, legs, and trunk, and also over the face and scalp. The tubercles were entirely absent at the flexures of the joints, and were most numerous about the elbows and knees. They were of a yellowish colour, mottled with a deepish rose tint, and with small capillary veins here and there ramifying over them. Dr. Addison says that they were not unlike the "ordinary molluscum," and many of them had in the middle a whitish nodule. On incision no fluid could be obtained. The eruption remained out three months, and then began to subside, and the patient was lost sight of. Many of the tubercles had entirely disappeared, and left no change in the skin.

Dr. Bristowe recorded, in the 17th volume of the 'Pathological Transactions,' a case precisely like this. As in Dr. Hughes's case, the patient was a tailor, and the subject of diabetes. He was 43 years of age. Parts of the hands, wrists, feet, ankles, elbows, knees, and buttocks were affected; the rest of the skin, including the face, was free. The eruption had been out four years and a half before Dr. Bristowe saw the man, and during six months under Dr. Bristowe's observation it scarcely altered. Dr. Bristowe found that he was the subject of diabetes, of which disease, however, none of the general symptoms were present. It was uncertain how long the diabetes had been present, but the increase in quantity of urine was only of a few months' duration. During the last three months of the period included in Dr. Bristowe's narrative of the case the eruption underwent great improvement.

Dr. Murchison, who in his work on the liver mentions these two cases, makes the important suggestion that, since the liver is probably concerned in the production of diabetes, this eruption may be, like the other forms of Xanthelasma, of hepatic origin.

An important advance in our knowledge of this form of Xanthoma followed on the production by Mr. Malcolm Morris before the Pathological Society in 1882 of an example of. Mr. Morris's case was not only ably recorded and investigated by him, but it was the subject of a Committee Report and of considerable debate. Although some of the opinions expressed have been since modified or superseded by the further accumulation of facts, yet the case and the reports on it are of such interest that it seems worth while to reprint them in full in the present place.

Mr. Morris's more advanced opinions on this subject—one with which his name is honourably connected—will be found in an able paper published conjointly with Dr. J. J. Clarke in 1892, and from which some extracts will be found further on.

A case of so-called Xanthoma tuberosum.
(By Malcolm Morris.)

(From the 'Transactions of the Pathological Society,' vol. xxxiv.)

Mr. T. S——, aged 48, has been a master builder for fifteen years, and previously to this a stonemason. During all his life he has been much exposed to the vicissitudes of the weather, especially when engaged as a foreman during the building of one of the Thames bridges some twenty-six years ago. Has been married twenty-five years, but his wife has never been pregnant. He has always had a sufficient quantity of good food, and now drinks about a quart of mild ale a day, with an occasional glass of spirits and water at night; but he has never been what may be called an excessive drinker. He has lived in London for twenty-seven years, in his present house four years, and in the one previous sixteen years, and both houses were dry and airy.

He is of medium height, but very stout, weighing as much as eighteen stone. Ten years ago he only weighed ten stone, the increase in weight beginning

after an accident (fractured patella) which occurred at that time. He seems of cheerful disposition, and his complexion is florid.

Family history.—Father, also a builder, died four years ago, at the age of 62, from decay of nature. He always enjoyed good health, with the exception of attacks of rheumatic gout. Was of thin stature. Mother died of dropsy at 61. Enjoyed good health. Father's brother, a farmer, enjoys good health; also his family. Knows of no other relation on father's side. Mother's brother, who is his wife's father, is alive and in good health. Of his mother's two other brothers and sister he knows nothing. The patient has no sisters; one brother died, he thinks, from apoplexy; another younger brother, a mason, enjoys good health, with the exception of severe sick headaches. Has eight children, all in good health.

Patient's history.— Has all his life suffered from severe headaches and occasional attacks of giddiness. The headaches have not been so severe of late years. As a young man he was a somnambulist, but on the whole enjoyed good health and strength. When a boy suffered from severe attacks of boils. Never had any form of fever, syphilis, or acute rheumatism. In addition to the accident before mentioned, he broke his left thigh about twenty-six years ago. Has suffered a good deal of dyspnœa on exertion, and palpitation of the heart during the last few years. The eruption suddenly commenced about two years ago on the outer side of the thighs and the extensor surface of the arms, gradually appearing on other parts of the limbs and body. During the last fortnight he says that some of the first swellings have disappeared.

Present state.—He says that now he only occasionally suffers from headaches; he sleeps badly, his sight is dim, and a mist sometimes appears before his eyes, preventing him from reading. Other senses are good. Tactile sensibility of feet normal, but there is anæsthesia of the skin of the heel, which is most marked on the inner surface. Knee-jerk and skin reflexes normal. Complains of sciatica in left side. Pulse 96, soft; heart weak, the sounds being most distinct at the base; no bruits; lungs decidedly emphysematous. Appetite is fair, but has a continual thirst; bowels regular; has never had jaundice. Liver and spleen normal. Passes a large quantity of urine, but is unable to feel the passage of it. It is pale, turbid, and contains sugar. States that he has lost all sexual desire for some weeks.

The eruption consists of small pink, round, or oval papules, and tubercles, varying in size from $\frac{1}{20}$ to $\frac{1}{4}$ of an inch in diameter, which are mostly discrete, but become confluent on the hands and about the knees. The larger tubercles are of a pale fawn colour in the centre, with a pink margin, and are only slightly raised above the level of the surrounding skin. The smaller papules are situated on the extensor surfaces of both arms, forearms, fronts of forearms, backs of thighs, buttocks, and on the back and shoulders. Some few are scattered on the front of the trunk, and some very minute ones may be seen between the fingers. In addition to those on the skin, some papules are to be seen on the tongue and on the mucous membrane of the mouth. There is no itching, but he complains of great tenderness, almost amounting to pain, if the skin of the hands is pressed; also a soreness of the skin generally. A small tumour was removed, with the patient's permission, for microscopical observation.

On the 19th of October I saw the patient again, and found that all the papules on both forearms, and many on the thighs and mouth, had entirely disappeared. The wound caused by removal of the tumour has healed, leaving a brownish scar, and no return of growth. He still complains of great giddiness, numbness of both feet, and soreness of the skin generally.

November 6th.—Only very few of the papules are left on the arms and thighs, and these are much smaller. Complains of soreness of the scalp and tenderness of the soles and balls of the great toes, but there is no real anæsthesia. Headache more severe. Has a sensation of numbness and soreness on the dorsum of both wrists and over metacarpals; also on the outer part of thighs, just above the knees, which is worse at night. These sensations radiate up to the buttocks and down to the calves. Skin dry and harsh, though he sweats on the slightest exertion. Passes a large quantity of water, which is pale, clear, and of acid reaction, sp. gr. 1030, and contains much sugar. There are several papules on the face, which have appeared about a week, but none on the scalp. The papules seen in the mouth on the last occasion are much smaller.

The small nodules, when incised and squeezed, gave out only a little blood; no pus or oily matter. An incision through a nodule proved it to be firm in texture.

Microscopical examination of nodule.—Sections of the small tumour stained with logwood and eosin show small nodules in the substance of the corium gradually merging into it, while the more recent nodules are composed of oval and fusiform cells lying in a slightly fibrillated connective-tissue matrix. The central parts stain less deeply than the margin, and have a granular appearance, in which the outline of cells and fibres can be faintly distinguished. The papillary layer and epidermis are unaffected. The developed nodules show no sign of having commenced

in connection with sebaceous or sweat-glands, hair-follicles, or blood-vessels; there are no blood-vessels to be seen in the growth. In the corium, but entirely separated from the nodules, are seen networks of dilated thin-walled vessels, around which are collections of round and oval cells. It is possible that these collections of cells represent the early stage of the growth, and, if so, an hypothesis might be suggested as to the subsequent history of it. As the cells become gradually organised into fibrous tissue, contraction would take place, reducing the size of the nodule, and compressing the vessels in the interior. In this way the absence of blood-supply would favour the degenerative changes in the centre of the nodule.

Remarks.—The names Xanthoma, Xanthelasma, and Vitiligoidea have all been used by authors to describe a peculiar disease of the skin. It is usual also to mention two varieties—Xanthoma planum and Xanthoma tuberosum. I have called my case, which I show to-night, by the latter name; not that I think it a good one, but because it is the most familiar. In many particulars, both clinical and microscopic, it seems to me to differ from what I may call true Xanthoma or Xanthelasma. I say "true Xanthoma," because the name is now always associated with a fairly common disease; whereas I think the case under consideration is an example of a very rare variety, as I can only find two recorded cases that in any way seem similar.

In his elaborate paper on Xanthelasma, published in the 'Medico-Chirurgical Transactions' for 1871, Mr. Hutchinson says that the disease to which the term "Vitiligoidea tuberosa" is chiefly applicable, having been twice noticed in association with diabetes, and having in both instances come out suddenly, presenting marked differences from ordinary Xanthelasma, and also showing a tendency to cure, is in all probability a distinct malady; and in another part of the paper he states that two at least of the cases published by Dr. Addison in his first paper are not examples of true Xanthelasma, and one of them probably belongs to a wholly different category, in which a very peculiar eruption occurs in connection with diabetes.

The three cases are so much alike, I think there is but little doubt that they are examples of one disease; but whether that disease is Xanthoma or Xanthelasma is a matter for consideration. At all events, there are several points in which they differ materially from true Xanthelasma. The points that link the cases together are:—

1. Diabetes.
2. The character of the eruption and its distribution (the eyelids being free).
3. The sudden appearance and the gradual disappearance of the eruption.

The points that distinguish the three cases from true Xanthelasma are:—

1. The diabetes.
2. The absence of the disease from the eyelids.
3. The gradual disappearance of the eruption.

As regards this third point, Mr. Hutchinson has given it as his opinion that the true xanthelasmic patches never disappear, but either remain stationary or gradually increase. Dr. Frank Smith and Dr. Wickham Legg have each reported a case in which the patches did get smaller; but still the fact remains that in the majority of the cases they are permanent.

It is of interest to note that all the three patients are of the male sex, whereas true Xanthelasma is much more common in women.

November 7th, 1882.

Report upon Mr Malcolm Morris's case of so-called Xanthoma in connection with diabetes.—The Committee have examined Mr. Malcolm Morris's case, and have nothing to add to his careful clinical description of the lesions.

The Committee are of opinion that Mr. Morris is so far justified in calling the case Xanthoma, as it is closely paralleled by Dr. Hughes's case, which Addison included in his original description of Xanthoma, or, as he called it, Vitiligoidea ('Addison's Works,' Syd. Soc. ed. p. 160).

The Committee consider that two other cases are on record which resemble these—one by Dr. Bristowe ('Path. Soc. Trans.' vol. xvii. p. 414), already alluded to by Mr. Morris; the other, a case in Dr. Hillairet's clinique, reported by Gendre in his 'Thesis on Xanthelasma.'

The ages of these patients ranged from 27 to 48 years; three were male and one female. They resembled each other in the following particulars:—

1. All of them suffered from Diabetes mellitus; in one the eruption probably preceded the diabetes.

2. The outbreak of the eruption was sudden in three; in the fourth there is no statement on this point.

3. Involution occurred in all, and was rapid when it once commenced; but the disease was stationary for a long period. The duration varied from three months to five years.

4. In all the elbows and knees were affected, and the eruption was confluent in those positions, though not at first; in three cases the face and buttocks were affected.

5. Dilated vessels upon the lesions are reported in two cases; no mention in the other two.

6. In all the eruption consisted of red, firm papules, some only of which had yellow tops which looked like pus; but incision showed them to be solid.

7. The eruption was confluent in some parts in all the cases.

8. Altered sensations, tenderness, pricking, or irritation are noted in three; in one shooting pains preceded the eruption.

These features more or less in common suggest that the cases belong to one group, but the Committee have grave doubts whether that group is Xanthoma multiplex, from which the cases differ in the following points:—

1. The sudden evolution and involution of the eruption.

In Xanthoma the development of the disease is slow, and involution is quite exceptional, it having occurred in four only out of twenty-eight adult cases, and was then very gradual indeed.

2. The lesions are firm and solid, while they are soft in Xanthoma.

3. Some only are yellow, and these only at the top; in Xanthoma they are always some shade of yellow, and the whole region is of uniform colour.

4. There were never any patches or striæ, a common feature in Xanthoma multiplex; all the lesions were tubercles or infiltrations distinctly raised upon the surrounding skin.

5. There was no jaundice, a very rare omission in *adult* Xanthoma multiplex; and unless the cases in question are considered to be Xanthoma, Diabetes mellitus has never been observed associated with Xanthoma, though Diabetes insipidus has been noted associated with eyelid Xanthoma.

6. The lesions appeared in many instances to be in the immediate neighbourhood of hair-follicles, a lesion not observed in Xanthoma.

7. The microscopic characters are not those characteristic of, and very constant in, Xanthoma.

Although the number of such cases is too small for absolute statements, yet they are evidently, both etiologically and symptomatically, closely related, and appear to form a definite group, with many of the features of lichen. Should further experience show that Diabetes mellitus is a constantly associated condition, the name of Lichen diabeticus would seem to be an appropriate designation; or, if Mr. Hutchinson's view be correct, Xanthoma diabeticum.

H. RADCLIFFE CROCKER.
ALFRED SANGSTER.

Postscript by Mr. Hutchinson.—Whilst agreeing in the main with the preceding report, I am still inclined to regard the disease as a near ally of Xanthelasma, and should prefer such a name as "Xanthelasma of the diabetic." I had, through the kindness of Mr. Malcolm Morris, a second opportunity (on April 11th, 1883) of examining his patient some months after we had met in committee. I then found in the left knee a group of spots which, when the skin was stretched, became distinctly yellow, exactly as those of Xanthelasma do. On the other knee was a similar group which did not show any yellow tint, and none of those on the tips of the elbows were definitely yellow.

Since the publication of Mr. Morris's paper, which we have here given in full, many valuable reports by different observers have been published. We have already briefly summarized our present knowledge of the subject at p. 29, and shall give some further details in the descriptions appended to the Plates in the present Fasciculus. In a future Fasciculus the subject will again receive attention. In the meantime, the reader may be referred to the "*Extract Book*," Xanthoma, No. 235, in the Polyclinic Library, and to the following papers:—

Pathological Society's Transactions, 1866. (Bristowe.)
" " " 1868. (Hilton Fagge.)
Archives of Surgery, vol. i., p. 381.
Clinical Society's Journal, May 8th, 1895.
British Journal of Dermatology, August, 1892.
" " " " November and December, 1893.
American Journal of Cut. and Genito-Urinary Disease, October, 1895.
" " " " " " May, 1894.
Transactions of American Dermatological Association, 1891.
Archiv. fur Derm. und Syphilis, 1897, p. 3.

CASES IN ASSOCIATION WITH PERSISTING JAUNDICE.

It is not purposed on the present occasion to enter upon any detailed description of this group of cases. It is well illustrated by Plates XCVI., XCVII., and H and I, and is summarised at page 28.

For the present it may suffice to remark that in order to form a clear estimate of the effects of the presence of bile products in the blood in producing lesions of the skin, we ought to make a collection of the cases of long-persisting jaundice from gall-stone obstruction. Of these a considerable number are recorded. We may just mention the following:—

Dr. Herska, of Carlsbad, has recorded one. A man of 27 had been jaundiced for seven years with the symptoms of obstruction of the common duct. Towards the end of this period he became the subject of Xanthoma. His elbows, knees, and buttocks were first covered with nodules. The upper lip, the ears, forehead, and one eyelid were also affected. A few months later the nodules had greatly increased in number in all parts, and the palms of the hands exhibited stripes of pale waxy yellow discoloration.

In a case given by Dr. Stout, of Philadelphia, a woman aged 50, who had for four years been the subject of jaundice from gall-stone obstruction (black jaundice), showed Xanthoma patches above the inner canthus of both eyes.*

Dr. Colcott Fox has briefly mentioned an unpublished case "in which a middle-aged woman who was under Dr. Ringer's care in University College Hospital with chronic jaundice afterwards died in the Middlesex Hospital with Xanthelasma of the eyelids and hands."

These cases are of importance as proving that a condition of Cholæmia, however induced, has a tendency to produce xanthomatous changes in the skin.

* See 'Journal of Cutaneous and Urinary Diseases,' June, 1894.

The present Fasiculus does not conclude the subject of Xanthelasma and Xanthoma. A number of other illustrations are in the artist's hands, and will appear in a future issue. The interval thus secured will allow of the introduction of additional observations on the several forms of disease known under these names. In the meantime, the Society's Council will feel indebted to any who may be able to supply either drawings or case-narratives in further illustration of topics concerning which all our knowledge is comparatively new. It is the desire of the Council that the present Atlas shall in all respects be brought up to the knowledge of the day, and be made of the utmost possible clinical value.

The microscopic anatomy of Xanthelasma and Xanthoma in their various forms has engaged the close attention of many able observers. Although there is a general concurrence of statement that the changes commence by the accumulation of zones of small cells in the perivascular, lymphatic, and inter-fascial spaces, which tend rapidly to become fatty, yet there are great discrepancies as to details. These have arisen in part from differences in the methods employed, but also in some small degree from lack of familiarity, on the part of the observer, with the clinical features of the disease. It is hoped that the present publication will to some extent supply the want which has unavoidably been felt in this direction, and enable all who care to do so to become practically conversant with the details of the special features of these rare maladies.

A *Resumé* of Histological observations will be given when the subject is again in hand.

PLATE A.

LONG PERSISTING XANTHOMA DIABETICORUM IN A WOMAN.

In conjunction with Dr. J. C. Johnston, of New York, Dr. Sherwell, of Brooklyn, has recorded the case of a woman, whose condition is illustrated in this Plate. The patient was 40 years of age, and somewhat plethoric. She was the subject of diabetes, although she considered that she had always enjoyed fairly good health. Of late the lesions in her hands and feet had caused much pain, and entirely incapacitated her for her household duties. The history of the diabetic symptoms extended back for five years, and it was about the same time that the first lesions on the skin were observed. The distribution of those lesions is well illustrated in the engravings, and need not be specified.

Dr. Sherwell states that at a little distance the lesions might have been mistaken for variola in a pustular stage. The pustules were rounded at their tops, and surrounded by dark red inflammatory halos. The palmar and plantar surfaces were involved, but the eyelids were entirely free. Under an anti-diabetic regimen both the diabetes and the eruption were for a time greatly improved. [See 'Transactions of American Dermatological Association for 1901, p. 165.]

Postcript.—A report, for which we are indebted to Dr. Sherwell, enables us to bring this case nearly up to date. The woman, we are informed, has been careless as to her diet and general treatment, and her eruption still persists in much the condition shown in the portraits. Although there is still sugar in the urine, her physical strength and general appearance are not markedly worse. She was last seen in the spring of the present year, 1902, rather more than two years subsequent to the date of the preceding notes.

PLATE B.

ERUPTIVE XANTHOMA IN A BOY, ASSOCIATED WITH XANTHELASMA OF EYELIDS.

This portrait is copied from one given (with colour) in the 'American Journal of Cutaneous Diseases' for July, 1890, by Mr. George Thomas Jackson, of New York.

The patient was a boy, aged 5, of poor parents, by whom he had been somewhat neglected. The statement given was that he had never had jaundice, and that he had always been thin. He had, however, been accustomed to mix with other boys, and had never ailed anything in particular. It was said that the eruption appeared when he was three months old, and without any antecedent ill-health. No enquiries could be made concerning his predecessors.

The boy at the time of observation was thin, a blond, and of pale skin. His appetite was good, and digestion excellent. There was no diabetes. The distribution of the eruption is well shown in the portrait. In the original, as it is given by Mr. Jackson, it is coloured a deep yellow. The whole body of the boy is said to have been occupied by a disseminated efflorescence, no part being spared except the hands, feet, and scalp. The lesions were about the size of split-peas, or smaller, and were soft to the touch, and showed central depressions. On the face, trunk, shoulders, and lower parts of the legs they were discreet, and scattered about without any particular arrangement. In some parts they were crowded into patches of various sizes and shapes, with normal skin between them. Even in these groups the spots remained distinct from each other. They touched, but did not coalesce. The distribution was quite symmetrical. The colour varied from a lemon yellow to an orange yellow tint, and about the joints was of a reddish brown.

The right eyelid showed typical patches of Xanthelasma of a chamois-leather colour. The lower lid was occupied by one continuous patch, which extended from the inner to the outer canthus. On the upper lid there was a small tumour. The lids of the left were but very slightly affected.

Upon the back of the neck and the upper part of the back itself were a number of bright brown pigmented spots, which the boy's sister said were the remains of some lesions which had disappeared. Scattered about the trunk were a number of depressed scars, apparently the result of recent varicella.

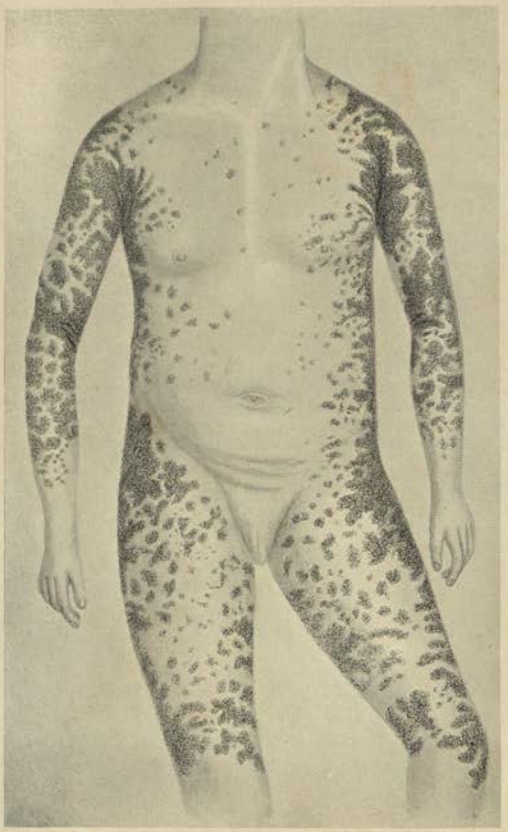

PLATE C.

ERUPTIVE XANTHOMA OF DIABETICS.

This Plate shows the distribution of the Eruption in a case published by Dr. A. R. Robinson. The patient was a man who was the subject of diabetes. [See also next Plate.]

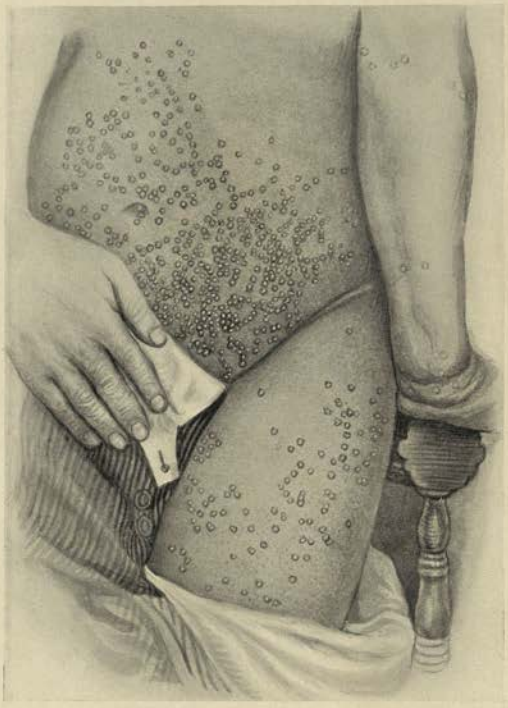

PLATE D.

ERUPTIVE XANTHOMA OF DIABETICS.

A back view of Dr. Robinson's patient. [See Plates B and E.]

PLATE E.

A STUDY OF THE ERUPTION IN DIABETIC XANTHOMA.

This Plate is copied from Dr. A. R. Robinson's report of a case of Diabetic Xanthoma. It shows well the remarkable tendency often seen in Xanthoma for the tubercles to remain discrete and wholly without coalescence, even when they touch each other.

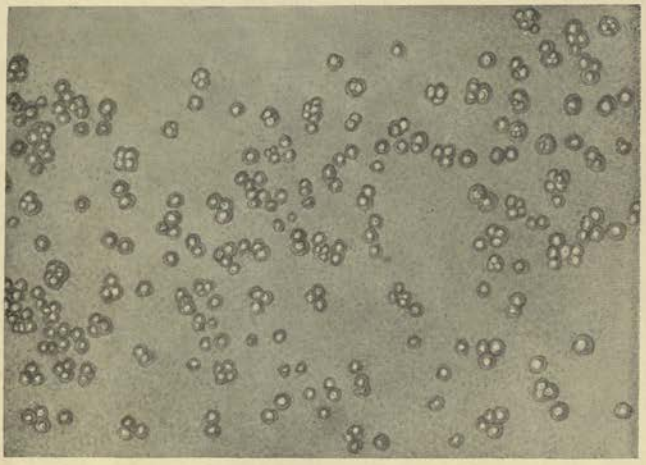

PLATE F.

XANTHOMA OF THE PALM.

This figure is copied from one given in Kaposi's 'Atlas,' and shows Xanthoma of the palm in an early stage. As yet it is arranged only in streaks along the lines of flexure—"Xanthoma striatum."

PLATE G.

XANTHOMA OF THE PALM.

This Plate is copied by permission of the publisher, Mr. Young Pentland, from one given in Dr. Radcliffe Crocker's 'Atlas.' It represents the palmar aspect of a hand, in which not only are there linear striæ in the creases, but numerous patches of little tubercles at other points.

PLATE H.

XANTHOMA OF THE PALMS IN ASSOCIATION WITH PERSISTING JAUNDICE.

This Plate is copied from one given in Kaposi's 'Hand-Atlas of Dermatology.' It represents the palm of the hand in a man who was the subject of persisting jaundice, and in whom Xanthoma had developed. The conditions are what are sometimes designated Xanthoma planum. The patches are not confined to the lines of flexure, but spread widely in the palm, and on the palmar aspect of the digits. The difference from what is known as Xanthoma lineare is, however, only one of extent. It is the common condition in the Xanthoma of jaundice, and is seen also occasionally in that of diabetics.

[Compare with Plate XCV.]

PLATE I.

GROUPED XANTHOMA TUBERCLES ON THE FRONT OF KNEE.

In this portrait we have a group of Xanthoma tubercles occurring on the front of the knee. They are closely set, but nowhere actually confluent. The patient, an adult, was the subject of chronic jaundice. The conditions were bilateral. In almost all cases in which Xanthoma occurs as a general eruption, there is a tendency for it to affect the fronts of knees and tips of elbows.

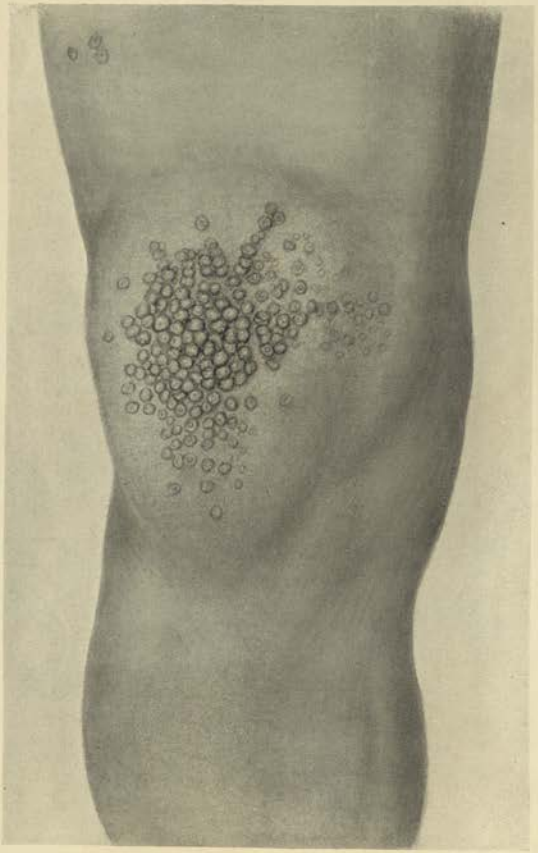

PLATE J.

JUVENILE XANTHOMA IN AN ADULT.

The figures in this plate and the three following are copied from photographs taken at the Hôpital St. Louis by M. Meheux for Dr. Thibierge. They illustrate an extraordinary condition of tumour-like growth attained by the papules of Xanthoma juvenile in an adult. The characteristic positions were affected—the tips of the elbows, the fronts of the knees, and the skin overlying the tendo Achillis. In all of these thick tuberous masses have been produced. Thus it appears to be proved that the papules of Xanthoma of childhood may continue to grow, and may ultimately attain the size of large tumours.

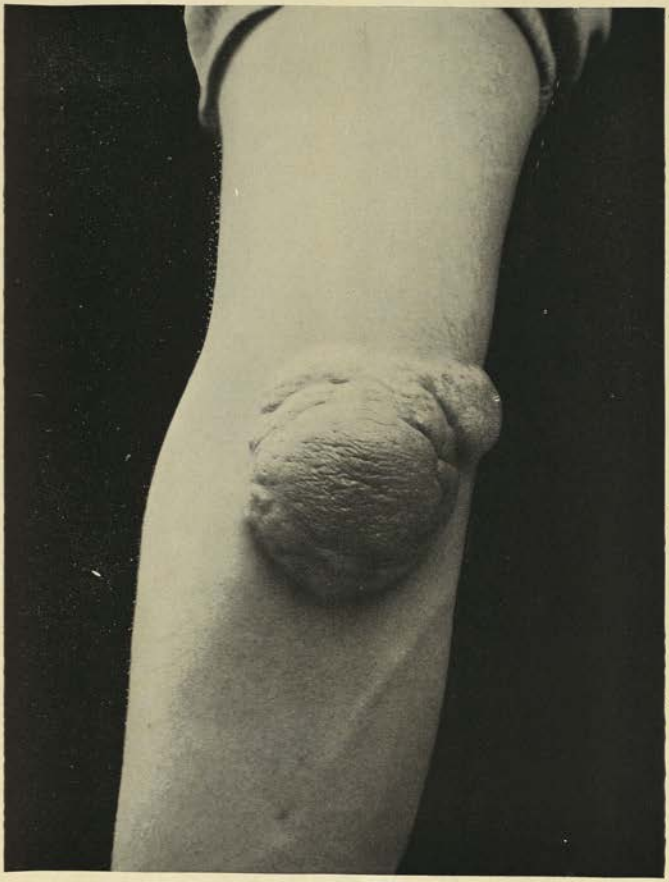

PLATE K.

JUVENILE XANTHOMA IN AN ADULT.

A group of Xanthoma tumours on the skin of the buttock. These, it will be observed, occur in precisely the same positions as those usually affected in childhood They have, however, grown from small papules to tumours of considerable size.

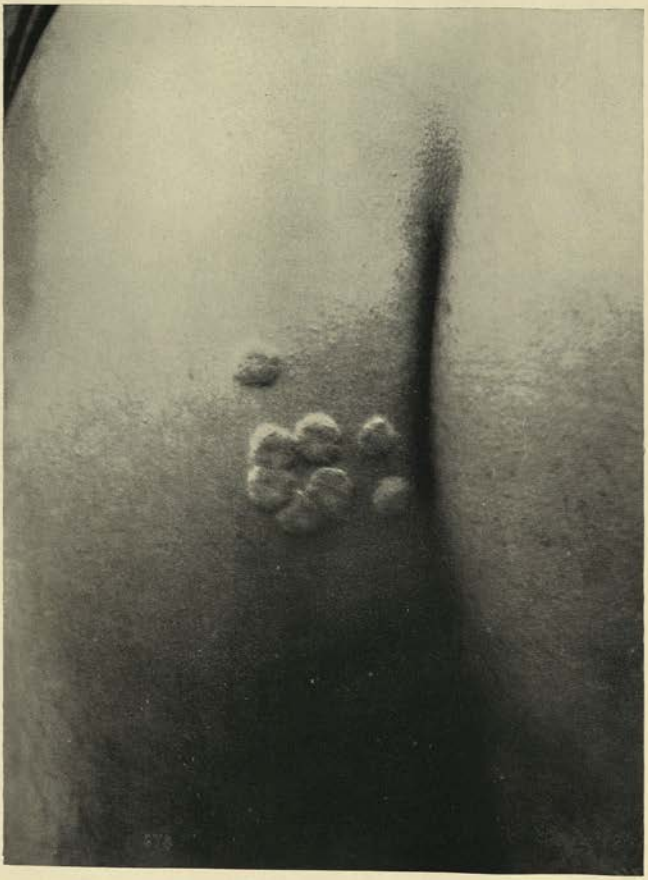

PLATE L.

JUVENILE XANTHOMA IN AN ADULT.

Xanthoma tumours on the region of the knee. A large thick mass is seen just over the patella, and several smaller ones above it. [See description of Plates I and J.]

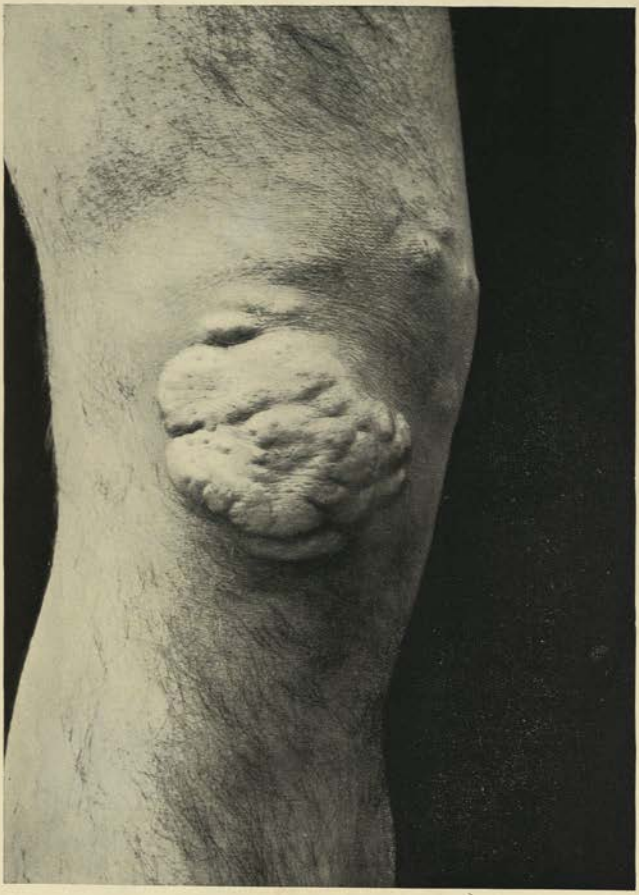

PLATE M.

JUVENILE XANTHOMA IN AN ADULT.

Xanthoma tumours over the tendo Achillis. A large thickened mass is seen just above the heel, and some smaller ones a little above it. [See descriptions of the three previous Plates from the same subject.]

PLATE XCI. *bis.*

FRAMBŒSIAL SYPHILIS IN ENGLISHMEN.

The Plate which is here given belongs properly to the last Fasciculus, from which it was omitted owing to misunderstanding on the part of the printer. It illustrates the form of eruption in the Secondary stage of Frambœsial Syphilis (so-called "Yaws") in two Englishmen. It is referred to at page 12 of Fasciculus 1. Well-characterised Frambœsial eruptions are rare in the white-skinned races both at home and abroad. In both these two cases the disease was contracted in Africa, and in both the eruption was in the first instance well-marked. They are probably the only cases in which those who had contracted the disease abroad, and in whom it had been diagnosed as Tropical Frambœsia or Yaws by those familiar with the malady so-named, have ever come under observation in England. Cases of Frambœsial Syphilis have been observed repeatedly, and with well-marked characters, in those who had contracted Syphilis in England, but these two have the peculiar interest that the disease was acquired in countries where the so-called Yaws is a common type of Syphilis.

Both cases will be found recorded at page 195 of 'Archives of Surgery,' vol. ix., and one of them has been published in more detail by Dr. Boyden in one of the volumes of the Army Medical Reports.

The interest attaching to each of the two figures is different in its nature. The uppermost figure is given because it shows exceedingly well the character of the granulation-mass which constitutes the frambœsial excrescence or fungus. It was the only one which remained on the patient's skin at the time that the sketch was made. In other respects the eruption had, under modified specific treatment, passed into the condition shown in the lower figure, only not so abundant.

The lower figure is given in proof that the frambœsial type of eruption is not a persisting one when "Yaws" is treated with specifics. In this patient, in the first instance, the eruption was much like that shown in the other, but before the man arrived in England all trace of frambœsial fungation had vanished, and the skin showed a remarkably polymorphous and widely diffused eruption. In the palms of the hands and soles of the feet there were peeling patches, which were considered characteristically syphilitic by all who saw them. A subsequent complete cure under mercury still further confirmed the diagnosis. The patient was produced before a meeting of the Tropical Medicine section of the British Medical Association, and an unanimous vote recorded the opinion that the case was one of Syphilis.

The history of the other case (Dr. Boyden's) was very similar. In that instance the primary sore had been caused by a prick from a hypodermic syringe which had been used on a Yaws patient. In the other case no cause could be assigned for the original sore, which had been developed on the forearm of a young man, probably by the accidental inoculation of a scratch. He had associated with natives (in Benin) who suffered from "Yaws."

The two cases were in all respects remarkably alike, the disease observing much the same stages, and running a parellel course. They appear to prove that there is a local sore or chancre in African Yaws, that earliest form of eruption is erythematous, as in Syphilis, the next of frambœsial type, and that when the latter subsides its place is taken by a polymorphous dermatitis, of which peeling patches in the palms and soles are a very definite feature.

In Dr. Boyden's case, nine months had elapsed since the inoculation, and in the other about fourteen months. Both patients are now quite well.

PLATE XCII.

ERUPTIVE XANTHOMA IN A CHILD.

This portrait, which shows the upper arm of a child, aged 3, has been copied from a drawing kindly supplied by Prof. McCall Anderson. The child was admitted into the Glasgow Infirmary in May, 1892. She was an orphan, and was reputed to have always been healthy. No date could be assigned to the commencement of the eruption, nor could anything be ascertained as to the diseases which had occurred in her family. The eruption consisted of small papules very closely set, and in some places confluent. They were rounded and had a flat surface, which glistened in certain lights. They were elevated, and of a light buff colour, and rather soft to the touch. The skin upon which they occurred was not in the least altered.

The eruption was symmetrical, and occurred on the face, neck, shoulders, arms, and legs, being most copious on the shoulders. The papules and the patches formed by their coalescence were grouped in irregular clusters. The largest of these clusters was situated over the deltoid on each side, and extended along the outer aspect of each arm as far as the elbow. It is this cluster on the left side which is represented on the plate. A few papules were scattered over the flexor aspect of the arms as far down as the wrists, but there were none on the hands. A large band of eruption ran from the lobe of the ear on one side beneath the chin to the corresponding point on the opposite side. The eruption was scantily present on the forehead, and there were only a few discrete papules on the cheeks. The trunk was free in front and also on the back as low down as the hips. There were papules on both thighs as far as the knees, and a few scattered ones on the flexor surfaces of the knees and legs. The feet were not affected. Some of the nodules were excised, and were carefully examined by Dr. Joseph Coates. Nothing is known as to the sequel of the case. It is of interest to note that in this instance the eruption, both in its characters and in the parts affected, very closely resembles the eruptive Xanthoma of diabetes. It was very different from that of several other cases of the juvenile type in which tuberous masses formed on the knees, elbows, and heels. It may be conjectured that the inheritance was from a progenitor who had suffered from the diabetic form. [Compare with the next plate.]

West, Newman chrom.

PLATE XCIII.

ERUPTIVE XANTHOMA OF DIABETICS.

In this portrait is represented the conditions present in an eruptive attack of Xanthoma in a man who was the subject of diabetes. It will be seen that the yellow papules, which occur abundantly on the upper extremities down to the middle of the forearms, are all discrete. There are a few on the pectoral regions, and there were many others on the usual positions. The patient was under the care of Dr. Barratt, at St. John's Hospital, by whom he was sent to the Clinic at Park Crescent, where the portrait was taken.

This case is recorded at page 270, vol. vi., of 'Archives of Surgery.' The patient was a man aged 52, stout, and having the appearance of excellent health. He asserted that he had never ailed anything in his life. He became aware, six weeks before he was brought under observation, that he was passing an excessive quantity of urine, and about the same time his eruption began to appear. Dr. Barratt found on examination that the urine was of high specific gravity, and contained much sugar. The eruption occurred chiefly on the four limbs, including in that term the shoulders and haunches. The eruption soon after the portrait was taken began to disappear.

PLATES XCIV. & XCV.

ERUPTIVE XANTHOMA OF DIABETICS WITHOUT SACCHARINE URINE.

These Plates illustrate the conditions present in a very important example of the eruptive form of Xanthoma. The man who was its subject had never been actually jaundiced, nor was he seriously out of health. He had, however, been liable for many years to slight attacks of migraine. Not only was the eruption present in the positions most usually affected in typical examples of Xanthoma diabeticorum, but the palms of the hands were affected by yellow streaks in their flexures exactly as occurs in the Xanthoma of confirmed jaundice. The tips of the elbows showed groups of tubercles more or less confluent, just such as are seen in the hereditary form, and sometimes in that of jaundice. Had there been patches on the eyelids, the patient would have presented a synopsis of all the type-forms united in one person.

Mr. A. S., a single man, aged 30, came under Mr. Hutchinson's observation in October, 1900. He was good enough to attend at the Polyclinic for demonstration, and also to permit the photographs to be taken from which these plates have been copied. The eruption had been out about six months, and had been first observed on the buttocks, and next on the elbows. It still occurred most conspicuously on these parts, but spots were scattered over the arms, the neck, and the lower limbs and the trunk. On the backs of his hands were a few little tubercles, which looked much like the buttons of Molluscum contagiosum, with the difference that they showed no central orifices. They were taken for Molluscum at the first glance, but when the patient stripped the diagnosis became clear. In the lines of flexure of his palms and across the digits, the skin was of a light yellow tint, somewhat polished, and showed a tendency to crack. The state of his hands had quite disabled him from golf, of which he had been fond. On the buttocks the tubercles were thickly placed, but were for the most part discrete. They were of lemon-yellow tint. On the tips of elbows and fronts of knees there were groups of yellow tubercles, which in some instances had become confluent. The papules were firm and almost shotty, and were blunt-pointed, or beehive-topped. They varied in size from a shot to a small pea. On his feet just above the clefts of his toes they were gathered into confluent patches, which had become polished on their surfaces. The eruption was scattered over the whole surface excepting the face, and differed from the common type of Xanthoma diabeticorum only in being of a less pronounced tint of yellow. Some of the papules indeed were scarcely yellow at all.

The history of the patient and his relatives presented some features of interest. His father had suffered from jaundice, but had recovered, and was still living. Two of his sisters were liable to egg-poisoning, and were always made severely bilious if they ate eggs. He himself could eat eggs with impunity, but he could not take butter or cheese, a peculiarity in which his father shared. He had himself never been jaundiced, but thought that he had repeatedly been on the verge of it. He had suffered from severe sick headaches attended by "swimming before the eyes," and had been liable also to attacks of severe abdominal pain, his description of which fitted well with the symptoms of passing gall-stones. In earlier life he had taken whisky freely, but for six years had been a total abstainer. He could digest bacon and ham well, and was fond of them. His urine he reported as usually clear and bright, but in former life it was often thick and muddy. It had now a sp. gr. of 1020, and did not contain sugar.

It will be seen from these facts that the case is one in close alliance with obstructive jaundice, although the patient had never had a declared attack. No doubt on many occasions bile products had temporarily accumulated in the blood.

Plate XCIV. shows the eruption on the buttocks, and the three figures in Plate XCV. show the confluent patches on the elbows and the streaks in the palm of the left hand.

Two years after these portraits were taken I was informed that the eruption had wholly disappeared, and that the patient was in good health. The treatment had been by a moderately strict diabetic regimen, and the use of Taraxacum and small doses of mercury.

West, Newman chromo.

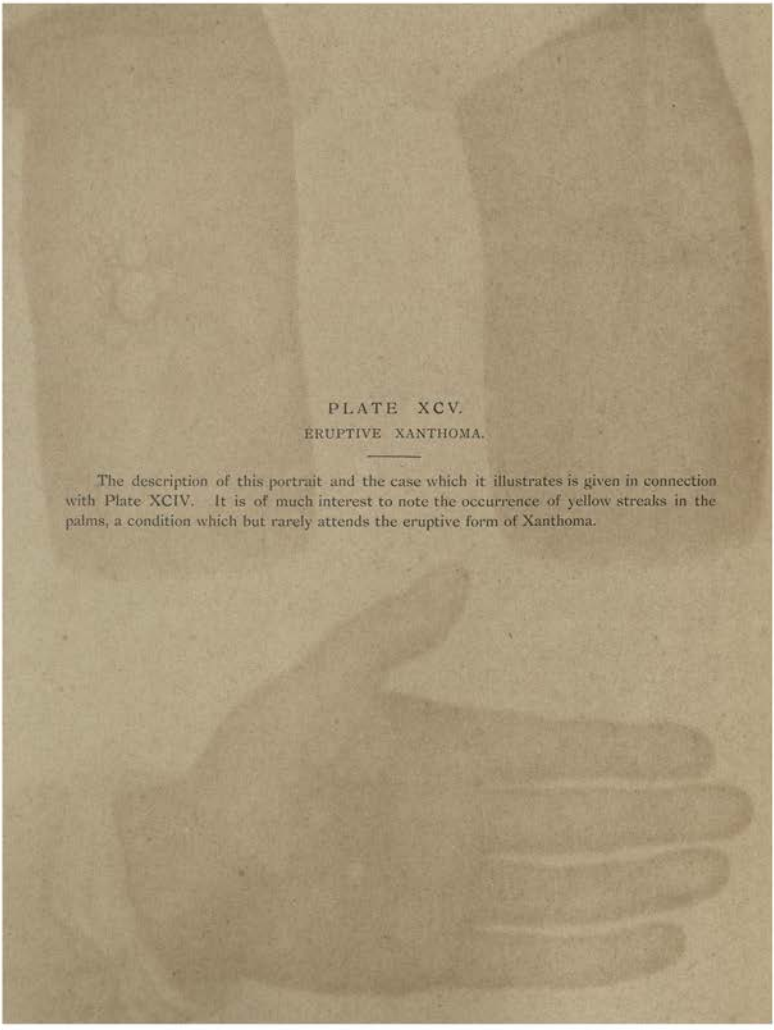

PLATE XCV.

ERUPTIVE XANTHOMA.

The description of this portrait and the case which it illustrates is given in connection with Plate XCIV. It is of much interest to note the occurrence of yellow streaks in the palms, a condition which but rarely attends the eruptive form of Xanthoma.

West, Newman chrom.

PLATES XCVI. & XCVII.

CASE ILLUSTRATING THE XANTHOMA OF PERSISTENT JAUNDICE.

The particulars of this case have been published by Dr. Abercrombie.

Dr. Abercrombie's patient was a woman, aged 61, extremely lean, and of a deep yellowish brown tint everywhere. All traces of subcutaneous fat and cellular tissue had disappeared, and her sinuous temporal arteries were very conspicuous. She had a quite clean, red tongue, and averred that her appetite was excellent and digestion good. In former life she had, she said, been bilious and dyspeptic, but of late years this liability had left her. Although distinctly bilious and of a bilious family, she had never suffered from jaundice until the commencement of her present attack about a year ago. At that date she became gradually very yellow, but it did not appear that she had had any acute or sudden attack of jaundice.

The conditions displayed by the skin were almost universal. As already stated, the general tint was that of a deep yellowish brown. The xanthomatous patches were of a much lighter yellow than the rest of the surface. They were little if at all thickened, and could scarcely be detected by the finger. They occurred chiefly on the eyelids, the hands, elbows, and sides of the abdomen, but were present also in greater or less abundance on many other parts. On the eyelids they presented somewhat exceptional conditions, consisting of an aggregation of little papules of a paler yellow, and less smooth than is usual in Xanthelasma. The disease was here so extensive as to completely surround the eye. The skin of the hands was dry, harsh, and discoloured on both surfaces. The Xanthoma conditions were most definitely seen as rather wide streaks of light lemon-yellow along the lines of flexure in the palms and palmar aspects of fingers. The conditions were everywhere symmetrical, and on each side of the abdomen there was a large patch of discrete yellow spots arranged exactly like herpes, and as big as the outspread hand. Excepting that they were more yellow, and not at all hardened, these groups of spots were very like what are often seen in Morphœa.

The liver was of enormous size, hanging down nearly to a level with the iliac crest. It was uniformly enlarged in all its parts, and its right lobe was very easily felt on a level with the umbilicus. Its surface was tolerably smooth and uniform. Its size was such as to constitute a very conspicuous tumour.

In spite of this condition of the liver and the protracted jaundice, the patient, as already stated, asserted that she had an excellent appetite and good digestion. In former times she had, she said, been bilious and liable to indigestion, but, curiously enough, since her present malady had attacked her, her digestion had improved. She could now, she said, eat almost anything, even pork.

This patient died a few months after the portraits were taken.

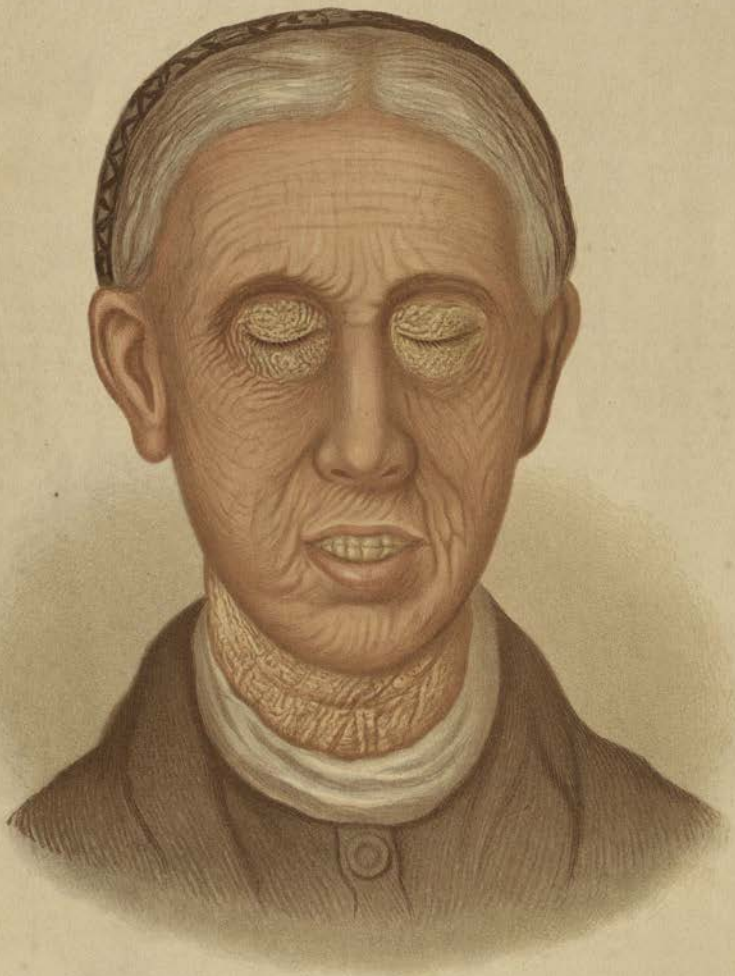

West, Newman & Co. imp.

West, Newman chromo.

AN

ATLAS OF ILLUSTRATIONS

OF

CLINICAL MEDICINE, SURGERY

AND

PATHOLOGY

(CHIEFLY FROM ORIGINAL SOURCES).

FASCICULUS XVI., OR V. OF NEW SERIES.

COXA VARA

PLATES A to I.

LIBRARY OF THE BOMBAY BRANCH OF THE ROYAL ASIATIC SOCIETY

WITH REPRINT OF ESSAY BY

C. R. B. KEETLEY, ESQ., F.R.C.S.

MISCELLANEOUS

PLATES J to L.

LONDON:
THE NEW SYDENHAM SOCIETY.
1903.

COXA VARA.

The conditions to which this name has of late years been applied are caused by changes in the obliquity, position, and length of the neck of the femur. The neck becomes shorter, more or less horizontal. It may even join the femur at right angles or may appear to have slipped lower down on the shaft of that bone. There is, in addition to these conditions, a bending backwards of the trochanter and shaft, so that the neck is slightly convex forwards. These conditions are evidenced in the patient by real shortening of the limb, with eversion, prominence of the great trochanter, elevation of the great trochanter above Nélaton's line, and a varying degree of lameness. The conditions may be slight or extreme, and they may be due to various forms of primary disease. Their severity will depend greatly upon the age of the patient at the time of the beginning of the disease which caused them. The earlier their commencement the greater will be the deformity, since the development of the bone is then less advanced.

The causes of Coxa vara are various, and in connection with them the cases may be classed into several groups :—

1st Group. The first, and by far the largest, is that in which the disease is rachitis. In these cases it may begin at any age, even during intra-uterine life, and it usually does so during early childhood. Both hips are commonly affected, and great deformity results. The conditions may even be mistaken for congenital dislocations of the hips.

2nd Group. In this we may conveniently place cases beginning in adolescent life, and usually on one side. In this, disease of the hip-joint is simulated, but the symptoms pass off after a time, and the joint itself is left free. Some of these cases may be due to "the rickets of adults," but there is often no proof of such a condition. The seat of the disease is probably the epiphysial cartilage, and its cause probably some slight sprain or contusion. The case which is described in connection with Plate A may stand as a good type example of this group.

3rd Group. In this we may place cases commencing after the ossification of the neck of the femur is complete. They are comparatively few in number.

4th Group. This group may include cases in definite relation with the osteo-arthritis of rheumatic gout, or with attacks of acute gout in the hip-joint. It would appear that any inflammatory process near the hip-joint may be conducive to loss of resisting power in the neck of the femur, and to conditions not distinguishable from Coxa vara. They are, in fact, a part of almost every case of Morbus coxæ senilis, and sometimes advance to very great deformity.

It will be seen that the grouping which we have suggested presupposes that there is no one disease which to the exclusion of others claims the name of Coxa vara, but rather that the aggregate of changes which receive that name may result from various causes. There are cases which are well characterised and typical, and others which are much less so, but there is no one which ought to be known as true Coxa vara. The changes in the bone involved, which make up the condition so named, are susceptible of various modifications in connection with the age of the patient and the nature of the exciting cause.

With the exception of the rachitic cases, Coxa vara is usually observed on one side only. In rickets it is commonly symmetrical,

and whenever it is so rickets should be suspected.

The New Sydenham Society is much indebted to Mr. Robert Jones, of Liverpool, for having liberally placed at the disposal of the Editor of the Atlas his rich collection of radiographs, taken from patients under his care in the Liverpool Southern Hospital. These radiographs are, without exception, most successful productions, and their merit is, we believe, due to the skill and energy of Dr. David Morgan, who assisted Mr. Jones in their production. We shall have to be indebted to these gentlemen so frequently, that it may be convenient, in designating the source of the portraits which we reproduce, to speak of the "Jones-Morgan Collection."

To Mr. C. R. B. Keetley the English profession is chiefly indebted for having its attention drawn to Coxa vara, and a case observed by him was one of the earliest that were correctly described. Mr. Keetley has kindly placed at our disposal a paper communicated by him to the Medical Society of London, vol. xxiii., and, at the risk of some repetition of what has already been said, we reprint his paper in its entirety.

COXA VARA.

By C. R. B. KEETLEY, F.R.C.S. Eng.

COXA VARA may be defined as a deformity of the upper epiphysial region of the femur, in which the head of the bone sinks to a lower level than normal, in extreme cases almost touching the lesser trochanter. Coxa vara has also been named "curvature of the neck of the femur," but it is not likely that so

FIG. 1.

The upper epiphysial region of the femur; I, II, III, epiphyses. (From a specimen in the Museum of the Royal College of Surgeons of England.)

short and handy a name will be displaced by a phrase including seven words, and not less open to criticism. In Coxa vara the upper border of the neck of the femur is longer than normal, and the lower border shorter than normal (see Figs. 2 and 3). The upper border may be as much as three times the normal length. A necessary result is that the neck is more horizontal than normal, or it may descend instead of ascending in the usual way. The articular surface of the head may thus come to look downwards. There is another remarkable and practically important change. The neck is bent in a

FIG. 2.

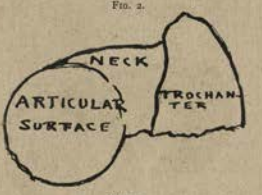

FIG. 3.

Fig. 2 and Fig. 3 respectively posterior and anterior diagrammatic views of the neck, &c., of a femur affected with Coxa vara. (After Kocher, 'Deutsche Zeitschrift für Chirurgie,' 1894, Band XXXVIII. p. 536.) Note the articular surface looking backwards and downwards instead of inwards and upwards.

horizontal as well as in a perpendicular plane, with the convexity forwards (Figs. 4 and 5).

Coxa vara does not consist of a mere diminution of the angle formed by the long axis of the neck with the long axis of the shaft of the femur. Indeed,

the changes are not confined to the neck. They always involve the head, and sometimes extend some distance down the shaft, just as in genu valgum the deforming influence often affects and curves the lower third or half of the shaft. The horizontal change is perhaps not constant. It manifests itself clinically by producing eversion and diminished range of inversion of the limb. Hofmeister arranged a collection of fifty-three cases of Coxa vara into three groups:—(1) With no outward rotation; (2) with outward rotation; and (3) with inward rotation (rare, only three cases). No one but Hofmeister himself had met with examples of this third group. In one of his cases one limb belonged to group 1 and the other to group 3. When a perpendicular

FIG. 4.

FIG. 5.

Similar specimen to that sketched in Figs. 2 and 3, but viewed respectively from above and from below. (Pen-and-ink sketch after Kocher's engravings, showing the horizontal curvature of the femoral neck, which limits the range of inversion.)

section is made, the strongest and most compact part of the bone is seen to be not the lowest part of the neck, but the upper part, near the epiphysial cartilage, on both the distal and proximal side of that cartilage.

The articular cartilage is sometimes thinned towards the centre of the head. Usually there are no osteophytic growths, and, with the exception of my own first case, no recent signs of rickets have been seen on microscopic examination, perhaps because the rachitic process was over, though leaving the deformity behind. A microscopic examination of the wedge of bone removed from my case was made by Dr. W. S. Colman, then house physician at the West London Hospital. It showed "exactly such changes as are seen in bones known to be affected with rickets." Very frequently other, probably rachitic, deformities co-exist. The co-existence of scoliosis and genu valgum suggested to me the correct diagnosis in my first case.

Writers who do not believe in the relation of rachitis adolescentium to Coxa vara seem to have curious ideas of what are the usual symptoms of the former affection. For instance, one author says of a case:—"No evidence of rickets; genu valgum present on both sides"! Surely the conjunction of Coxa vara and genu valgum is itself evidence of rickets, though, of course, not conclusive.

Adolescents attacked with rickets do not present the same clinical picture as infants. They are not visibly rachitic in every limb. They are not pot-bellied, bow-legged, beaded-ribbed, &c., any more than they are unable to walk or collapse in the spine when they sit down. The older a person is when attacked with rickets, the more limited and localised are his resulting deformities likely to be.

Deformity of the upper end of the femur, including increased angularity of the neck, has been recognised for many years as a common symptom of general rickets in young children. Jenner referred to it in his lectures. What has attracted so much attention in the last eleven years is the deformity when observed in adolescents.

I believe that in many, if not in most, cases of genu valgum the knee deformity is a compensatory curve to a certain degree of Coxa vara. It would take too long a digression to give reasons, but I would invite anyone interested in the question to examine the rachitic skeletons preserved in our museums.

Another thing which I have twice distinctly noticed in cases of my own, and which I believe I can trace in the portrait given by Kocher of one of his cases, is an alteration in shape of the bones of the face and forehead. I do not like to call it a deformity. It is not necessarily unpleasing. It is most marked in one case. The facial bones seem thin and expanded, especially in the orbital and nasal regions. I do not say they *are* thin, only their appearance of expansion suggests it. The orbits are shallow, and the eyeballs are inclined to be prominent. The ridge of the nose does not rise sharply. In fact, there is a lowness of relief about some of the features, but something essentially different from the ordinary "flat face."

Symptoms.—Pain in the hip, brought on or increased by walking, is almost always the first symptom noticed. This pain may extend down to the knee, which is perhaps one reason why these

cases have been so often confounded with hip disease. Soon afterwards the patient begins to limp, and soon tires on walking. In bilateral cases the second hip is generally attacked soon after the first, *e. g.* at an interval of three or four months. The usual age at commencement is from 12 to 18 years, especially about 15 years of age. Eventually the objective signs appear. The trochanter rises above its proper level, usually with shortening of the limb as a result. Abduction becomes limited or abolished at the hip, flexion also, as well as internal rotation. The foot is generally more or less everted. Genu valgum appears. It is probably a compensatory curvature. Flat-foot and lateral curvature of the spine are occasionally seen. In severe cases the movements of the hip become extremely limited, so that it may easily be supposed by mistake to be the seat of fibrous ankylosis. In a small proportion of cases external rather than internal rotation is reported to have been limited. Sometimes flexion is comparatively free. The range of flexion can sometimes be increased by everting the limb. Passive mobility generally seems to be greater than active mobility. As is apt to be the case with ordinary flat-foot, the venous circulation is often not good, and the extremities tend to be rather cold and blue when allowed to hang down. When the thigh is much adducted, the knees are thereby brought one in front of the other. It is then especially that genu valgum is likely to co-exist. A single-hip case limps, but when both hips are affected the sufferer waddles, shuffling one knee round the other as he walks. When the hips and knees are flexed in such a case the thighs cross.

Diagnosis.—My first case, the subject of which had visited various surgeons and hospitals, had been diagnosed as respectively periostitis of the femur (the trochanter was broader as well as higher than normal), sarcoma of the femur, and dislocation of the femur on the dorsum ilii. Other cases have been diagnosed as "arthritis adhæsiva." I am afraid I do not know the meaning of this term, unless it means ankylosis secondary to inflammation of the joint. According to Frazer, it was the diagnosis made by Kocher of his first case before he had excised the joint, and had seen the nature of the case explained by the specimen. I have seen a case exhibited at a society as one of separation of epiphysis, and when I asked for the points which distinguished it from Coxa vara, the distinguishing symptoms pointed out to me were exactly like those of Coxa vara. This case, or rather the skiagrams of it, are published as a case of separation of epiphysis. I have tried, but unsuccessfully, to see the patient. The waddling gait of congenital dislocation may suggest Coxa vara. But the looseness of the joint in most cases of congenital dislocation contrasts with the stiffness of Coxa vara. Coxa vara contrasts with hip disease in the following points. Gentle passive movements and pressing the head into the acetabulum are not painful. There are no startings at night. As a rule, wasting of the thigh is much less marked, though not absent. The head can be felt in the acetabulum, however high the trochanter may be, and it is not tender to direct pressure. Pain is easily relieved by rest without fixation. Roentgen rays are of the greatest value in finally settling the diagnosis. The skiagram should be studied in connection with the general clinical picture presented by the case. Nothing is more misleading than a skiagram studied by itself.

Prognosis.—The disease is progressive at first, but it tends ultimately to come to a stop. The deformity remains. In the worst cases not only is there great shortening, but the joint is so stiff that the patient has difficulty in lacing his boots and in sitting down comfortably, especially on a low chair, and is easily fatigued by walking. The general health does not suffer, except indirectly through pain and want of exercise.

Treatment.—An obvious indication is to restore, as far as possible, the natural shape of the bone by osteotomy. Another is to relieve the pain by rest. A third is to increase the range of movements by passive exercises, and even by forcible movements under anæsthesia. One of my patients said that he was thus benefited by a bone-setter, who, I need not add, was quite mistaken as to the nature of the case he had to deal with. Palliative measures are rest in bed, with or without extension. Two or three weeks generally suffice to remove the pain and some of the stiffness. In old-standing cases iodide of potassium and salicylate of soda, as well as the systematic use of purgatives and massage, might be also tried. I am referring to middle-aged patients, or at least to cases of, say, ten years' standing, in which there is sometimes a suspicion of complication by gout or rheumatism. Bicycling was of great benefit to one of these cases (a unilateral Coxa vara of twenty-five years' duration). In the early years of the case sea-air, Parrish's food, and other anti-rachitic remedies should be tried. It is impossible to say when such treatment ceases to be useful. Although I think that the influence of weight pressure is a factor that has been greatly exaggerated in explaining this deformity, carrying weights to the extent of causing fatigue should be avoided, and if the patient's occupation necessitates this he had

better change it. None of my own patients followed occupations requiring them to carry weights. The relief of pain and stiffness by rest is apt to prove of only temporary value. Both are liable to recur after exposure to fatigue or on the occurrence of damp weather. Massage is frequently recommended. It can at best only relieve aching and lessen stiffness. It cannot affect the deformity.

FIG. 6.

From the case described by me in the 'Illustrated Medical News' for September, 1888. Note the adduction at the left hip, the genu valgum, the eversion and the shortening. The prominence at the hip is not the great trochanter, but is due to a curve in the shaft below. The great trochanter could be felt much higher and considerably above the level of the head of the femur, which could be felt in the normal situation. I performed a subtrochanteric wedge-osteotomy on this case in 1888. A skiagram of this case demonstrates in the hip the characteristic changes of Coxa vara.

Operative Treatment.—In some of the earlier cases a mistaken diagnosis led to the excision of the head and neck of the femur and part of the trochanters. As the joint is practically healthy, excision is now pretty generally condemned. The original excisions served a useful purpose, however, because they furnished the specimens from which first Müller, and afterwards Kocher, gave accurate accounts of the anatomy of the disease. What is to be thought of reports like the following (a reference to one of Schneider's cases)? "Patient limps, but has no pain. Treatment: resection of the hip-joint. The patient was discharged cured." Cured! What of? Not of the limp, we may be sure; not of the adduction either, unless bony ankylosis ensued, nor of the shortening. Increased mobility may have been obtained, but at the expense of increased weakness and diminished length.

FIG. 7.

From a youth, aged 18 years, the head of whose right femur was about on a level with his great trochanter. The shortening of the limb was almost completely compensated for by increased length of the leg below the knee. There were well-marked symptoms of Coxa vara from the age of 14 years.

The practical question at present is how and where to perform osteotomy. "Kocher, Hofmeister, and others have advised a subtrochanteric osteotomy," writes Frazer. He might have added that subtrochanteric osteotomy had been performed for Coxa vara some years before by myself. It has recently been done and strongly recommended by Watson Cheyne. I removed a wedge. The patient herself was much pleased with the result, mainly because it greatly diminished the shortening. Watson Cheyne directed his attention chiefly to remedying the eversion, and effected great improvement. He used a silver plate and steel pins to fix the fragments in the corrected position. The seat of the deformity being mainly above the trochanter, the obvious indication

would be for supra-trochanteric osteotomy, but for the comparative depth and difficulty of controlling the upper fragment, consisting only of the head and part of the neck, after that operation. It has been recommended by Kraske, whose operation consists of the removal of a wedge from the neck, with the base upwards, through an anterior longitudinal incision. Budinger says that linear supra-trochanteric osteotomy does just as well if the limb be kept well abducted and everted during the after treatment. My experience of osteotomy in general is that if the operator be a practised osteotomist a better result can generally be obtained from a wedge than from a linear osteotomy, except where, as in Macewen's operation for genu valgum, the bone is comparatively deep and slender, and the correction desired very simple. The neck of the femur is deep and slender, but the correction desired is not simple. The abnormally great length of the upper border of the neck of the femur invites strongly to a wedge osteotomy. But it must be remembered that the lower border of the femoral neck is also abnormally short. No operation hitherto performed would cure the shortness, which constitutes a part of the deformity which is of great practical importance. If the problem were merely one of joinery, such a procedure as the following might be adopted. The femur would be divided obliquely, from without inwards and downwards, just above the lesser trochanter. The outer surface of the upper fragment (D, Fig. 8) would be

Fig. 8. Fig. 9.

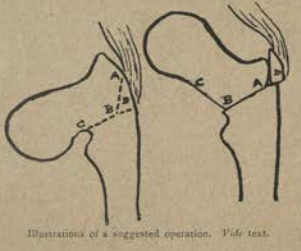

Illustrations of a suggested operation. *Vide* text.

cut off and turned upwards with the muscles, which would be left attached to it. Then the surface A B (Fig. 8) would be brought down into the original position of B C, and fixed there with pins. The result, as shown in Fig. 9, would be to bring back the articular surface of the femoral head almost into its normal position. To make the articular surface look sufficiently forward—*i. e.* to remove the evil effect of the horizontal curve in the femoral neck—a wedge with the convexity forward would also have to be removed from either the lower fragment at B C (Fig. 8) or the upper at A B (Fig. 8). Otherwise the external rotation of the limb would have to be corrected by a separate simple osteotomy, done after the first osteotomy was recovered from. Mere rotation inwards of the limb would disturb the fit of the fragments if done as a part of the first osteotomy. But surgery is not mere joinery, and such an operation as I have sketched out would never be popular with practical surgeons. If carelessly or awkwardly done there would be risk of imperfect fixation and even of splitting the bone in fixing the pins. Nevertheless, the operation is a practicable one, and, properly executed, would almost certainly give a first-class result, better than any got from simple osteotomy. Bold division of soft parts, especially joint-capsule, would be required. Pins are extremely useful in fixing bony fragments after either fracture or osteotomy, but they should never be trusted to alone. They should be properly supported by splints, bandages, and extension apparatus, and the action of these should be carefully superintended. The pins should be of thickly silver-plated steel. The holes for them should be bored by sufficiently large gimlets or American bits, as the insertion by force of pins into small holes will result in splitting the bone. Of course, when the bone is soft and tough, and the pin small in diameter, a bradawl suffices for boring.

Historical.—My chief object in adding a few words under this head is to make a small claim for priority. The position as regards this point was clearly and concisely put by Ernst Müller, of Stuttgart, in the 'Centralblatt für Chirurgie' of September 1st, 1894. His first work on the subject appeared in Bruns's 'Beiträge zur klinischen Chirurgie,' published in November, 1888. He reported therein two cases in which the head, neck, and part of the trochanteric region of the femur had been excised. He gave a very good description of the clinical histories and of the specimens, and expressed the opinion that the affection was of rachitic origin. Afterwards von Lauenstein, Hoffa, Rotter, all in 1890, and later Hofmeister and others, published additional cases and described fresh specimens. Then Kocher, in 1894, published a paper—"Ueber Coxa vara, eine Berufskrankheit der Wachstumperiode"—of the highest intrinsic value, but doing scant justice to Müller and others. Müller wrote in the 'Centralblatt für Chirurgie' of September 1st, 1894, p. 818: "Even if Kocher had not read my work in the original, the others (viz. the papers of Hoffa, Lauenstein, &c.),

which all referred to mine, could not have escaped his observation." And further: "Kocher had, therefore, no right to assert that he published his cases without knowing anything about my work, since otherwise he lays himself open to the reproach of not inspecting (surgical) literature, which is the first thing which an author should do before he describes a new disease." Kocher defended himself with his usual ability, but not, I think, with complete success. He persuaded himself (I think erroneously) that his cases differed essentially from Müller's, and that because they presented at the hip certain analogies with the changes at, and near, the ankle in talipes varus, only cases precisely like his ought to be called "Coxa vara."

I must now point out that Müller himself could scarcely have exhaustively "inspected surgical literature" before publishing, because what, to him at least, should have been obviously a case of Coxa vara was published by me in the first number of the 'Illustrated Medical News' (of date September 29th, 1888). Müller's first publication appeared in the following November. My paper was entitled: "A Case of Rachitis Adolescentium, in which the Disease was for several Years localised in the Trochanteric and Infra-trochanteric Region of the Right Femur, and afterwards attacked the Spine; Wedge Osteotomy for the Femoral Deformity and Plaster-of-Paris Jacket for the Spinal." In the text I wrote of the case that it was "one of *rachitis adolescentium, attacking first the upper epiphysial region of the femur* (see Fig. 1), and, secondly, after some years, the epiphysial regions of the vertebral bodies." A photograph attached shows very plainly the adduction of the hip, the eversion of the foot, the shortening, and the compensatory knock-knee (Fig. 6). My case was the first, therefore, in which the nature and seat of the disease were diagnosed correctly during life and before operation.

There are several reasons why I have not hitherto received credit for this: (1) The next observations were made in Germany; indeed, for some years the literature of the subject was purely German. (2) I did not make the mistake of diagnosing the affection to be one of the hip-joint and then, by excising the upper end of the femur, put myself in a position to give an anatomical description of the specimen. (3) I omitted to give any clinical account of the objective symptoms, and left the photographs to speak for themselves. (4) The art editor of the journal added a misleading diagram "to explain the nature of the *operation*." I pointed out its erroneous nature in the last paragraph of my paper, but in terms rather too mild. Lastly, the journal in question only lived two years; its production was found to be too expensive. It was the largest and most copiously illustrated medical journal of its time. Various Continental and American surgeons have written to me asking for the loan of the journal, but the bound volume in my possession was too cumbrous to send abroad.

Previously to the date of my case, Dr. Monks had given an excellent clinical description of a case which was most likely one of Coxa vara, and he had, moreover, distinctly recognised that the trochanters had risen above their normal level with regard to the heads of the femora. He had, however, believed that the femoral heads were also dislocated, and that the cause of the changes was rheumatoid arthritis. Assuming the case to be one of true Coxa vara, I think Dr. Monks must have been mistaken on these points. Various pathological specimens had also from time to time been preserved or described, but had been supposed to be due to rheumatoid or to inflammatory changes, or to traumatism.

Lastly, the existence of Coxa vara in rachitic children had been long known—indeed, it could be seen in almost every pathological museum of importance. Jenner referred in his lectures to the great frequency with which the upper extremity of the femur is deformed in the rickets of childhood. It was, however, reserved for Ernst Müller to give the first complete description of Coxa vara, and Kocher's paper is so valuable from the exactness and fulness of its anatomical descriptions that, with or without priority, it must always remain a classic. The fullest account in the English language is probably Frazer's in the 'Annals of Surgery' for June, 1899, and the most elaborate in any language is Hofmeister's (*op. cit.*). Whitman, Bayer, Kirmisson, and others have made valuable contributions, and, as well as Frazer, they give references to the literature of the subject.

PLATE A.

COXA VARA IN A YOUNG MAN.

The subject of this was a young man, who was sent to Mr. Hutchinson by Dr. Stocker, of Forest Gate, about two years ago. He subsequently attended repeatedly at the *Polyclinic* for purposes of demonstration, and his case excited great interest.

The following extract from Mr. Hutchinson's "Cases with Comments," published in the 'Polyclinic Journal' for November, 1902, describes the case:—

We have had under observation from time to time several examples of that peculiar condition of loss of the obliquity of the neck of the femur and consequent shortening of the affected limb, to which the name Coxa Vara has, of late years, been applied. A most instructively typical one occurred in a young man, in whom we had opportunities for watching the progress of the disease through its stages. Although long before the term "Coxa vara" was devised I had been well aware that under certain conditions the neck of the femur might be shortened or almost lost, there were certainly some features in this young man's case which were new to me, and which I observed with the greatest interest. Briefly, I may say that without any injury the lad became lame on the right side, and after continuing to go about with a limp for some weeks, he was made to rest at home. There was at this stage some little pain about the hip, and disease of the joint was suspected, but the symptoms were never severe enough to made him keep his bed, and when after a six months' rest he was sent to us, he travelled up from Forest Gate and was able to walk freely. We found him with free movement at the hip joint, but with a limb an inch or more shorter than the other, and distinctly everted. During the next few months he lost all pain, and became able, with a high-heeled boot, to walk almost as well as ever. It is now two years since the beginning of his symptoms, and we have seen him recently and have found him quite recovered. During the last year he has been pursuing his vocation as a clerk in the City without inconvenience. Now the revelation which was made to me by this case was that it is possible for a local process of osteitis, independently of injury and without acute symptoms, to soften the neck of the femur so as to permit of an alteration in its form, and then for consolidation to ensue, the patient remaining throughout, apparently, in good health. In most of the cases which I had previously seen, the patient had been subjected to some violence, so that displacement of the epiphysis might be suspected, or the symptoms had been more severe. In this instance we had no proof of either rickets or scrofula, nor was there any history of rheumatism. It is important to note, however, that the patient's age would permit of there being still some remains of the epiphysial cartilage unossified, and in this structure, not improbably, the changes had been initiated.

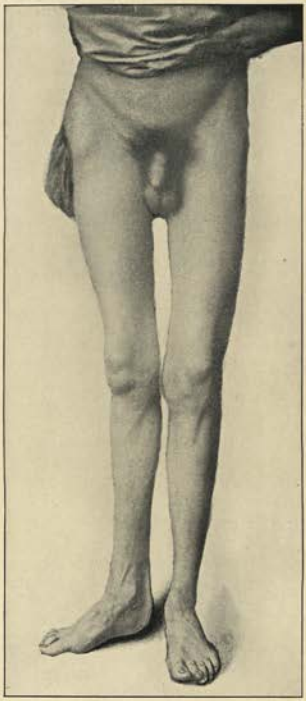

PLATE B.

BACK VIEW OF A SUBJECT OF COXA VARA.

A photograph from the same case as Plate A. It shows well the elevation and projection of the great trochanter, and the resulting hollow behind it.

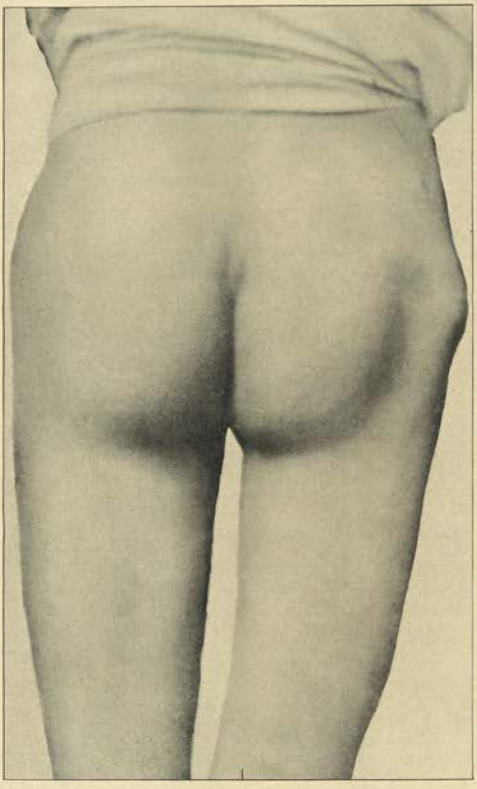

PLATE C.

COXA VARA ON ONE SIDE IN A GIRL.

The subject of this case was a girl, probably about 14 years of age. The radiograph shows in admirable contrast the normal obliquity of the neck of the femur on the left side, and its horizontal and shortened condition on the left. The changes had probably not commenced in very early life, and it is not unlikely that the history of the patient's symptoms, if it were forthcoming, would be found to be very similar to that given in connection with the subject of Plate A.

[From the Jones-Morgan Collection.]

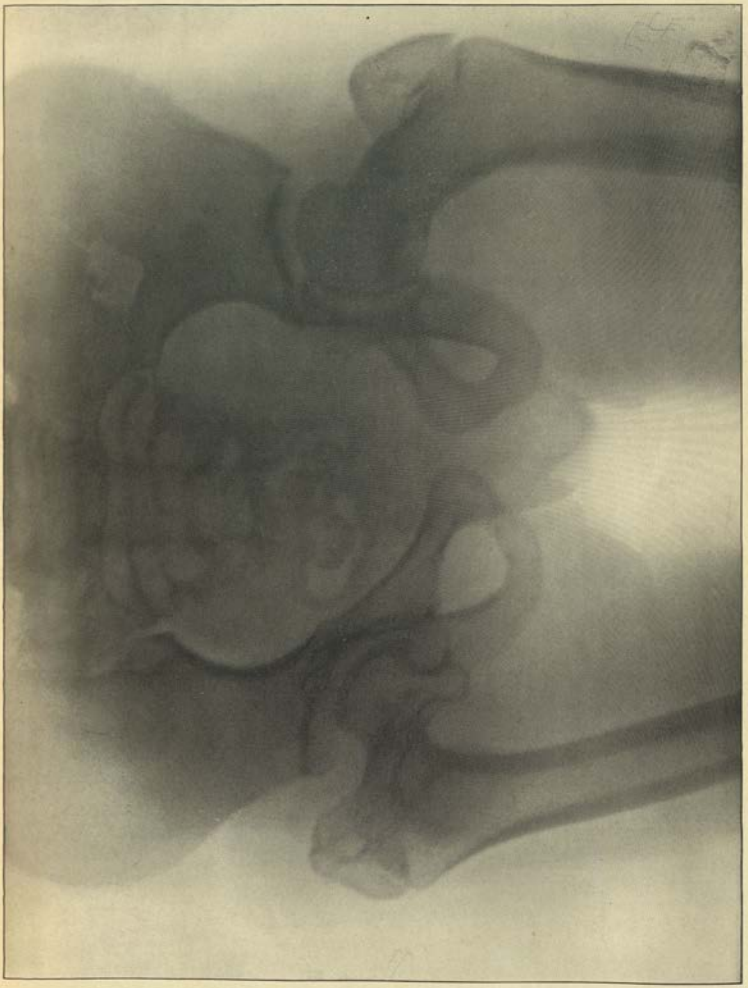

PLATE D.

COXA VARA IN A YOUNG WOMAN.

The subject of this case was a woman of 30, in whom some symptoms had been present for many years (five or more). The right hip only was affected, and on this side the limb was shortened and the trochanter projected. Her trochanter was above Nelaton's line about 1¼ inches, and its neck was at right angles to the shaft. She had external rotation, limited abduction and free adduction. No history or signs of rickets, and no evidence of hip-disease. The radiograph shows the neck of the right femur so much shortened as to be almost obliterated. The lower border of the head almost touches the lesser trochanter. The neck on the other side is normal in size and direction. The case belongs to group II., and had probably a history much like that of the subject of Plate A.

[From the Jones-Morgan Collection.]

PLATE E.

COXA VARA CHIEFLY IN THE LEFT HIP.

The pelvis and hip bones of a well-grown adolescent girl. On the left side especially the neck of the femur has lost its obliquity and become shortened. The great trochanter, which is of large size on both sides, projects upwards very strongly on the left. There is no great evidence of changes at the epiphysial junction, and the shortening of the neck is less than is usual with such definite loss of obliquity.

The conditions imply that the changes did not commence in very early life. It will be seen that the great trochanters are not well ossified. The reputed age of the patient was only 13, but she was of large growth.

[From the Jones-Morgan Collection.]

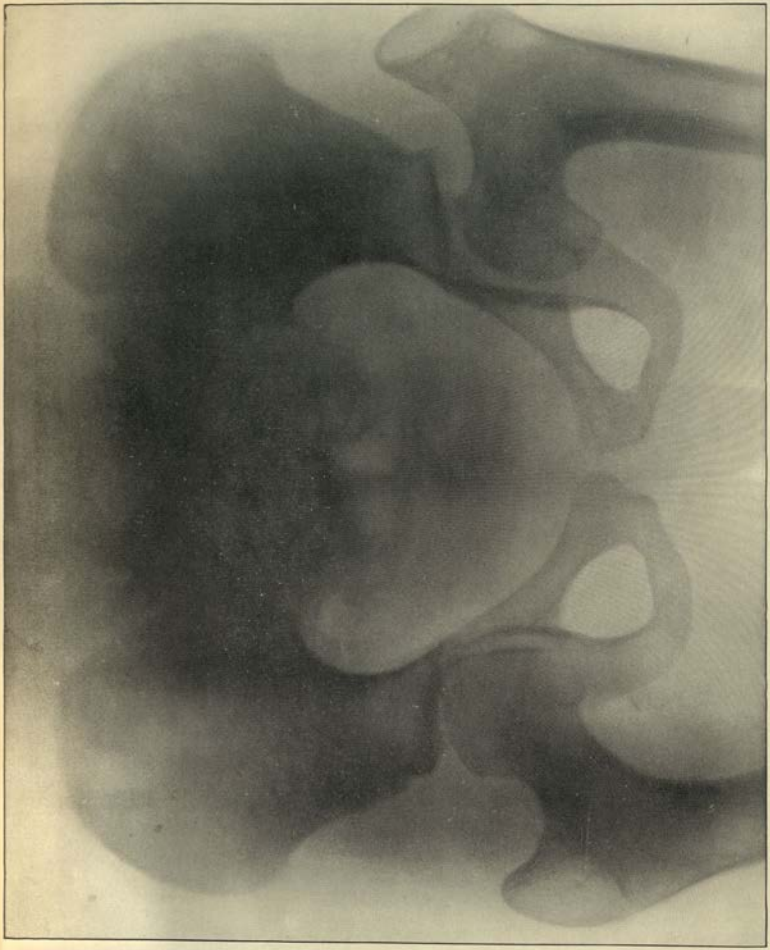

PLATE F.

EARLY STAGE OF COXA VARA IN A YOUNG SUBJECT.

This radiograph is of interest as showing on the left side a long and almost perpendicular neck, whilst on the right the neck is shortened and more nearly horizontal. The altered direction of this latter might, however, almost escape notice, were it not for the opportunity of contrast which is afforded. The patient had for two or three years been noticed to droop on one side, and had experienced pain in the knee after walking. The right trochanter was then three-fourths of an inch above Nelaton's line.

[From the Jones-Morgan Collection.]

PLATE G.

DOUBLE COXA VARA WITH RICKETS IN A CHILD.

The following are Mr. Jones' notes:—

"The girl who was the subject of this case was 7 years of age, and very rachitic. The extremities of all her long bones were enlarged. There was marked genu valgum, with twisting of the lower end of each femur. Her head was typically that of rickets, the ribs were beaded, and Harrison's sulcus was clearly marked. No spinal deformity. The child's gait much resembled that of congenital dislocation of the hips. Separation of the limbs was limited, as also was rotation outwards. The two limbs could not be abducted further than to a right angle with each other. The legs measured of equal length, but on both sides the great trochanter was an inch above Nelaton's line."

On both sides the obliquity of the neck of the femur has been lost, and the neck itself much shortened. The changes had, no doubt, commenced early in life.

[From the Jones-Morgan Collection.]

PLATE H.

COXA VARA IN A YOUNG RACHITIC CHILD.

Mr. Jones' notes state that the subject of this case was a boy, aged 4. He had lordosis with prominent hips and unequal elevation of the great trochanters above Nelaton's line. Mr. Jones regarded the case as a typical one of bilateral infantile Coxa Vara. There was some bossing of the parietal and occipital eminences, some inturning of the molar teeth, and the child suffered from night sweats. These were the only indications of rickets. One limb was flexed at 38°, and the other at 45°. There was outward rotation of both limbs with free adduction, but only very limited abduction.

All the bones show retarded ossifications. In the great trochanters there is but a wafer-like disc of bone. The acetabula cannot be traced, and the heads of the femora are represented by ossified centres not bigger than half cherries, and placed down on the inner aspect of the shaft. The neck of the bone is almost wholly lost. The femora slant towards each other. It is obvious that such great changes at this early period of life must result in great deformity.

[From the Jones-Morgan Collection.]

PLATE I.

AN UNUSUAL CASE OF COXA VARA.

The following particulars are transcribed from Mr. Jones' notes:—

A woman, 26 years old, walked into the out-patient department of the Royal Southern Hospital. I remarked to a few who were with me: "This is evidently a case of congenital dislocation." It was noted, however, that the wobbling was not so pronounced as is usual in cases of congenital type, and I am indebted to Dr. Honer Bone for some very careful measurements and notes. The patient was a strong-looking woman, who walked with some wobbling. Her spine and pelvis exhibited marked lordosis.

She began to walk at 2 years old, and even then a wobbling gait was noticed. When 11 years old she was said to have hip-disease, and for 11 months she wore a Thomas's hip-splint on the left limb. She still complained of pain, which was getting worse. Both her hips were prominent, especially the left.

The right trochanter was 2 inches above Nelaton's line; the left 2½.

The length of the limbs as measured from the umbilicus was equal.

The measurement from the anterior spine to heel gave the right limb half an inch longer than the left.

The flexion angle on either side was sixty degrees. Neither limbs could be flexed on to the abdomen beyond a right angle.

Abduction of either limb was very slight. The tip of the internal condyle could be abducted from middle line 2½ inches; the left two inches.

Adduction was more free. The limbs could be adducted so that the under surface of either knee can be made to rest on the opposite patella. This was the position most comfortable to the patient, and she was accustomed to rest first one limb on the top and then the other.

It will be seen that the yielding appears to have occurred at the junction of the head with neck, and to have effected an extreme degree of change in the relative position of the parts. The lower border of the head is brought almost in apposition with the side of the shaft. Although the patient was of adult age, only a narrow bar of bone connects (on the right side) the head with the neck.

[From the Jones-Morgan Collection.]

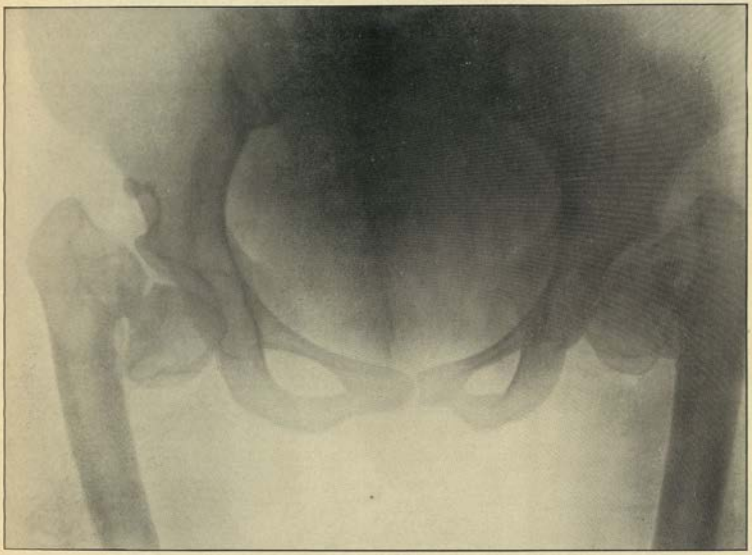

MISCELLANEOUS.

PLATE J.

UNUNITED FRACTURE OF SURGICAL NECK OF HUMERUS.

MR. F. MACKENZIE.

PLATE K.

REMARKABLE DISPLACEMENT OF BONES AT ELBOW-JOINT FROM DISEASE IN CONNECTION WITH INHERITED SYPHILIS.

MR. J. HUTCHINSON.

PLATE L.

MULTIPLE CARCINOMATA OF SKIN.

DR. ALLWORTHY & MR. PERNET.

PLATE J.

UNUNITED FRACTURE OF THE SURGICAL NECK OF THE HUMERUS.

This radiograph is copied from an original, which was taken by Mr. F. M. Mackenzie, of Sloane Square, under whose care the patient was. It represents the state of the parts in an ununited fracture of the surgical neck of the humerus in a lady about 65 years of age. The fracture was caused by a fall, and had occurred two years before the radiograph was taken. The usual symptoms were present at the time of the accident, and the usual treatment by splints and complete immobilisation was followed out. No union, however, resulted. The patient regained good use of the arm with, as is shown, a false joint, in which the upper end of the humerus plays in a hollow in the under surface of the head. It is now three years since the radiograph was taken, and the conditions remain unchanged. It is of great interest to record that the subject of this case had had her left breast removed by Mr. Hutchinson on account of cancer. This was twelve years before the fall in which the bone was broken, and she was at that time free from any indications of recurrence. Since the fracture, however, now five years ago, there have been developments of cancer in the axilla, and other operations have been required. There is, however, not the slightest reason to believe that either the fracture or the non-union was due to the presence of cancerous growth in the bone.

PLATE K.

DISEASE OF ELBOW-JOINT, WITH REMARKABLE DISPLACEMENT OF BONES IN A CASE OF INHERITED SYPHILIS.

The following narrative, by Mr. Hutchinson, is reprinted from the pages of the 'Polyclinic Journal' (May 1900). It gives the facts as to the case which is here illustrated. The radiograph shows the deformed and almost pointed extremity of the humerus projecting below the bones of the forearm, which are displaced so as to rest against the front and side of its lower third. The end of the humerus has lost its articular portion and condyles, and is almost pointed. The head of the radius is much enlarged.

"Very remarkable deformities of the elbow-joint sometimes occur in connection with inherited syphilis. I have seen several of these, and have recorded them, and although I cannot say that I have ever been able to prove their connection with epiphysitis, yet the suggestion that they are so is very probable. An inflammation of the lower part of the shaft of a long bone, involving its epiphysis, and occurring at an early period of life, may be supposed very likely to result in arrest of growth and great modifications of form. Whether this suggestion is adequate in the instance of the patient of whose elbow I now show you a skiagraph, it is difficult to say. The diagnosis as regards the patient's inheritance is not quite free from uncertainity. The condition of the elbow is one of the most extraordinary that I have ever seen.

"It is the right elbow which presents the conditions which I have to describe. A blunt end of bone projects below, and is at first mistaken for the olecranon, but on examination the latter is found to be two inches above it, resting against the outer side of the humerus, the end of which (the projection mentioned) is all that remains. The end of the radius, in apposition with the ulna, and of course yet more superficial, is easily visible in almost its whole extent. It still rotates freely, and with its companion bone moves within certain limits of flexion and extension. It is not in apposition with any part of the humerus. Thus we have a dislocation of both bones upwards on the side of the shaft of the humerus, the latter having undergone extraordinary modifications in form. The elbow is very thin, and the bones are covered only by a thin white scar, which extends for a considerable distance above and below what remains of the joint.

"There is no history of any injury. The statement is that disease occurred in the joint at the age of 10 or 11; that portions of bone came away; that the limb was in splints for a year; that amputation was proposed, and was only averted by a consultation with Sir James Paget. The ulceration of the skin must have been of a lupoid character and very extensive to have left so large and such an abruptly margined scar. The question is, Was the disease struma or congenital syphilis? and it is not one easy to answer. Miss W. is now 40 years of age, and she comes attended by a sister two years older than herself.

"Both sisters bear traces of having suffered severely from symmetrical inflammation of their corneæ. The conditions, although suspicious, are, however, not quite characteristic, and are such as might possibly have been caused by ulceration. The central opacities have not wholly cleared, and very marked arcus senilis (an unusual condition in middle-aged women) prevents any critical examination of the margin. Neither of the sisters had a characteristic physiognomy, and both have lost their upper front teeth, and are wearing artificial ones. Both of them are deaf, the younger one very much so, but then there is the history of otorrhœa after scarlet fever. They have lost their parents, and no history of infancy is obtainable. Their two younger sisters both died of pulmonary phthisis. The younger of these two suffers from ozœna, and her soft palate on the right side is adherent to the posterior pharynx, evidently as the result of ulceration. Thus there are a number of items of evidence, which, taken together, make it very probable that the disease of the elbow was really due to inherited taint.

"In connection with the absence of anchylosis in this case, we must remember that it is a peculiarity of syphilitic epiphysial disease that the bones may suffer very severely whilst the joint remains intact. Thus, with very extensive destruction of bone, there may be no anchylosis. This escape can scarcely take place in strumous disease, in which almost invariably the cartilages suffer. I do not think that there can be much doubt that the disease was due to inherited syphilis."

(Plate L., continued.)

a dull red or livid colour, and the larger more of a pale yellowish tint. All were quite devoid of sensibility, and some firm to the touch, whilst others had softened in the centre, leaving a crater-like formation, with a thin ichorous discharge.

The glands of the right inguinal region were greatly enlarged, with the skin tightened over them; so much so that I quite anticipated suppuration.

On removing one or two of the growths for microscopic examination, I found that the blood supply was copious, and experienced some difficulty in stopping the hæmorrhage. Subsequently the parts healed well, leaving only a small raised scar, darker in colour than the surrounding skin.

When any of the growths disappeared, whether from the use of the knife or from their own degeneration, one or two new nodules invariably made their appearance within half an inch of the old cicatrices; some grew slowly and remained firm, whilst others attained their full size in two to four months. During the past eight months five matured and disappeared, and those that grew most rapidly softened and degenerated sooner than those of slower growth. The photograph represents the condition on the 6th March, 1900. The two larger tumours on the upper and left-hand side were removed by me and sent to Mr. Pernet, who kindly undertook their examination. With regard to treatment, the diseased part was carefully kept clean by the use of a carbolic lotion, and resorcin ointment was applied. Sulpho-carbolate of soda was given internally, afterwards iodide of potash. At first a great improvement in the general health of my patient took place, his colour improved, and the inguinal glands became very much smaller, but this I think, was in great part due to the effect of the lotion in cleansing the growths and preventing absorption. At present he is taking iron and arsenic, and although extremely anæmic is able to walk a considerable distance each day, and has not apparently lost strength during the past three months."

Histological Notes, by Mr. George Pernet.

"The tumours sent to me by Dr. Allworthy were as large as Tangerine oranges. Their general appearance is well shown in the photograph. The growths spread mushroom-like well beyond their base of attachment, and in places had broken through the epidermis.

Macroscopical.—On section the tumours were found to be made up of spheroidal, individual growths, which had in some instances apparently coalesced. The larger were soft, composed of a brownish red pulp; the smaller were white and firmer, but they were well defined, and, as it were, encapsuled by the limiting tissues, except, of course, at those points where the growths had broken through. A well-marked peripheral zone of pigmentation was present in some.

Microscopical.—A very small early growth would have been more adapted for microscopical examination, but, as this was not forthcoming, portions of the large growths were cut in celloidin, and sections stained by various methods:—1. Delafield's Hæmatoxylin; 2. Polychrome methyl. blue; 3. Polychrome methyl. blue and neutral orcein; 4. Acid orcein.

The skin showed marked infiltration by a new growth, in well-defined masses, limited, and, as it were, encapsuled, by the surrounding connective tissue, and separated from the epidermis, except where the latter had become involved and destroyed by the growth breaking through to the exterior.

The masses were made up of numerous cells arranged in rows and alveoli, very suggestive of a glandular growth from the sweat coils and ducts. The cells themselves were more or less polygonal, darkly stained and nucleated, and practically of the same size as the cells of the epithelium. In some instances there was a more or less complete narrow zone of pigment at the periphery of the masses. In the central parts of the larger masses, breaking down and liquefaction had occurred. As to the connective-tissue cells, they were not more numerous than is normally the case. Mast-cells were present, but not in any great number.

The blood vessels were in some parts markedly dilated, but there was not much evidence of inflammation anywhere.

Taking all the facts, the case must be considered as one of multiple alveolar carcinoma of the skin, possibly originating from the sweat apparatus."

PLATE L.

MULTIPLE ALVEOLAR ? CARCINOMA OF SKIN.

The case, the progress of which is displayed in the appended plate, may suitably be allowed for the present to stand alone as an example of a very exceptional form of malignant disease of the skin. The case was recorded in detail by Dr. S. W. Allworthy, of Belfast, in the 'Transactions of the Dermatological Society of Great Britain and Ireland,' vol. vi. The histological examination was by Mr. George Pernet. We are indebted to both these gentlemen and to the Council of the Society for permission to reproduce the illustrations. The photographs were supplied by Dr. Allworthy.

Subsequent to the history as given in the following notes, the patient became cachectic, and gland tumours developed. Death occurred about a year after the last photograph was taken.

Clinical Account, by Dr. S. W. Allworthy.

"My record of this case is imperfect with regard to the early phases of the disease, but as my patient is thoroughly intelligent, his own description may be accepted as fairly correct. The photographs which I have taken include the entire lesion, and give an accurate record of the position on the body as first seen by me on the 10th July 1899, and again the condition presented on the 6th March, 1900.

A. D., aged 55 years, 5 ft. 4 in. in height, weight 9½ stones, first came under my observation in the extern department of the Belfast Hospital for Diseases of the Skin on the 10th July, 1899. He said that for about eighteen months he had been suffering from a number of tumours on his 'right buttock,' some of which had disappeared, whilst others 'kept growing to take their place,' and occasionally he had resorted to cutting one off with his penknife when it inconvenienced or annoyed him too much. Especially was he driven to do this by a disagreeable and intensely fœtid discharge mixed with a considerable quantity of blood which came from some of the tumours after they had softened and burst. He also stated that about twelve months previous to the appearance of the larger growths he had detected, 'when at stool,' on passing his hand over the part, a small raised portion about the size of a shilling, but that he had experienced no discomfort from itching or otherwise, and, indeed, would not have noticed its existence had not his hand made the discovery. This little patch eventually became slightly moist, and then others developed. Even afterwards he had very little pain, and only persuaded himself of the advisability of seeking medical advice, when owing to failing strength he could no longer follow his employment. There is nothing specially noteworthy in his history.

His father and mother were 78 and 79 years of age respectively when they died. He had three brothers and three sisters, and as far as his knowledge goes there never was a case of cancer or skin disease in the family.

He married when twenty-seven years of age, and has been a widower eleven years. His family consisted of eight children—four died in infancy, and four daughters now living are quite healthy.

With the exception of two weeks due to an attack of pleurisy, when about seventeen years old, he does not remember being unfit to work for a single day till he began to suffer from the present malady. He seems to have led a very simple and regular life, neither drinking nor smoking, and never suffered from syphilis or any skin trouble. Until the year 1888 he lived in the country, and worked as a hand-loom weaver; since then he has been in Belfast engaged as a labourer in one of the linen mills. When I first saw him he was more or less emaciated, and his face had all the appearance of one suffering in an advanced stage of cancer, with the usual cachexia. The stench from his body was almost unbearable, owing to the fact that the diseased surface was not cleansed or treated in any way. His skin was dry, but otherwise healthy, with the exception of some thickening between the growths. His pulse rate was 100, and his tongue furred. However, he simply complained of feeling unfit for work, and thought the tumours were probably the cause. There were about thirty tumours, varying from the size of a small bean to that of a good-sized tomato, the smaller ones being of

PLATE XCVIII.

FUNGATING (FRAMBŒSIFORM) CHANCRES FROM TATOOING.

These three figures are here placed together in order to illustrate the peculiar features often assumed by primary syphilitic sores when occurring on the naked skin. In each instance the virus had been introduced in the course of tatooing. It will be seen that in all a little raspberry-like mass of granulation tissue has been developed on an indurated base.

Figures 1 and 2 are from photographs supplied by Dr. Thelwall Thomas.

FIG. 1.—The patient, Samuel B., æt. 23, was tatooed on January 4th, 1898, and came under Dr. Thomas's observation on April 5th; that is, three months later. The statement was that two red pimples had developed one month after the tatooing. In the process of tatooing the operator had moistened the arm with his saliva, and then pricked in the pigment with needles. On April 5th the conditions were as shown. There was induration at the base of the sore, and the glands in the axilla were much enlarged. There was no secondary rash or sore throat.

FIG. 2.—In Dr. Thomas's second case the tatooing was done on March 12th, 1898, the patient being a man aged 22. The sore was first noticed on April the 11th, the thirtieth day. The photograph was taken on April 24th, at which time there were enlarged glands in the arm-pit, some sore throat, but no eruption. The patient was sent to Dr. Thomas by Dr. O'Hagan. The tatooer, a travelling showman, had communicated syphilis in this way to at least four men.

FIG. 3 has already been given in a former Fasciculus, but is here reproduced in order to place it in juxta-position with the two preceding. It is from a photograph given to Mr. Hutchinson by Dr. Crossley Wright, of Halifax.

Very similar conditions of granulation growth on a vaccination chancre are shown in Plate XXIII. of 'Illustrations of Clinical Surgery.'

FIG. 1.

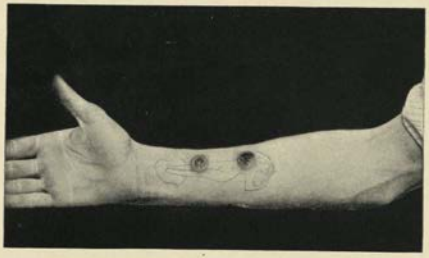

FIG. 2.

FIG. 3.

PLATE XCIX.

FUNGATING GROWTHS OF MELANOTIC SARCOMA ON THE PALM AND SOLE.
(From Photographs supplied by Dr. Thelwall Thomas.)

Fig. 1.—A photograph showing a fungating growth of melanotic Sarcoma in the palm of the hand. The patient was a man aged 63, who was under the care of Dr. Thelwall Thomas in May, 1894. There were nodules on the lymphatic trunks extending up the arm, and the axillary glands were enlarged.

Fig. 2.—From a photograph done for Dr. Thelwall Thomas, showing a fungating growth of melanotic Sarcoma on the sole of the foot. The glands in the groin were enlarged. The patient was an old woman of 70, and was under observation in December of 1898. The structure is described as that of a spindle-celled Sarcoma.

It may be remarked that melanotic sarcomatous growths occurring in the thick skin of the palm and sole appear to show a remarkable tendency to remain somewhat constricted at the base, and to fungate. These illustrations show well the features usually assumed by them. In the Clinical Museum at the Polyclinic there are a number of portraits which show precisely similar conditions.

FIG. 1.

FIG. 2.

XANTHOMA AND XANTHELASMA.

CONTINUED FROM FASCICULUS XV.
(OR III., IV. OF NEW SERIES.)

PLATES 100, 101, 102, 103, 104, and 105.

PLATE C. (100.)

XANTHELASMA PALPEBRARUM.

FIG. 1, in rather an exaggerated form, shows the yellow patches of Xanthelasma palpebrarum in their usual positions curving round the inner canthus. They are symmetrically placed, but were of older date, and are of larger size on the left side. At the outer canthus, again symmetrically placed, are two small yellow spots. This is the usual position in which Xanthelasma of the eyelids next appears after the patches round the inner canthus have become well developed. Sometimes, as in Plate XCVI., the whole of both eyelid regions is involved. This seldom occurs, excepting in cases in which the Xanthoma is associated with jaundice. The cases, however, are not very infrequent in which, like the one here illustrated, the naso-canthus region is involved, and some small patches are seen at the outer canthus. Unless there be actual jaundice, the whole of the palpebral integument is scarcely ever involved.

FIG. 2 shows the Xanthelasma regions of the eyelids occupied, not by solid yellow patches, but by symmetrically placed serous cysts. These cysts contained a clear fluid resembling sweat, and were probably developed in connection with obstructed sudoriferous ducts. At the base of some of these cysts, especially the upper ones, there was a small amount of yellow solid growth. Very few cases of this sudoriferous form of Xanthelasma have been placed on record, and this portrait is from one of the most marked of them. In one other there were little cysts at the outer canthi as well. All the cases have been attended by severe symptoms of functional liver disturbance, precisely such as those met with in ordinary Xanthelasma palpebrarum.

FIG. 3 shows symmetrically placed patches of Xanthelasma on the upper part of the Xanthelasma region. This is the ordinary form, and the patches are in the position usually affected earliest. The patches are, however, somewhat more abruptly margined than is usually seen, and the appearance of elevation is too definite.

FIG. 1.

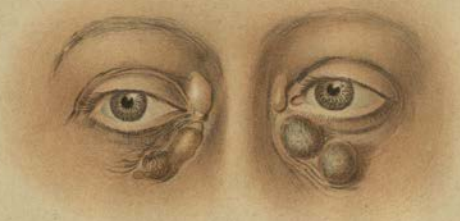

FIG. 2.

FIG. 3.

PLATE CI.

XANTHOMA DIABETICORUM.

FIG. 1 shows the palm of the hand with yellow bars of Xanthoma growth crossing the digits, and especially marked in the lines of flexure. In the palm, however, there is a diffuse yellow discoloration, but no material thickening.

FIG. 2 is a study of the eruption in a marked case of Xanthoma diabeticorum. The discrete arrangement of the yellow papules, and the mode in which they coalesce and form irregular patches, is well shown. It may be compared with several portraits given in Fasciculus XV.

FIG. 1.

FIG. 2.

PLATE CII.

XANTHOMA STREAKS AND PATCHES IN THE PALM OF THE HAND IN ASSOCIATION WITH PERSISTING JAUNDICE.

FIG. 1 shows the arrangement of Xanthoma streaks and patches in the palm of the hand, and may be compared with the previous Plate. It will be seen that the lines of flexure on the palm are specially affected, but this is not marked on the digits, where the condition is more diffuse. The portraits were taken from a woman who was the subject of deep jaundice and had been so for some years. She had Xanthoma patches surrounding the eyes and covering both eyelids, and patches on other parts of the body. Dr. Abercrombie's patient. See Plates XCVI. and XCVII.

XANTHOMA IN EXCEPTIONAL POSITIONS IN ASSOCIATION WITH THE SAME ON THE EYELIDS.

FIG. 2 is from an exceptional case in which the patient was the subject of gout, both inherited and acquired. He was liable also to liver disturbance, and had had jaundice. He had numerous subcutaneous tumours, and around some of these the characteristic yellow growth of Xanthoma occurred. The case is published in the twenty-second volume of the Clinical Society's 'Transactions,' page 241.

The patient was a Jew, aged 44, of dark complexion. His father and grandmother (paternal) had been the subjects of Xanthelasma of the eyelids. He himself had conspicuous patches in the usual positions on both sides. He stated that they had followed an attack of jaundice eighteen years before. The swelling, which is represented in the portrait, was firm and painless. It adhered to the skin but was not inflamed, and caused no pain. All around its base on the furrow which was caused by its overlapping were a number of little streaks of Xanthoma growth. The patient had fusiform enlargements in many of his tendons. In a corresponding position on the other elbow there was an induration, ill-defined, under the skin, which was surrounded by a lip of bone developed from the ulna. This induration presented none of the features of a bursa. These tumours and also the indurations of his tendons were probably in association with his gout. He continued to enjoy fairly good health.

Fig. 1.

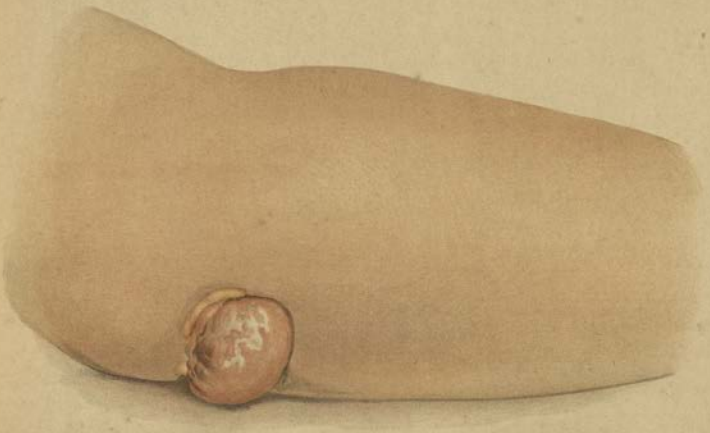

Fig. 2.

PLATE CIII.

THE COMEDONOUS FORM OF XANTHOMA.

Fig. 1 in this Plate is copied from an oil painting in the Clinical Museum. The patient was an old woman, an inmate of a Yorkshire workhouse. The condition shown is that of grouped comedones occupying the Xanthelasma positions, and placed quite symmetrically. In each instance the principal group is on the upper eyelid, but smaller ones extend downwards, curving round the inner canthus. There is no proof of the presence of any yellow Xanthoma growth; but the patient had had liver disturbance, and the positions occupied sufficiently indicate an association with more ordinary forms of Xanthelasma.

Fig. 2.—The portrait of a young girl who attended at one of the consultations at the Polyclinic. A group consisting of ten little sebaceous accumulations is seen occupying the Xanthelasma position of her left eye. She was not specially out of health. The lowest spot in the group shows the blackened end of a comedo. In the others the contents of the little cysts were not exposed, the condition being that usually known as milium.

It is the position and the grouping of the spots which imply relationship with Xanthelasma. The girl had not suffered from any special form of illness. A portrait closely resembling this will be found in Dr. Radcliffe Crocker's 'Atlas.'

Fig. 2.

Fig. 1.

PLATE CIV.

ARSENICAL KERATOSIS. XANTHOMA IN A CHILD.

FIG. 1.—Section of the skin from a case of arsenical keratosis. It is copied from an instructive paper by Dr. Giletti, of Turin. Fig. 2, Plate CVII., shows the condition of the hand from which it was taken. The chief feature of interest is the proof afforded that this form of keratosis consists of over-development of epidermal structures, and that there is no hypertrophy of the papillæ.

FIGS. 2 and 3 are from a case of Xanthoma in a young child. The patient was a girl in good health, who was sent to Mr. Hutchinson by Mr. Cadge, of Norwich. Patches of Xanthoma occurred symmetrically on the backs of the elbows, fronts of the knees, and over the Achilles tendon and the back of each ankle. In this case the features conformed exactly to what has been observed in other instances. It will be seen that the spots on the knee begin in the first instance as discrete papules, but they have a tendency to become confluent where they touch.



Fig. I.

Fig. II.

Fig. III.

PLATE CV.

COMEDONOUS XANTHELASMA.

Figs. 1 and 2 show little yellow buttons in the Xanthelasma positions of the eyelids, some of them exhibiting the blackened point so frequently characteristic of a comedo, but some of them without it. In all the condition was an accumulation of very yellow sebum beneath a thin layer of epidermis. There was very little evidence in Fig. 2 of the presence of true Xanthelasma growth, and none whatever in Fig. 1. It is not uncommon in these cases of comedonous Xanthelasma to find in connection with the sebaceous accumulations some true Xanthelasma growth. It is, however, for the most part, the position and the arrangement of the comedones which implies relationship to Xanthelasma.

Fig. 3 shows symmetrical groups of comedones slanting downwards and outwards from the inner canthus of each eye. They are symmetrically placed, and so closely grouped as to involve and partially disorganize the whole of the skin. On the left side there are a few comedones on the upper eyelid, and on both a few are seen near to the outer canthus. The patient was a middle-aged man, who had suffered from bilious attacks, but who had no other form of Xanthoma. The patches had been present several years.

Fig. I.

Fig. II.

Fig. III.

DISORDERS OF THE SKIN INDUCED BY ARSENIC.

(PLATES 107 to 117.)

ARSENICAL PIGMENTATION.

PLATES 109, 110, 112, 113, 114, 115, 116, and 117.

ARSENICAL KERATOSIS.

PLATES 106, 107, 108, 109, 111, 112, 115, 117.

ARSENICAL CANCER.

PLATES 107, 112, 113, 114.

PLATE CVI.

KERATOSIS OF THE PALMS AND EPITHELIAL CANCER FROM ARSENIC.

The figures in this Plate show the palmar and dorsal aspects of the left hand in a man who had suffered from chronic psoriasis, had taken much arsenic, and who finally became the subject of arsenical cancer. Some patches of psoriasis are seen still remaining about the wrist, but on the hands peculiar conditions of keratosis have been developed. The condition of the right hand in the same patient is shown in the next Plate, CVII. It will be seen that a number of dry warty excrescences have formed both on the palm and dorsal surface of the hand; with them there was also a dry harsh condition of the skin generally. These growths were new, and were not parts of the original psoriasis. In some places they resembled corns which had become broken up and become ragged. The patient was a man past middle age, and on whose right hand one of the patches had assumed malignant conditions necessitating amputation of the finger. *(See next Plate.)*

Fig. I.

Fig. II.

PLATE CVII.

KERATOSIS AND CANCER FROM THE USE OF ARSENIC.

FIG. 1 in this Plate is from the same case as the two in the preceding one. The forefinger had been amputated two years before this portrait was taken, and in the middle of the scar of the operation it will be seen that a deep fissure with keratosis and breaking up of epidermis on both sides had occurred. For this another amputation was subsequently performed. The microscope declared the conditions to be characteristic of epithelial cancer. In the meantime the patient had had a malignant growth twice excised from his right shoulder.

FIG. 2 shows the condition of the palm of the hand in the case to which the microscopic section given in Plate CIV. belongs. The case was published by Dr. Giletti, of Turin, as an example of keratosis following the use of arsenic. The drug had been suspended for some time before the portrait was taken, and the conditions persisted afterwards. The soles of the feet were in a similar state.

Fig. I.

Fig. II.

PLATE CVIII.

KERATOSIS OF THE PALMS FROM THE MEDICINAL USE OF ARSENIC.

In this illustration we have shown a condition of diffuse keratosis of the whole of the palmar aspect of the hand, produced by the use of arsenic in full medicinal doses. The patient had no skin disease whatever until the arsenic was given. The drug was prescribed in the hope of checking a large malignant growth in connection with the tonsil. It was pushed to the extent of twelve minims three times a day, when it caused a general muddy discolouration of the skin associated with dryness of the palms and soles, together with keratosis in certain positions. There could be no question whatever that the changes shown were caused by the arsenic.

In the next Plate keratosis is shown in patches over the knuckles and the backs of the pharyngeal joints; and in the next is seen a patch of keratosis almost resembling psoriasis on the outer side of one elbow. The case ended in death about six months after these portraits were taken, the fatal event being caused by the continued growth of the original tumour. The arsenic was of course suspended when these keratosis conditions were produced, and some slight amelioration of their condition was observed before the patient died. The arsenic had manifested disagreement by causing nausea and loss of appetite. The patient had lost flesh, but this might have been due to his original disease. He was under the joint observation of Sir James Paget, Sir Hermann Weber, and Mr. Hutchinson. His case is recorded in the Pathological Transactions. It is one of the most instructive that have been published in proof of the power of arsenic to modify the nutrition of the skin, and to produce conditions of keratosis, together with those resembling psoriasis.

FIG. 1.

FIG. 2.

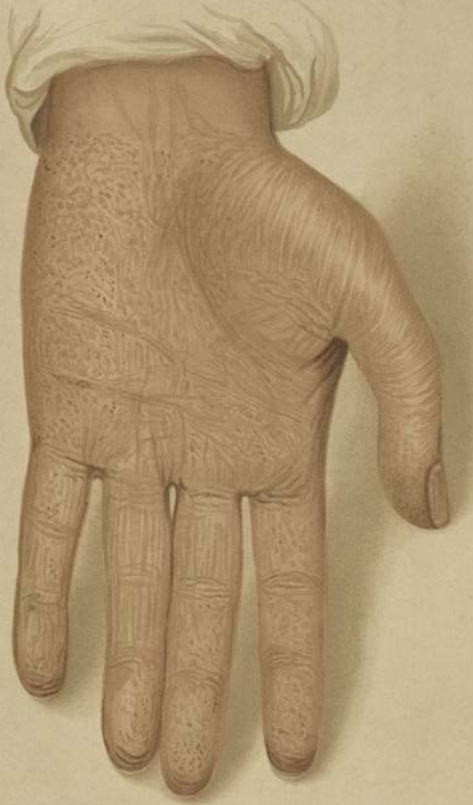

Bale & Danielsson, Ltd., London.

PLATE CIX.

CONDITIONS RESEMBLING PSORIASIS FROM THE MEDICINAL USE OF ARSENIC.

The back of the right hand in a patient whose case is described in connection with the preceding Plate. Large thick accumulations of epidermis are seen over the knuckles and over the backs of the phalangeal joints. Although looking somewhat like psoriasis, they differed from the conditions characteristic of that disease in that the accumulations did not consist of silvery scales, and that they could not be detached. They were firmly adherent, and were made up of thickened epidermis. A number of little pits will be seen on various parts of the skin. The conditions were quite symmetrical on the two hands.

LIBRARY OF THE BOMBAY BRANCH OF THE ROYAL ASIATIC SOCIETY

Hale & Danielsson, Ltd., London.

PLATE CX.

CONDITIONS RESEMBLING PSORIASIS FROM THE MEDICINAL USE OF ARSENIC.

This Plate, taken from the same subject as the two preceding, shows a patch of keratosis on the outer side of the elbow. There was a similar patch on the other elbow. The remarks as to the distinctive features in this condition and that of true psoriasis, which were made on the preceding Plate, apply also to this.

Bale & Danielsson, Ltd., London.

PLATE CXI.

ARSENICAL KERATOSIS OF PALMS AND SOLES.

The three figures given in this Plate are copied from a paper on "Symmetrical Kerato-Dermatitis of the Palms and Soles" after the use of arsenic, published by Dr. Giletti, of Turin. Figures 1 and 3 have, by an inadvertence in giving out the originals to the lithographers, been already placed in Plates CIV. and CVII. Figure 1 shows the palm of the hand covered with little corneous excrescences, which extend from the tips of the digits to the wrist, and figure 2 shows similar conditions in the sole of the foot. The artistic delineation is not sufficiently detailed, but there can be no doubt that the conditions represented are identical with those shown in Plates CVI., CVII., and CVIII. Figure 3 gives us an excellent representation of the microscopic structure of the affected skin, and is of especial value, because it is possibly the only one which has as yet been published. It shows that the changes are in the epidermal layer only, and that the papillæ are not affected. The accumulations are not warts, but corns. This is in conformity with what is shown in Plates CX. and CXI., where patches, obviously epidermic accumulations, and much resembling some forms of psoriasis, resulted from the use of arsenic.

Dr. Giletti's patient was a man in good health, aged 23, who had suffered from an eruption which had been diagnosed as urticaria, and which had followed typhoid fever. For this Fowler's solution was prescribed in 1889. It was taken continuously up to March, 1893, when he came under Dr. Giletti's observation, presenting the conditions shown in the Plate. At this date the arsenic was disused, but the conditions continued rather to increase during the next two or three months, and after that remained *in statu quo* for a year or more.

On account of the persistence of the keratosis after leaving off the arsenic, Dr. Giletti felt some hesitation in attributing the changes to the drug. We cannot, however, feel any doubt on this point, for persistence, or even aggression, after such disuse, has been observed in other cases. So far, indeed, from the processes, once begun, being promptly arrested on giving up the drug, there is still much fear that epithelial cancer may supervene.

Fig. 1.

Fig. 2.

Fig. 3.

Bell & Daldiesen, Ltd., London.

PLATE CXII.

KERATOSIS OF PALMS FROM ARSENIC FINALLY RESULTING IN EPITHELIAL CANCER.

This Plate illustrates the condition of the two hands in a man who had taken arsenic during the greater part of his life in order to alleviate the conditions produced by an inveterate psoriasis. For many years his hands had been quite unaffected, but finally patches of keratosis occurred in his palms, and these progressed into epitheliomatous ulcerations. His case has been fully described by Mr. Hutchinson in the Pathological Transactions, and has also been the subject of careful comment by Dr. White, of Boston, U.S., under whose observation the patient originally was. The ulcerated growth shown in Fig. 1 on the front of the right wrist had been repeatedly scraped and excised, but the growth always recurred. Amputation was ultimately done through the forearm, but the glands in the armpit became affected, and the patient died. At the autopsy, growths were found in connection with the ribs and pleura. In Fig. 2 a similar condition of growth and ulceration is shown just below the cleft of the index and middle fingers. For this also amputation of the digits concerned was performed.

Attention is requested to the skin on the other parts of the palm, and if this be compared with that shown in Plate CVIII. there will be no difficulty in recognising the sameness of character in the two. In Plate CVIII. there is no doubt whatever that it was the result solely of the use of arsenic.

Fig. 1.

Fig. 2.

Hale & Iconistoun, Lith. London.

PLATE CXIII.

EPITHELIAL CANCER FROM ARSENIC WITH GLAND IMPLICATON.

This Plate, with the two that follow, belong to, and illustrate, a case in which a patient who had taken arsenic for several years for psoriasis finally became the subject of cancer. A cancerous ulcer is shown in the pubic region, the edges of which are everted and sinuous, but unattended by any large amount of growth. The right groin is occupied by a large mass of adherent glands, which at the lower end have ulcerated and left a sinus. The gland mass was much larger than it appears in the portrait.

After the portrait had been taken the glandular mass continued to grow, and the patient sank exhausted by the ulceration and discharges. A small cancerous ulcer which was present on his back is shown in the next Plate, and the keratose condition in the soles of his feet in Plate CXV. The patient was under the care of Dr. Bullock, of Notting Hill, and was brought by him to Mr. Hutchinson's Clinic at Park Crescent in 1897. He was a man aged 48, who had been the subject of psoriasis from boyhood. Under the advice of the late Mr. James Startin, subsequently that of Sir Erasmus Wilson, and lastly that of Mr. Milton, he had taken many prolonged courses of arsenic. His skin had become generally harsh and dry, and was a light brown tint. His palms were harsh, but had not developed definite corns. (See 'Archives of Surgery,' vol. ix. page 63.)

ROYAL ASIATIC SOCIETY LIBRARY OF THE BOMBAY BRANCH OF THE

Hale & Danielsson, Ltd., London.

PLATE CXIV.

EPITHELIAL CANCER FROM MEDICINAL USE OF ARSENIC.

In this Plate, from the same case as the preceding one, an ulcer on the skin of the back is shown. It is superficial, and of polycyclical borders. There is no great amount of growth. It was gradually spreading at its edges. The patient died of cancer of the original glands some months after the portrait was taken, but no opportunity for microscopic examination was afforded.

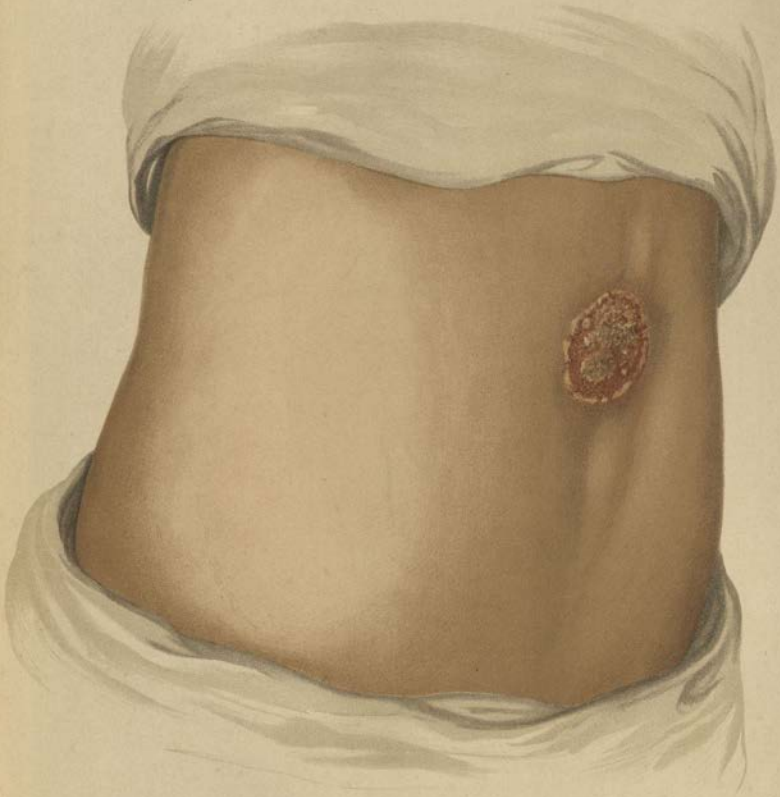

Hale & Danielsson, Ltd., London

PLATE CXV.

KERATOSIS OF THE SOLES OF THE FEET FROM MEDICINAL USE OF ARSENIC.

In this Plate, from the same case as the two preceding ones, we have shown the keratosis condition of the soles of the feet. It had been present for a year or more before the patient's death, and was quite independent of his old psoriasis. That it was due to the arsenic which had been given, and not to the psoriasis, probably no one will doubt who compares the state with that shown in Plate CIX. The palms of the hands were affected in a similar manner. The stains which are seen on the legs are those left by the old psoriasis.

Bale & Danielsson, Ltd., London.

PLATE CXVI.

PIGMENTATION OF THE ABDOMEN FROM ARSENICAL POISONING.

For this portrait the 'Atlas' is indebted to Dr. Kelynack. It is given in order to show the condition of pigmentation of the abdomen resulting from arsenic, and was taken from a patient who came under observation during the Manchester epidemic of arsenical poisoning from beer.



West, Newman chromo.

PLATE CXVII.

ARSENICAL PIGMENTATION AND KERATOSIS OF THE SOLE.

For this, as also for the preceding, we are indebted to Dr. Kelynack. It shows brown pigmentation of the skin of the foot, and also keratosis of the sole with peeling of the epidermis, and some congestion of the derma. It, like the preceding, was taken from a patient the subject of poisoning by arsenical beer. It will be seen that the type of keratosis differs considerably from that shown in Plates CV. and CVIII.* This is explained by the fact that the poisoning was not chronic but sub-acute.

LIBRARY OF THE BOMBAY BRANCH OF THE ROYAL ASIATIC SOCIETY

West, Newman, chromo.

MISCELLANEOUS ILLUSTRATIONS

CHIEFLY

DERMATOLOGICAL.

PLATES A TO J.

PLATE A.

BROMIDE ERUPTION IN A CHILD.

(Copied from Photographs supplied by Dr. Arthur Hall, of Sheffield.)

Fig. 1.—The portrait here given is from a photograph taken by Dr. Hall, of Sheffield. The child, a boy of six months old, was brought to the hospital in the condition here shown. The history was that it had been taking an advertised medicine known as "Infants' Mixture" every night for several weeks. The eruption disappeared in a short time after the child's admission. It will be seen that the eruption is of the papulo-tuberous form, a not uncommon type in connection with the bromide of potassium.

The Museum of the Polyclinic contains a large collection of portraits in illustration of Drug Eruptions, and from this a liberal selection will be made in a future Fasciculus of the present 'Atlas'; but as some little time must necessarily elapse before that Fasciculus is reached, the anticipatory publication of such photographs as that now given may not be unacceptable.

ACCIDENTAL VACCINATION ON THE BACKS OF THE HANDS.

Fig. 2.—The hands of a nursemaid who had never herself been vaccinated, but who had taken charge of an infant after its vaccination. She had suffered from chapped hands, and inoculation had taken place at several different parts. The accidental vaccination ran a usual course.

FIG. 1.

FIG. 2.

PLATE B.

ILLUSTRATIONS OF INHERITED SYPHILIS.

(Copied from Photographs supplied by Dr. Arthur Hall.)

Fig. 1.—A gyrate eruption on the buttocks and backs of thighs of a young child who was the subject of inherited syphilis.

The tendency to become gyrate is a marked but not a very common feature of certain types of syphilitic eruption both in the inherited and acquired forms. It seldom occurs in the early secondary eruptions, which are usually either erythematous blotches or papules, and which show little or no tendency to spread at their borders. They are abundant in quantity, but not usually in any degree serpiginous. The gyrate pattern is obviously produced by the coalescence of large rings which have advanced by contagion of continuity at the edges, and have left areas which have returned to health. They are therefore, so far as this feature is concerned, more nearly allied to tertiary than to secondary lesions; that is, they seem to imply local contamination rather than blood-disease. In point of time they are usually seen intermediate between secondary and tertiary phenomena. They are perhaps more frequent, in ratio with the total number of cases, in inherited than in acquired syphilis.

Plate No. XXVIII. of the New Sydenham Society's 'Atlas of Skin Diseases' shows a marked type of this kind of eruption in a young girl; and Plate XXXI. a similar condition on the neck of an adult woman.

Fig. 2.—In this portrait several special features of inherited syphilis as observed at the period of puberty are well shown. The left upper central incisors exhibit a characteristic notch. The bridge of the nose is much sunken. There are linear fissures (long ago healed) at the angles of the mouth and in the upper lip. In addition to these features, which are common in severe cases of inherited taint, we have the very exceptional condition of partial paralysis of the third nerve on both sides. The eyelids and the brow are thrown into deep wrinkles by the energetic action of the occipito-frontalis in the endeavour to lift the lids by elevating the eyebrows. The eyeballs diverge owing to weakness of the internal recti. This portrait may be instructively compared with one published by Dr. Byrom Bramwell in his excellent Clinical Atlas.

FIG. 1.

FIG. 2.

PLATE C.

IMPETIGO CONTAGIOSA.

(From a Photograph by Dr. Arthur Hall.)

The only particulars as to the subject of this portrait which we can give are that he was a lad of 17, and that the eruption had been coming out for five weeks before he came under Dr. Arthur Hall's treatment in the Skin Department of the Royal Hospital at Sheffield. Whether the lad had been a football player is not known. Under treatment by parasiticidal applications he was soon well.

The portrait affords an excellent illustration of an eruption which was formerly known as Porrigo, and more recently as Impetigo contagiosa. It has long been recognized that it is very contagious, and also that it is very readily cured if the crusts be carefully removed and some parasiticidal application, either lotion or ointment, sedulously used. The ointment of the ammonio-chloride of mercury, a scruple to the ounce, is perhaps the most convenient, but a weak solution of the perchloride will serve the purpose equally well.

The initial stage is always a delicate vesication and not a pustule. Abundant secretion of a fluid which forms heaped-up crusts resembling dried honey is one of its prominent features. Auto-inoculation is easy, and its subjects often spread the eruption to other parts of their bodies by scratching.

Epidemics of this disease have been observed in connection with vaccination in football-players, in whom the contagion occurs from the jersey. In young children it often affects the scalp, and it is probable that pediculi serve to convey the contagion. If neglected, and especially on the lower limbs, it may produce ulcerations, and be attended by pustules (see Plate XV. in New Sydenham Society's 'Atlas').

The collection of portraits illustrating this eruption in the Polyclinic Museum are numerous, and may be found in the south end of the gallery.

The micro-organisms which attend these affections are probably, although allied, not identical in all cases. They have been carefully studied by many observers. Although of great scientific interest, a knowledge of them is fortunately not essential to successful practice. It is sufficient to assume their presence, and treat the case accordingly.

PLATE D.

ACUTE SHORT-LIVED ERUPTION ON THE FACE OF A CHILD.

FIG. 1.—This portrait, which is copied from a photograph kindly supplied by Dr. Arthur Hall, of Sheffield, shows an acute vesicating eruption on both sides of the face of a child. It was diagnosed, but with some hesitation, as symmetrical herpes, and on its sudden onset and rapid subsidence appeared to conform to the herpetic character. It may be doubted whether this form of eruption, which is well-known, is really closely allied to Herpes. The character of its crusts closely resembles that of contagious Impetigo, and although in most instances it appears to undergo, like Herpes, spontaneous cure, it is possible that it does not always do so. There is an excellent model in the Museum of the Hôpital St. Louis, in Paris, which illustrates this eruption, and concerning which it is expressly stated that it got well in the course of a few days. Plate XX. of the New Sydenham Society's 'Atlas' illustrates the same course, and an exactly similar eruption. Although no local treatment was adopted, whilst the artist was engaged on the drawing the eruption rapidly dried up and disappeared. In its extensive development and irregular distribution on both sides of the face it is unlike Herpes; but, as already said, in its tendency to disappear quickly it conforms to the well-known characters of that malady.

ACUTE SCABIES ON THE HANDS OF A CHILD.

FIG. 2.—This figure, which, like the preceding, is copied from a photograph taken by Dr. Hall, of Sheffield, shows the ordinary appearances of acute and severe Scabies occurring on the delicate skin of a young child. Very numerous vesicles and vesications are seen, and the digits and the backs of the hands are somewhat tumid from inflammatory swelling.

PEMPHIGUS AND ITS VARIANTS

(MORE ESPECIALLY IN REFERENCE TO SO-CALLED DERMATITIS HERPETIFORMIS.)

THOSE who are fortunate enough to possess the New Sydenham Society's Library, and will take down from the shelf vol. 143, will there find placed together the several papers in which Dr. Duhring described the disease now known as "Dermatitis herpetiformis." These papers, containing as they did numerous case-narratives, given with that accuracy of detailed observation for which the author's name may be considered a guarantee, supplied a new and important chapter to the records of Dermatology. It may be doubted, however, whether the attempt to place the cases described under a new name, and thus apparently to disassociate them altogether from the Pemphigus family, was a judicious step. It was based possibly upon an arbitrary and too restricted definition of what ought to be included under the clinical term of "Pemphigus." Duhring's observation was that there are certain cases of bullous and vesicular dermatitis in which many of the vesicles are small, and by no means amount to bullæ, and in which they are often arranged more or less in the paniculate pattern, like the grouping of Herpes zoster. No natural alliance with Herpes was proved or even implied, for the disease was described as generalized and always symmetrical, persisting, often even tending to become chronic, and prone to relapse,—features the converse of what we know of most forms of true Herpes. Nor is it well to insist that Pemphigus, although its prominent character is the production of large bullæ with but little inflammation of the surrounding skin, shall never be attended by small vesications and diffuse congestion of the skin. To do so would leave very few cases, if any, to be placed under that name. Most of the cases, indeed, which Duhring records would have been named by the dermatologists who preceded him a-typical forms of Pemphigus. Nor are some of the cases even very markedly a-typical. They were attended by large bullæ; they lasted with relapses over very many years; and although often not cured, they were usually influenced for good by arsenic. On this latter point Duhring writes: "Amongst such drugs I would speak first of arsenic, which in suitable cases offers, I believe, more hope of benefit than any other remedy."

It should be the aim of the clinical investigator to construct natural families of disease, associating the members of each by real relationship. He should avoid as much as possible all arbitrary definitions, and carefully abstain from giving different names to conditions which are only modifications of the same malady. This is especially difficult in cases where the cause of the malady in question is not specific, but associated with derangements of functional health which are susceptible of modification. Such is emphatically the case with the forms of Dermatitis under consideration. Dr. Duhring, as the result of close study of the literature of the subject, is desirous to claim as really belonging to his newly named Dermatitis herpetiformis a number of maladies known to dermatologists under other designations, notably many cases of Pemphigus, and most of those called Hydroa, all Herpes gestationis, Herpes circinatus bullosus, and the Impetigo herpetiformis of Hebra.

We may fully accept his verdict that all the maladies thus named are really modifications of one and the same, and, going a short step further still, may suggest that either all Pemphigus should pass into the family of Dermatitis herpetiformis, or that the latter should itself be relegated back to that of Pemphigus. To speak of Herpetiform Pemphigus would be

very different from using the term Herpetiform Dermatitis. It would suggest what really is the fact—a relationship to Pemphigus, and only a simulation of Herpes—whereas the other loses itself in vagueness, or even suggests what is not true. We have but to give a broader and less arbitrary meaning to the word *Pemphigus*, and, instead of insisting that it shall be applied to an eruption which consists of large bullæ and nothing else, conceive of it as applicable to a state of disturbed health which has for one of its most conspicuous manifestations a generalized Dermatitis which is usually, or, at any rate, in its onset, bullous or vesicular, but which may in the sequel become polymorphous. This done, it would not be difficult to construct a perfectly natural family of Pemphigus maladies, and to designate in their names their relationship.

It should be recognized that all maladies of this class are liable to set in by an acute stage, which may threaten or even cause death. If they begin more mildly, or if by suitable treatment the fatal event have been warded off, they are prone to pass into a chronic state, and assume modifications as regards their skin manifestations. Under treatment, or even without it, they may wholly disappear, and the health may be restored, but always with a remarkable proneness to relapse after an interval. In the male sex, with the exception of certain cases due to drugs (bromides, iodides), it is usually very difficult to assign any cause either for the first attack or for relapses, but in the female the influence of functional changes in the state of the reproductive system is often well-marked. Thus relapses may occur in connection with menstruation, pregnancy, or lactation.* A liability to become pruriginous characterises them all, but in very varying degrees of severity. All are more or less under the influence of arsenic. In many it arrests the eruption at once, and restores the health, though it does not prevent relapses; in others it effects a partial cure, and changes the character of the Dermatitis, and in a few it aggravates the itching and renders the patient more uncomfortable. There are probably exceedingly few cases in which it does not arrest the tendency to the formation of large bullæ, although it may leave a vesicular or even pustular eruption.

In connection with the use of arsenic, it is necessary both in English and American practice to remember that nowadays we but rarely have the opportunity of studying uncomplicated cases. Everyone gives arsenic for all conditions in the least resembling Pemphigus, and thus almost all chronic or relapsing cases have been modified in their evolution by that potent drug. Dr. Duhring records expressly: "Upon enquiry I have found that most of the patients who have been under my observation had at one time or another previously taken a course of arsenic," and, although uncured, they had not improbably received modification from it. Dermatitis herpetiformis may thus be for the most part a name for Pemphigus diutinus when practically cured by arsenic.

The more or less paniculate or herpetiform arrangement of the lesions in any eruption is no proof of real alliance with Herpes. Even the exanthemata are often so arranged, and it is well known that Hebra claimed this feature for Variola itself. The cutaneous nerves probably take a share in the localization and arrangement of many eruptions which are originated by blood-causes.

Amongst the portraits in the Polyclinic Museum which illustrate the eruptions which different authorities have named Pemphigus, we have in addition to the portrait published by the New Sydenham Society in its 'Atlas' (Plate XIII.), and that given by Erasmus Wilson, the following one, taken from Radcliffe Crocker's 'Atlas,' showing a man's thigh. In the description of the latter it is especially stated that the man had previously had a red raised eruption, which itched severely, and was called "prickly heat." Two months later some hemp-seed-sized vesicles appeared, and two months later they were bullæ as large as marbles. As the case progressed, a bullæ became larger and larger

*In this feature the Pemphigus family does not stand alone. All observers have recognized that in cases of common psoriasis the liability to relapse during either pregnancy or lactation is very marked.

in successive crops. At the time the drawing was taken they varied in size from a pin's-head to that of a small egg.

The portrait shows a considerable amount of erythematous congestion around the bullæ, and extensive excoriations. The author names the disease simply "*Pemphigus*," and records that although the patient was so weak that he could scarcely turn in bed, and although quinine had failed to relieve him, he was cured by a course of arsenic, and left the hospital quite well within a month of its commencement.

Amongst the portraits taken from Kaposi's 'Atlas' is one which is named "*Pemphigus vulgaris incipiens*," showing small bullæ with much erythema; a "*Pemphigus vulgaris hæmorrhagicus*," showing large bullæ with blood-stained fluid; a "*Pemphigus circinatus*," in which small bullæ are grouped in circles, no doubt produced by peripheral spreading. This portrait is copied from an original one in Hebra's 'Atlas,' where it is named Pemphigus vulgaris. In this instance there are no large bullæ, nor is there any definite herpetiform arrangement.

Another portrait shows *Pemphigus vulgaris chronicus*, showing small bullæ, partly in circles with many excoriations and stains, no doubt from a partially cured case.

A *Pemphigus pruriginosus* is depicted in another Plate; the arm of an old woman being covered with excoriations and small bullæ.

Under the diagnosis of *Dermatitis herpetiformis* we have a beautiful portrait—an original water-colour by Burgess. It shows the eruption on the back of an adult woman, occurring in groups not unlike those of Herpes, and consisting of small vesicles, there being no large bullæ. This patient, a married woman who was bearing children, was liable during many years to recurrences of the eruption. The latter was always most definitely controlled by the use of arsenic, and she finally became quite free from it. (See 'Archives,' vol. v. page 10.)

Another portrait published by Dr. Radcliffe Crocker, with the diagnosis *Hydroa herpetiforme*, very closely resembles the one just mentioned. The patient, who was under Dr. Sangster's care, was a man aged 20. The eruption had frequently relapsed, and it is especially noted that it always disappeared quickly when arsenic was given. The ringed arrangement of the vesicles is distinctly seen in this portrait. Although the grouping of the vesicles may be said to somewhat resemble that of Herpes, there is neither in this nor in the preceding one any arrangement in the least like Herpes zoster, and the vesication of the borders producing little circles is a feature which very definitely distinguishes them from all true Herpes.

This group of facts proves quite definitely that the forms of Pemphigus which most nearly resemble typical "*Dermatitis herpetiformis*" are just as amenable to treatment by arsenic as is common Pemphigus itself. The only difference is in the size of the bullæ, and this is a very variable character. Clearly they all belong to one family, and it is a matter of regret that different names should be used.

There is yet to be mentioned the syphilitic form of Pemphigus.

An original water-colour by Burgess shows the arm of a man covered with large Pemphigus bullæ in various stages. In this instance the patient was passing through the secondary stage of Syphilis; his Pemphigus eruption proved intractacable under mercury, but was cured when arsenic was pushed in full doses. The patient's case, together with another similar one, is published in the 'Archives of Surgery' (vol. iv. 198).

It may be plausibly suggested that the clue to the essential relationship of these various forms of bullous Dermatitis is the hypothesis of congenital peculiarity in the structure of the skin, rendering it prone to sub-epidermic effusions (Epidermatolysis). Thus congestions from constitutional causes, which might in other persons result in an urticaria or a psoriasis, produce in these persons vesicular or bullous eruptions. Irrespective of the special cause, arsenic tends to restrain the tendency to fluid effusion and dries the skin.

PLATES E, F.

CASE OF PEMPHIGUS HERPETIFORMIS RECURRENT IN ASSOCIATION WITH PREGNANCY.

(Dr. Arthur J. Hall's Case.)

The four portraits here given illustrate a case in which severe Pemphigus eruptions repeatedly occurred in connection with pregnancy and lactation. On several occasions they recurred after an interval of health during the latter part of a pregnancy, but on others they came out with great severity after delivery. The case was published by Dr. Arthur Hall in the 'Quarterly Medical Journal,' vol. viii. We here reprint part of an abstract given in the 'Medical Review,' and shall append other facts kindly supplied by Dr. Hall, which bring the case up to date. It will be seen that the patient has now for some years been free from the eruption, her child-bearing period having apparently ceased. Dr. Hall published the case under the designation of "Dermatitis Herpetiformis (Hydroa Gestationis)." We have already given reasons for preferring to use the term Pemphigus rather than Dermatitis for all eruptions definitely and chiefly bullous, and for wishing to get rid altogether of that of "Hydroa."

"In February, 1896, a woman, aged 40, eight months pregnant, felt severe itching over the backs of the forearms; almost immediately the skin became red and inflamed, and within twenty-four hours small vesicles formed. About three days later the ankles and calves, and, a few days afterwards, the thighs, neck, and abdomen were similarly affected. Labour occurred in March. The feet and chest were first involved on April 23rd, four weeks after the confinement. On April 26th there were small blebs near the webs of the fingers and vesicles on the backs of the hands. The forearms were almost free from vesicles, the skin being rough and scaly with brownish red patches (where there had been at the beginning a number of blebs). At the flexures of the elbows the skin was red and inflamed, and showed one or two large blebs and the relics of others. On the fronts of the thighs were large blebs, most of which had burst, leaving raw bleeding surfaces. The legs were also affected. There was a large rounded dark-brown patch irregularly raised into papules extending over the whole of the lower half of the abdomen. In May the eruption disappeared.

In March, 1898, when the patient was four months pregnant, the rash reappeared. She was seen in April, when it was limited to the forearms, and consisted of vesicles and papules *arranged in little groups, of which some had a striking resemblance to a patch of herpes*. During the whole of this pregnancy the rash remained limited to the forearms, and gave very little trouble. She was confined of a dead child on July 7th, and the rash appeared on the following day. A severe attack followed."

Subsequent to this narrative two pregnancies occurred. During and after one no eruption occurred, but after the second, which ended prematurely in a still-birth at seven months, a most severe attack followed.

Dr. Hall informs us that on all occasions he gave arsenic with good results, though not with definite cure.

On May 10th, 1903, Dr. Hall ascertained that his patient had not recently had any relapses, nor had she again been pregnant. It was believed that the pigmentation, which was very intense on the abdomen, had begun before any arsenic had been given. It was more or less permanent. It is to be explained that the different tints of the photographs do not in any degree imply pigmentation or its absence, but result from difference in exposure. The palest of the four was taken subsequent to the others.

In some instances the eruption came out during pregnancy, but in others not until after delivery. The earlier ones were before, and the later ones after. Six or eight attacks were counted during eleven years. It is very necessary to remember that arsenic was always given, since, although it did not cure, it may have much influenced the progress of the disease and shortened some of the attacks.

PLATE G.

PEMPHIGUS HERPETIFORMIS (POLYMORPHOUS PEMPHIGUS).

The photographs here reproduced represent the state of the skin (in June, 1900) of a charwoman, aged 65. The eruption was somewhat polymorphous, consisting of Erythematous areas, papules, vesicles, and bullæ. The patient's statement was that her eruption had first attacked her in November, 1896. It was first observed on the right arm, but rapidly spread over the whole body. She described it as "like bunches of grapes full of water." The attack lasted five months, and during most of the time she was confined to bed, and partially "lost the use of her legs." Nothing is known as to the treatment during this stage.

When the first Pemphigus outbreak subsided it did not wholly disappear, and during the next four years it was never quite absent. It varied much in severity at different times, possibly in connection with treatment. In June, 1900, she came, for the first time, under the care of Dr. Arthur Hall, at the Sheffield General Hospital. She was then suffering from a relapse, and was covered with vesicles and small blebs. The eruption was attended by much soreness and itching. She complained of loss of appetite and dizziness. She was admitted into the hospital, and liquor arsenicalis in ten minim doses, three times a day, was prescribed. Under this she improved rapidly, and in August it was noted that she had not had any fresh bullæ for some weeks. She was then discharged and lost sight of. It is to be noted that her skin had become rather deeply pigmented.

In May, 1903, Dr. Hall, with a view to the present publication of the case, was good enough to look up the patient. He found that she had not needed treatment since her cure in 1900, but that she was still liable to the occurrence of successive crops of papules, chiefly on the abdomen and back. The general pigmentation was still well marked. It may be added to the patient's history that she was a married woman, and had borne one child. She had suffered from small-pox in childhood, but had since enjoyed good health. Menstruation had ceased at the age of 40. Her first eruption had followed after a cut thumb.

It will be seen that there is not much in this narrative to connect the eruption with Herpes, whilst in its chief features it comes close to the cases hitherto known simply as Pemphigus. It was cured definitely by the drug which is usually a specific for Pemphigus, and the cure stood well for several years, the relapses being but slight. It it unfortunate that we do not know the treatment pursued in the earlier stages. It is not improbable that she had repeatedly taken arsenic for a time. The pigmentation of the skin would corroborate such a suspicion. In view of the fact that the eruption was grouped more or less in the paniculate manner, and that it was for the most part vesicular rather than actually bullous, the term Pemphigus Herpetiformis is perhaps the most appropriate. Several cases closely parallel in history and progress are narrated by Dr. Duhring in the papers which are reprinted in the New Sydenham Society's volume.

PLATE H.

DENTIGEROUS CYST IN THE UPPER JAW.

[From a Patient under the care of Dr. Thelwall Thomas, of Liverpool, by whom the Photographs were supplied.]

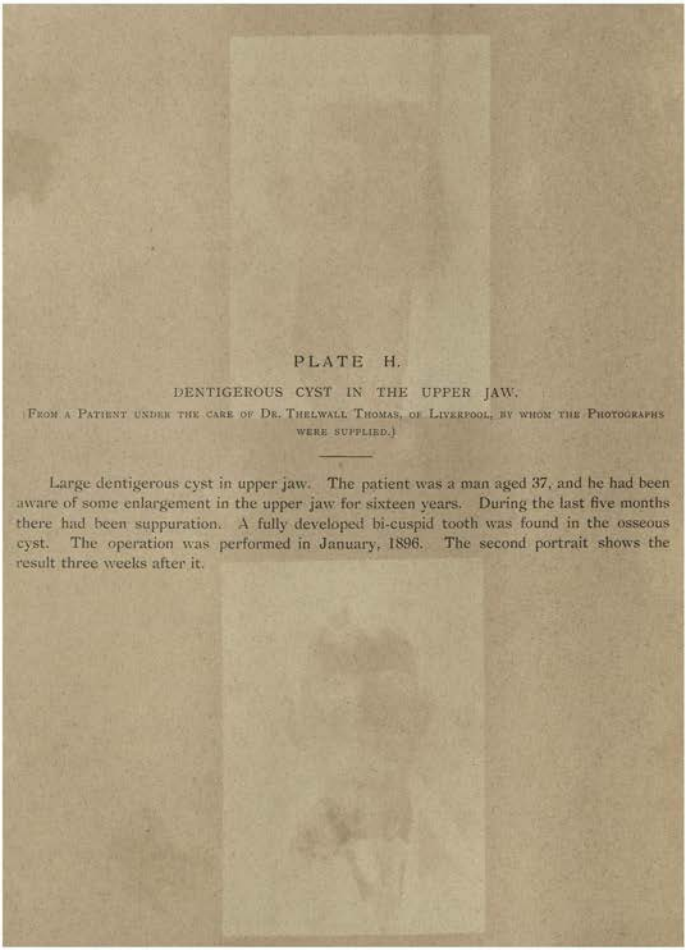

Large dentigerous cyst in upper jaw. The patient was a man aged 37, and he had been aware of some enlargement in the upper jaw for sixteen years. During the last five months there had been suppuration. A fully developed bi-cuspid tooth was found in the osseous cyst. The operation was performed in January, 1896. The second portrait shows the result three weeks after it.

PLATE J.

EPITHELIOMATOUS ULCERATIONS IN SCARS.

(From Photographs supplied by Dr. Thelwall Thomas, of Liverpool.)

Fig. 1.—Epithelioma in the scar of an old burn. The burn had occurred seventeen years previously, and had destroyed the external ear and the skin adjacent to it. On one part of the epitheliomatous part the dura mater was exposed, and the pulsations of the brain could be seen and felt.

Fig. 2.—A photograph showing a large ulcer in the front of the bend of the elbow. The ulcer had developed in an old scar. It shows polycyclical edges, somewhat raised, and its surface is covered with bossy masses of granulation tissue. In some parts the ulceration was deep; amputation was performed on February 26th, 1898. The patient died a year later with return of the disease in the glands of the arm-pit.

FIG. 1.

FIG. 2.

FRACTURES AND DISLOCATIONS

ILLUSTRATED BY RADIOGRAPH PORTRAITS.

PLATES K TO O.

PLATE K.

TRANSVERSE FRACTURE OF OLECRANON.

FIG. 1.—Radiograph taken several months after a transverse fracture of the olecranon (with wide separation) had been wired. The site of fracture is still marked by a faint line, but bony union was complete, and the contour of the joint-surface and olecranon is perfect. In adults, and when muscular action has helped in the production of the fracture, the position of the latter is usually as shown here, opposite the upper border of the coronoid process, or but slightly higher. This is of importance with regard to operation, since the upper fragment will be found of ample size to allow the silver wire to obtain a firm grip. The wire in this case (owing to the position of the elbow when the radiograph was made) appears to transverse only half the thickness of the bone. This is an illusion, as the drill was passed just short of the articular cartilage. The wire loop had worked somewhat loose, and was subsequently removed. The range of flexion and extension in the case was perfect, and the triceps muscle remained as strong as that of the uninjured arm.

Wiring the olecranon is reserved for those cases in which there is marked separation of the fragments, and it should be done within a few days of the accident (as soon as the inflammatory reaction has subsided), before the olecranon has become fixedly retracted. One marked advantage of wiring is the fact that at the end of three or four weeks free movement of the joint is usually regained, and that flexion may be encouraged before this.

The patient was a working-man under the care of Mr. J. Hutchinson, Junr., at the London Hospital.

SEPARATION OF LOWER EPIPHYSIS OF HUMERUS.

FIG. 2.—Radiograph taken by Dr. F. M. Mackenzie from a case of separation of the lower epiphysis of the humerus in a young girl, the result of a fall from a bicycle. The accident had occurred a few months previously. No proper reduction had, however, been effected, and union had occurred with the epiphysis at the back of the humeral shaft. Much new bone has formed in the periosteal bridge connecting the epiphysis and diaphysis. But it will be seen that the projection in front, which limits flexion to less than a right angle, is not due to excessive callus (as used to be thought in these cases), but is simply the bare end of the diaphysis. The deformity is such that an operation might well be suggested to remove the projecting portion of the diaphysis. Nature, however, may be safely trusted to remodel the bone; and radiographs made a year later by Dr. F. M. Mackenzie showed that everything that could have been done by an operation had been quietly effected without it. The range of flexion had greatly increased, and the elbow had become nearly perfect in contour and function.

The same remarkable remoulding of bone has been proved in cases of separated lower epiphysis of the femur when the deformity at first has been most pronounced. At the end of two or three years hardly anything abnormal can be detected by the radiograph. (H. L. Barnard and J. Hutchinson, Junr.)

The deformity is so peculiar and so great that it may perhaps be desirable to repeat that the projecting bone seen above the coronoid process is the rounded end of the shaft, and that the bone in apposition with the ulna is the lower fragment displaced backwards and upwards behind the shaft. It may perhaps be doubted whether the separation of the epiphysis did not involve also detachment of some not inconsiderable fragments from the end of the shaft, as is often the case.

FIG. 1.

FIG. 2.

PLATE L.

FRACTURE WITH DISLOCATION AT ELBOW IN A CHILD.

Radiographs taken by Dr. Fred. M. Mackenzie from a case of old fracture-dislocation at the elbow in a child. The accident had occurred when the patient was aged four; she was now six, and the range of movement (90°) is illustrated in the two photographs. There has evidently been a dislocation forwards of the radius, so that only the edge of its head plays against the capitellum; and, in addition, there has been a fracture at, or close to, the epiphysial line. Thus the articular surface of the humerus is deformed (seen best in E), the lower fragment having united when displaced forwards. In flexion it will be noted that the ulna has very slight contact with the humerus.

In this case the joint was most useful, and the range of mobility would increase with years. No operation could be justified.

FIG. 1 shows the position of the bones with the arm extended.

FIG. 2.—In flexion.

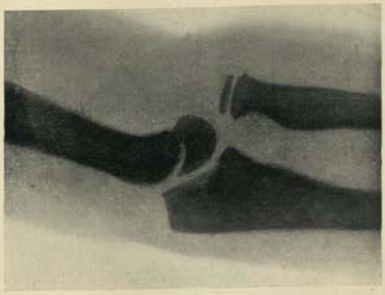

FIG. 1.

FIG. 2.

PLATE M.

FRACTURE WITH DISLOCATION AT THE ELBOW.

FIG. 1.—Fracture-dislocation at the elbow-joint—a typical and not infrequent accident in adults. As the result of some injury, usually of a fall upon the hand, a violent strain upon the elbow-joint is inflicted. The ulna is too securely locked in position to become displaced, but it fractures a few inches below the joint. There is then nothing to hinder a continuance of the force dislocating the radius, either backwards, or backwards and outwards. In this case (a man, aged 30, who had been thrown heavily from his bicycle, and whose forearm had been run over by a cart) the radial head rests on the lower edge of the capitellum.

The patient was sent to Mr. J. Hutchinson, Junr., three months after the accident (when the radiograph was made). The dislocation had not been noticed early, owing to the swelling which followed the accident. The two fragments of the ulna had united at an oblique angle, the forearm was shortened, and the power of rotation of the radius was entirely lost. Flexion and extension at the elbow were very limited. The question naturally arose as to operation; if any were done, nothing would suffice short of chiselling through the ulna at the site of fracture and arthrotomy of the elbow-joint, with probably incision of the radial head. Improved rotatory movement and a straighter forearm might be expected, supposing the operation resulted favourably. In the present case the patient decided to content himself with a stiff elbow.

It may be noted with regard to this important form of injury that when a violent force is transmitted up the arm it is impossible for the interosseous ligaments between radius and ulna to tear; if one bone gives way, and the force continues to act, a dislocation higher up is almost certain to result. The subject is illustrated and discussed by Prof. Helferich in his work on 'Fractures and Dislocations.' (See New Sydenham Society's Library, vol. 167.)

OSSIFICATION IN MUSCLES AFTER INJURY TO ELBOW-JOINT.

FIG. 2.—*Myositis Ossificans* following a severe injury to the elbow. A radiograph taken about three months after a dislocation backwards of both bones at the elbow-joint had been sustained. The patient was a man of about fifty years; the myositis was of the well-known traumatic type, and did not spread beyond the vicinity of the injured part. It is especially to be noted that there had been no fracture, only a simple dislocation, which had been properly reduced and treated from the first. There was nothing in the man's history to throw light upon the tendency to abnormal formation of bone. As the radiograph shows, large plates were deposited in the triceps and brachialis anticus muscles, so that movement of the joint became extremely limited. The case is described in the Clin. Soc. Trans. for 1901 (J. Hutchinson, Jr.). Another almost identical case was under the same surgeon within a few months of the first.

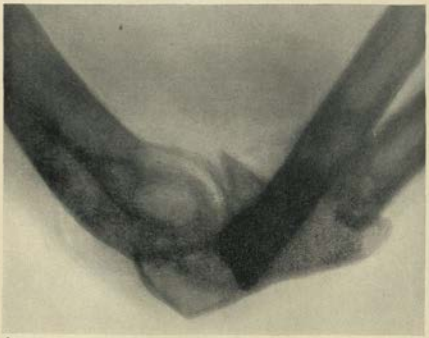

FIG. 1.

FIG. 2.

PLATE N.

SEPARATION OF THE LOWER EPIPHYSIS OF THE FEMUR BEFORE AND AFTER REDUCTION BY FLEXION OF THE KNEE.

The two radiographs are of course from the same subject. In the first the epiphysis is seen to be riding in front of the diaphysis; the latter almost touches the tibia, so great is the displacement.

In the second skiagraph the epiphysis has completely returned into place by the simple manœuvre of flexing the knee-joint to a right angle. A pad of wool is then bandaged in the popliteal space, and the knee kept flexed for three to four weeks, at the end of which time union will be firm. A McIntyre's splint is very convenient for maintaining the flexed position. With extension of the knee it is, as a rule, impossible to effect reduction.

(J. Hutchinson, Jun., and H. L. Barnard, Med. Chi. Trans.)

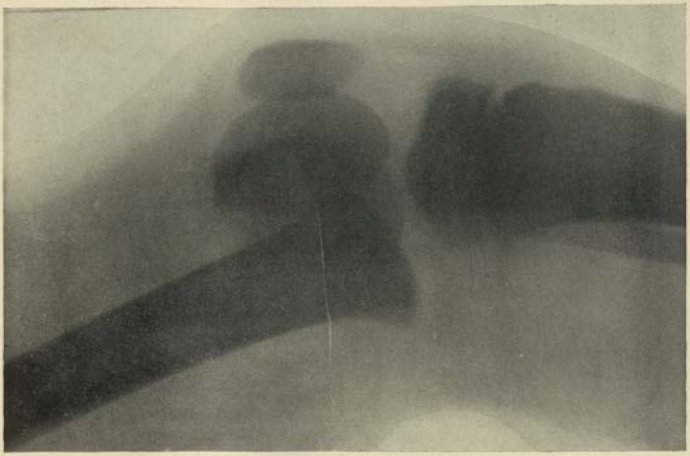

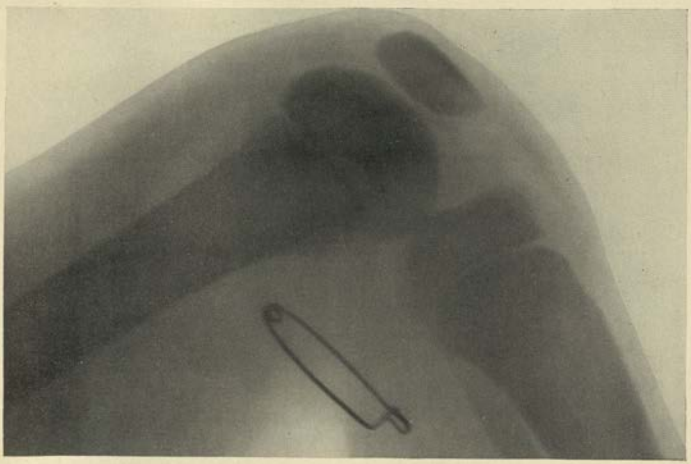

PLATE O.

DISLOCATIONS OF FIRST PHALANX OF GREAT TOE.

FIG. 1.—Photograph of case of dislocation of the great toe upwards. It shows how slight is the apparent deformity, and illustrates the especial value of the radiograph.

FIG. 2.—Radiograph showing upward dislocation of the first phalanx of the great toe in a lad of sixteen. The sesamoid bones are seen to be displaced upwards with the phalanx, as is the case in the corresponding dislocation of the thumb. The metatarsal bone is wedged downwards; this is especially evident at the joint between it and the internal cuneiform. Reduction could only be effected by division of the glenoid fibro-cartilage between the sesamoid bones from the dorsal aspect of the joint. This was done with a tenotomy knife, and reduction then became easy. The case did perfectly well, and there was no tendency to recurrence.

FIG. 3.—This radiograph is from another and an older patient than Fig. 2. In the first case it will be seen that the epiphyses have not yet united. The two, however, resemble each other in a remarkable way. The value of the radiograph in such cases is great, as it determines at once the nature of the dislocation, the deformity being slight and concealed by swelling. The radiograph of each shows that the sesamoid bones travel upwards with the phalanx (exactly as in the corresponding dislocation of the thumb), and they form, with the glenoid plate, the chief obstacle to reduction. In this case reduction was effected by hyper-extension and downward traction under an anæsthetic.

Both these cases were under Mr. J. Hutchinson, Jr., at the London Hospital.

FIG. 1.

FIG. 2.



FIG. 3.

AN

ATLAS OF ILLUSTRATIONS

OF

CLINICAL MEDICINE, SURGERY AND PATHOLOGY

COMPILED FOR

THE NEW SYDENHAM SOCIETY

(A CONTINUATION OF THE "ATLAS OF PATHOLOGY")

LIBRA
OF TH
ROME
BRANC
OF TH
ROYAL ASIATI

FASCICULUS XVIII. (DOUBLE FASCICULUS)

BEING VIII. & IX. OF THE CLINICAL ATLAS

Eruptions, &c., caused by Arsenic

PLATES A TO G;

Urticaria Pigmentosa

PLATES CXVIII. TO CXXI. (*Coloured*), PLATES E TO H (*without Colour*);

Illustrations of the Phenomena of Leprosy

PLATES CXXII. TO CXXV. (*Coloured*), PLATES I TO Z (*without Colour*).

LONDON:

THE NEW SYDENHAM SOCIETY

AGENT—H. K. LEWIS, 136, GOWER STREET, W.C.

1903

ILLUSTRATIONS OF THE

RESULTS

OF

ARSENICAL POISONING

INTRODUCTORY STATEMENTS, BY THE EDITOR, PAGES 71 TO 79.

PLATES A TO G

FROM PHOTOGRAPHS TAKEN DURING THE EPIDEMIC OF POISONING FROM ARSENICATED BEER AT MANCHESTER, IN 1901

REPRODUCED BY PERMISSION FROM THE ORIGINAL ACCOUNT OF THE SAME

BY

ERNEST SEPTIMUS REYNOLDS, M.D., F.R.C.P.LOND.

Assistant Physician to the Manchester Royal Infirmary; Visiting Physician to the Manchester Workhouse Infirmary

PLATE A. Figs. 1 and 2.—Pigmentation and Œdema.
„ B. Figs. 1, 2 and 3.—Pigmentation, Erythema, &c.
„ C. Figs. 1 and 2.—Œdema, Pigmentation, Keratosis, &c.
„ D. „ „ Pigmentation.
„ E. „ „ Muscular Paralysis.
„ F. „ „ Bulbous Eruptions.
„ G. „ „ Paralysis of Diaphragm and Extremities.

DISORDERS OF THE SKIN, &c., INDUCED BY ARSENIC.

(Continued from previous Fasciculus.)

In the last fasciculus plates were given illustrating arsenical Pigmentation, arsenical Keratosis, and arsenical Cancer. It is now proposed to supplement these by further evidence, and to give a brief *résumé* of the whole subject.

As regards the Herpes which results from arsenic, it is not necessary to give any pictorial examples. Arsenical Zoster does not differ from the Zoster which results from other causes. The fact that arsenic can cause herpes zoster, and that it not infrequently does so, is, however, of great clinical importance. It was first asserted in the year 1870, as the result of observations made at the Blackfriars Hospital for Diseases of the Skin, and although at first received with much incredulity, it is now acknowledged by all observers. It was indeed the frequent occurrence of zoster in the cases of peripheral neuritis in the recent epidemic at Manchester which led Dr. Reynolds to suspect the presence of arsenic in the beer, which was already under suspicion in reference to the neuritis. Whilst, however, we must accept arsenical zoster as affording proof that the mineral can produce symptoms on the skin which are located by the peripheral distribution of nerves, it by no means follows that it is through the nervous system that all the various changes in the skin which are due to arsenic are brought about. It may be the fact that others of them, and perhaps a large majority, are due to its direct local influence, when conveyed to the skin by the blood, or when applied externally. It is highly probable that we have in the case of the English chimney-sweeper a good example of the effects of arsenic when applied to the skin in small quantities through long periods of time. It is well known that the soot of English coal contains much arsenic, and it is well established that those whose occupations bring them much into contact with it are liable to changes in the state of their skins from which those who are exposed to purely carbonaceous forms of soot are free. The skin of the English chimney-sweeper becomes harsh and dry, and liable to corneous indurations which pass into cancer. Sir James Paget, who carefully examined the matter, described the sequence of events as follows:—

"A similar drily scaled or incrusted warty change of the cutis often, I believe, precedes the chimney-sweep's cancer; and I suspect that the true influence of the soot in this disease is not that its continued contact determines the growth of cancers, but (at least in part) that it produces a state of skin which provides an apt locality for epithelial cancer in persons of cancerous diathesis. How it does this I cannot imagine, but this is only one of many things unexplained in this strange disease, for the whole of the peculiarities of the chimney-sweep's cancer—its dependence on soot, while coal-dust is wholly inoperative (for the disease is unknown among colliers); its comparative frequency in England, especially in the large towns, while in other countries where soot is abundant it is hardly seen; its selection of the scrotum for its most frequent seat—all these, and many like facts in its history, appear completely inexplicable. Still, it is certain that scaly or incrusted small warts, such as I have been describing, are very common in chimney-sweeps. In many of them, even when they are thoroughly cleaned, the whole skin is dry, harsh, and dusky, and, before operation for the

removal of scrotal cancers in them, it is a common question whether one or more warts or scaly patches near the chief disease should be removed with it. Nor are such warts confined to the scrotum, they may exist on every part of the trunk and limbs; and I have seen sweeps so thick-set with them, that a hundred or more might have been counted."—*From "Lectures on Surgical Pathology," by Sir James Paget, p. 718.*

For obvious reasons we cannot say much as to the pigmentation of the chimney-sweeper's skin, but very probably it resembles that produced by the internal administration of arsenic.

It is of interest to note how closely this description of the skin corresponds with that which results from the internal administration of arsenic. Plates CIX., CXI., CXII., and CXIII., may be cited as good illustrations of the latter. It would appear to make no difference whether the arsenic reaches the skin from without or within, it has the same tendency to produce a dry, harsh condition with the tendency to form corn-like indurations.[1]

In Plates CXVI. and CXVII. we have given coloured illustrations of the deep pigmentation of the skin which occurred in two of the subjects of the Manchester arsenicated beer epidemic, and we now, through the kindness of Dr. Reynolds, by whom that epidemic was first traced to its cause, offer a number of other portraits which, although without colour, still show the conditions in a very instructive manner. The following statements are taken from Dr. Reynolds' little monograph on the epidemic referred to.

Dr. Reynolds on the Skin Lesions which occurred in the Manchester Epidemic.

"These are very numerous, and almost invariably present in some form or other in greater or less degree. (*a*) Erythromelalgia. This condition, described as 'painful red neuralgia of the extremities' by Weir Mitchell, or 'acrodynia' by older observers, was one of the commonest lesions. The soles of the feet are crimson, as if stained with red ink, sometimes the whole surface, but more generally only where the surface touches the ground, so that there is left a normal appearance on the inner side at the hollow of the foot and also a transverse line just beyond the distal extremities of the metatarsal bones. The sole, and often the whole foot, is bathed in perspiration, which may be stinking (but this is rare). The skin is also puffy, even if no true dropsy is present. On the palm the redness may again be uniform, but again more frequently it is most marked on the thenar and hypothenar eminences and on the palmar surfaces of the terminal phalanges, the centre of the palm being normal in colour; the whole palm is wet and may be actually pouring with sweat. Both soles and palms are tingling and burning hot and painful, and these signs are greatly intensified by heat, so that the patients cannot sleep unless the feet are exposed to the air outside the bedclothes.[1] The pressure of the bedclothes cannot be borne and the surfaces are exquisitely painful on pressure, so that, as I have said, the gait is affected, and the patients cannot use the hands, even if no paralysis is present. This erythema does not become pigmented, but passes on to keratosis. (*b*) Keratosis. This condition seems to be a somewhat late manifestation and is, at any rate, very frequently secondary to the erythema and hyperidrosis of the palms and of the soles. I have watched it develop on the hands and feet and can thus speak with some certainty. It may take several forms, it may be in a few isolated scaly masses, either thin or very heaped up in marked prominences, and in this way previous corns on the feet or patches of tylosis on the soles or palms become extraordinarily prominent. In some cases the keratomatous patches appear on the dorsum of the hand between the webs of the fingers and on the knuckles. In more marked cases either the whole palm or sole is thickly covered with large white or dirty grey scales, which are constantly being shed into the bedclothes; or the centre of the palm and inner side of the sole may be merely erythematous and dry, but not covered by scales. Sometimes the keratosis extends up to the ankles and on to the wrists, but the scales are now not thick but more like a branny desquamation. The palms and soles may both be affected, but the soles are almost always the worst, and sometimes are affected alone. Moreover, in cases where there is no pigmentation keratosis may be present and forms a most valuable aid in the diagnosis of a case which might otherwise appear to be merely one of alcoholic paralysis. The process is very slow (many weeks) in its development and seems to be, if untreated, extremely chronic. (*c*) Erythemata. These are very varied in character and are often accompanied by great irritation. There is sometimes a scarlatiniform eruption on the upper part of the chest spreading to the neck and face, sometimes on the forearms and rest of the body. At other times, and perhaps most frequently, it is a morbilliform rash on the trunk and limbs running into scarlatiniform patches; often it is a more distinctly papular erythema, and not infrequently there is an acute urticaria. In some the change is so intense that there is a vesicular eruption in which the lesions may vary in size from that of a pinhead to large bullæ several inches in diameter: those which I have seen have been almost always on the limbs. In one or two cases the appearance has been that of a true pemphigus, and when the contents have been shed circular marks have remained, like very superficial scars. These vesicular

[1] The distinction between a corn and a wart is that the one has for a chief characteristic, and often an uncomplicated one, the overgrowth of papillæ, whilst the other has only an accumulation of closely adherent epidermic scales. The two conditions are often mixed. For the most part what results from arsenic is not a wart, but a corn.

[1] Rarely the patient says his feet are very cold, but on examination they are found to be hot.

eruptions are probably a late form of rash, even coming on six weeks after the last glass of beer had been taken. The erythematous papules sometimes become larger, run together, and are covered with scabs in patches, so that there may be after many weeks an appearance somewhat like lupus or even of superficial syphilitic ulcerations. (*d*) Pigmentation. This is generally not present in light-complexioned patients, or merely amounts to a darkening of pre-existing freckles. In darker people it is practically always present in greater or less degree, but in many is so diffuse that it may entirely escape notice. In most of the cases it follows (after many weeks) the erythematous blush, which gradually turns from red to copper colour, then to bronze, and in severe cases almost to black, so that many of the patients resemble mulattoes. Even if it is thus almost universal it does not affect the palms and soles, nor, as a rule, does it touch old scars in which the deeper layers of the skin have been destroyed, but round the edge of the scar it is much intensified, the scar thus seeming to be of an especially white character. Round the neck, in the armpits, round the nipples, on the abdomen, round the genitals, and on the buttocks, where there has been pressure, as round the waist or under the garters, it is much deeper in tint and, indeed, resembles the pigmentation of Addison's disease; but I have not seen any pigmentation of the mucous membrane of the mouth. Although well seen on the face of many patients, yet on the whole it is more marked on the trunk. Frequently the pigmentation shows well-marked lighter spots like 'rain-drops.' In other cases the pigmentation is seen on close examination to be punctiform. In others it is in isolated spots varying in size from a pinhead to patches equal in size to the palm of the hand, clear light-coloured skin intervening, and often these isolated patches run together to form a continuous pigmentation. Not only is the colour like that of a mulatto, but the texture of the skin takes on the same beautifully soft, velvety feel to the touch, quite different from that of normal English skin. In many cases after many weeks a branny desquamation of the pigmented skin takes place, so that by friction one can rub off the pigmentation, as it were, and leave healthy skin underneath. Having watched numbers of these cases for weeks, I am convinced that there is a distinct sequence of events—namely, an erythema followed by pigmentation and then a desquamation—so that the pigment is really a part of the general altered nutrition of the skin and is not due to a deposit of metallic arsenic in the skin, as was once thought. This view does not necessarily exclude the idea that the drug may be partly eliminated by the skin. (*e*) Herpes zoster. This was the tell-tale eruption which, as I have said, gave me the key to the puzzle. When it occurred without any other very definite symptoms, then I considered that I was dealing with epidemic specific herpes, but when I found other signs of arsenic poisoning present there could be no doubt that it was also arsenical in origin. Since the discovery of the arsenic practically every case of herpes zoster has been found to have other unmistakeable signs of arsenic poisoning in greater or less degree. I have seen rarely herpes of the fifth cranial nerve, a few cases of the ascending branches of the cervical plexus, several of the other cervical nerves, many of the dorsal nerves, and one of the first lumbar nerve. In no case has the herpes been bilateral, and generally only one nerve-root was affected, but in two cases I have seen two succeeding nerve-roots affected. I have seen no herpes below the elbow or below the knee. From the great number of cases seen in this district there is to my mind no longer any doubt that arsenic causes herpes by a direct action on the posterior spinal ganglion, just as much as it acts directly on the motor and sensory nerve fibres; this seems to me to be a much more probable view than that put forward by Dr. H. Head, that arsenic is only a remote cause of herpes, inasmuch as it renders a person more liable to attack by specific herpes. In fact, how many of the epidemics of so-called specific herpes (such as that described by Dr. Head as occurring in 1897, during the long drought that lasted from July to November) have not really been due to arsenical poisoning? From actual therapeutical observation I have seen a few cases of herpes develop when I have been giving small doses of arsenic in which the only other sign of arsenical poisoning was lachrymation and a silvery tongue. I am indeed convinced that it may come on with quite small doses. The herpetic eruptions have always been preceded and accompanied by very severe neuralgic pains along the course of the nerve or nerves affected. And I may here state that I have had many cases with severe neuralgic pains in the arms or round one side of the trunk which I expected would be followed by herpes, but none appeared. (*f*) Nails. In many cases the nails are affected. After the patients have stopped taking the beer for some weeks the best appearances are seen, for then there is a transverse white ridge across the nail. Proximal to this the nail is normal, but distal to it the nail is whiter, cracked, thin, and towards the tip almost papery and much flattened. In some cases there have been a series of parallel transverse ridges on the nails, almost suggesting a series of week-end 'drinking bouts.' These deformed nails of course break easily. (*g*) Loss of hair. One or two women have told me that they have lost the hair during the attack, but this has certainly not been a marked feature."

Pigmentation of Skin.

It is no new observation that the administration of arsenic may cause pigmentation of the skin. Observations on this subject were made more than half a century ago, and have been repeated by many different clinicists. That at the same time a peculiarly dry state of the skin often results has also not escaped notice; and it has even been suggested that it is owing to its power in this direction that the drug is found so efficacious in certain diseases of the skin, more especially in those, such as pemphigus, which are attended by proneness to fluid effusions and the formation of bullæ.

Portraits CIX., CX. and CXV. illustrate the fact that apart from actual pigmentation the skin is made harsh and muddy. Plates CIX. and CXV. show an exceptional tendency to accumulation of epidermic scales in certain

definite regions. As the particulars of these cases are given in the Plate descriptions they need not be repeated here.

Arsenical Keratosis.

Next, upon the statement that arsenic, whether given internally or applied on the surface, causes the skin to become dry, harsh, muddy, pigmented, and occasionally the seat of epidermic accumulations, we have the fact that epidermic corns may result. Of these corns several of the plates which have been given afford good illustrations.

Plate CXI. (for which the Atlas is indebted to Professor Gilletti) is especially valuable, because the nature of these corns is shown in a section, and proof is afforded that they are not of papillary origin. We owe to Sir Erasmus Wilson the first mention of the occurrence of these corns, but he unfortunately encumbered his description by mentioning a peculiar pitting, which is exceptional. The knowledge of the nature of these corns, and the appreciation of their importance in diagnosis, may be claimed as of later date. From the description of the arsenical corns it is only a step to the recognition of a peculiar form of cancer which follows them. This development of Arsenical Cancer is illustrated in Plates CVII. CXII. CXIII. and CXIV.

Other cases of arsenical cancer have been placed on record, and as the subject is a novel one, and still more or less under debate, it may be useful to present the reader with a brief synopsis of them. Before doing so, however, it is desirable to advert to certain other forms of disturbance of the functions of the skin due to arsenic, but which cannot be illustrated pictorially. Very frequently burning sensations are experienced, more particularly in the soles of the feet. These are sometimes attended by pricking sensations, or numbness. In some cases the sudoriparous glands show undue activity in the regions affected, and the soles of the feet may be sodden by perspiration. This, however, is an exceptional condition, the more common one being dryness and epidermic peeling.

The Nervous System.

Various affections of the nervous system in connexion with the administration of arsenic have been recorded. An excellent summary of the information then possessed on this subject will be found in Christison's celebrated work on Poisons. At that date the pathology of what we now know as peripheral neuritis was not understood, but it was well recognised that arsenic might cause paraplegia, hemiplegia, or indeed any form of local paralysis. It was credited also with occasional production of epilepsy. Little, however, had been ascertained as to the effects of the long continued administration in small doses, and almost all the cases cited by Christison[1] were those of acute poisoning by large doses. In order to give a good record of the most recent observations on the latter class of cases, we cannot do better than again quote from Dr. Reynolds' pamphlet, to which we have already referred. Dr. Reynolds had in connexion with the beer epidemic an opportunity for observation such as occur but to few.

It may be added that certain facts are not wanting which tend to confirm the records of the older writers, who regarded arsenic as a "cumulative" poison, the ill effects of which might be not apparent for a long period of time and then develop suddenly and with persistence, when once begun. Not only does the tendency to keratosis and cancer develop late, and occasionally long after the administration has ceased, but the same is observed in reference to affections of the nervous system. Dr. Reynolds writes as follows :—

"(a) Sensory affections have been present in practically all the cases. In the mildest they have merely consisted of paræsthesia and tinglings and burnings and pricking sensations in the fingers and toes; in others these conditions have been combined with numbness of the hands and feet and sometimes of the legs below the knees. I have not seen a case of *total* loss of sensation, although the numbness has been very pronounced. Part of the apparent loss of power in the hands and feet has been due to this partial loss of sensation. In one case there was very marked, but not total, anæsthesia of the whole left fifth cranial nerve, but its motor fibres were unaffected. This is the only instance in

[1] See *Archives of Surgery*, vol. v., 152, 364, 367.

which I have seen any affection, either sensory or motor, of the cranial nerves. Neuralgia of the arms or trunk, either followed or not by herpes, I have already alluded to. Finally, and of the greatest diagnostic importance, there was in a large number of the cases (but only if there was some loss of power) tenderness on pressure of the muscular masses of the legs and arms; sometimes deep pressure was required, but in other cases light pressure produced most exquisite pain and caused the patients to scream out and to exhibit a very typical facial expression of terror, or in less marked cases merely a screwing up of the facial muscles in a 'grin of pain.' (*b*) Motor. These symptoms were similar to those ordinarily found in so-called alcoholic neuritis. They were present in greater or less degree in about 70 per cent. of the cases. In the slighter cases there was only slight loss of grip and slight affection of the gait, and there was then no appreciable atrophy of the muscles. In more marked cases there was a total paralysis of the affected muscles, with very marked atrophy. The small muscles of the hands, especially the interossei, the muscles of the fore-arms, especially the extensors, and in severe cases all the muscles of the arm, were involved. If the muscles of the upper arm were not affected then also the supinator longus escaped to a large extent, as in lead-poisoning. In the early stages, in the feet there was loss of power with some slight irritation of the extensors of the toes, so that the great toe was well extended and 'cocked-up.' In this stage the knee-jerk was always either present or exaggerated, but there was never any ankle clonus. But soon the muscles became paralysed and atrophied, first the interossei and the anterior tibial and peroneal groups, so that the toes were flexed and the whole foot dropped at the ankle into a position of talipes equino-varus. The calf muscles were next affected and at about the same time those of the thigh, accompanied, of course, with rapid wasting and loss of the knee-jerks. The superficial reflexes were normal or exaggerated. Even in this stage the muscles on the front of the trunk were weak, so that the patients could not raise themselves in bed, and in some advanced cases there was well-marked diaphragmatic paralysis, with laboured breathing and a markedly ineffective power to cough. In one case with comparatively slight loss of power in the limbs the diaphragm was entirely paralysed. It goes without saying that in the most advanced cases the patients lay in bed totally helpless. There was no paralysis of the sphincters except in the most marked cases, in which some of the incontinence was possibly due to the mental condition, and the intercostal muscles were never paralysed. I never saw any paralysis of the cranial nerves in any case. The walk I have already described as a 'stepping' gait, but many of the patients were distinctly inco-ordinate in their movements, and swayed slightly on standing with the eyes closed, but to my mind there was never any real resemblance to the ataxic walk of a case of tabes. (*c*) Mental. In many of the cases of advanced paralysis there was the peculiar mental condition commonly found in alcoholic paralysis. This has been called 'confusional insanity,' but it is more accurately described as a total loss of memory of time and then of place. There is a loss of initiation of ideas, but any suggestion, however absurd, is at once accepted. Thus a totally paralysed patient who has been in bed for weeks, when asked if he has not been for a walk this morning, will say that he has, and will tell you with much circumstance where he has been; and when asked about yesterday, will perhaps say with a little prompting that he has been to the seaside. If asked when he came into hospital, he will always turn towards the nurse at the other side of the bed and say: 'Let me see, I think it was yesterday [or some other near date], wasn't it, nurse?' But, taking only the paralysed cases, I am inclined to think that the amount of mental confusion has been distinctly less than I should have expected from as many cases of ordinary alcoholic paralysis, which rather leads me to think that arsenic has not much effect on the cerebral cortex."

Cases of Arsenical Cancer.

It is to be clearly asserted that the effects of arsenic on the skin often persist long after the disuse of the drug. In the instance of the corns and of the tendency to cancer growths, there is indeed usually observed not only persistence but increase of these results. The corns multiply and continue to degenerate. Nor is the tendency to produce malignant growths restricted to the skin itself. Sarcomatous growths may develop in the subcutaneous cellular tissue or the internal viscera may be affected. Many facts make it probable that the mucous membranes are, equally with the skin, liable to be so attacked.

The following is a series (for the most part in order of chronology) of the principal recorded examples of arsenical cancer.

Case 1.—*Psoriasis in boyhood and subsequent long-continued use of arsenic. Malignant growths in the palms of both hands at the age of 43. Repeated operations. Death, with gland disease and internal growths* (Plate CXII.).

The particulars of this very important case have been so fully recorded, both in America and at home, that it is not needful to repeat them. (See *Transactions of Pathol. Soc. of London*, vol. xxxix., p. 360.)

Case 2.—*Psoriasis treated by arsenic. Keratitis of palms, and cancerous growths in front of wrist and near to anus.*

The subject of a case recorded by Dr. White, of Boston—under whose observation Case 1 came in the first instance, and to whose investigations the subject is much indebted—was a gentleman, aged 52, who had suffered from psoriasis from boyhood. Ten years before coming under Dr. White's care he had noticed that the skin of his palms was becoming thick and warty. Subsequently an ulcer formed in front of one wrist, which is described as having been exactly like that figured in Plate CXII. Caustics and free excision were the measures used. Death from cellulitis followed. A small growth near the anus was also excised. Microscopic examination showed "the presence of large

masses of epitheloid cells of irregular shape and size, separated by narrow bands of fibrous tissue, and extending deeply downwards into the subcutaneous fat tissue."

CASE 3.—*Cancerous ulcer on the sole of the foot of an elderly man who had taken much arsenic for psoriasis.*

In this case the ulcer healed after excision and caustics, but another malignant growth subsequently occurred on the skin of the thigh. A portrait showing the sole of the foot is preserved in the Clinical Museum. The microscope confirmed the diagnosis, and the patient ultimately died of cancer of the stomach. (See *Polyclinic*, vol. vi., p. 386.)

CASE 4.—*A single cancerous ulcer on the back in a man who had taken much arsenic.*

This case was under the care of Mr. Buckston Browne. The patient, a man of middle age, had taken much arsenic before the development of the cancerous ulcer on his back. The conditions of the latter closely resembled those shown in Plate CXIV. The ulcer was excised, and no return has been recorded. The microscope confirmed the diagnosis of epithelial cancer.

CASE 5.—*Psoriasis in boyhood and lasting through life. Repeated use of arsenic. Cancerous ulcers in two places at the age of 42, and death from gland implication.*

This case is given in detail in *Archives of Surgery*, vol. ix., pp. 63-223. Its subject, a man aged 47, had, on account of psoriasis, taken arsenic under several specialists, at intervals, from boyhood. He was brought to Mr. Hutchinson's clinic at Park Crescent on October 9, 1897, by Dr. Bullock, of Notting Hill. The cancerous ulcer was on the lower part of the abdomen, and was supposed to occupy the site of a former patch of psoriasis. It was as large as a child's palm, but a long oval in shape (see Plate CXIII.). It had rolled, everted borders and a florid, granulating surface. Near to it in the right groin was a mass of adherent glands, which had broken down in several places. It was about three years since changes in the psoriasis patch had first attracted attention, but only during the last year had the advance been rapid. Both the base of the ulcer and the enlarged glands were firmly adherent to the abdominal wall, and the conditions clearly excluded hope of relief by operation. The man had been salivated under a diagnosis of syphilis, and had also taken much iodide of potassium. There was, however, no history of syphilis. His skin generally was brown, harsh and dry, and on his soles were the remarkable epidermic accumulations which are displayed in Plate CXV. On many parts of the surface there were roughened patches, concerning which it was difficult to say whether they were the remains of psoriasis or due to arsenic. On his back was an ulcer which was characteristic of the latter. The man was emaciated and weak, and he died from exhaustion two months after the portraits were taken. The ulceration in the groin had in the interval advanced rapidly.

In this case, as well as in several others, the microscope had been used with the result that nothing characteristic of epithelial cancer was found. Unfortunately, there was no autopsy, but there could not be the least doubt that death was caused by rapidly advancing cancerous ulceration.

In the following case we had the advantage of several reports from the Clinical Research Association.

CASE 6.—*Arsenic taken for psoriasis, with interruptions for many years. Keratosis in palms of hands and cancer in one palm and on one shoulder. Subsequent development of "soft carcinoma" and of multiple epithelioma with gland disease.*

Mr. L., then aged 70, first consulted the writer on September 29, 1899. He had an ulcer of some standing on the forefinger of his right hand, and another on the back of his right shoulder, just where the brace might have rubbed. Both ulcers were somewhat peculiar in their features, and in association with them was a rough, corneous condition of the palms which led at once to the diagnosis of "arsenic-cancer." At first it was doubted, both by his medical attendant and himself, whether he had ever taken much arsenic, but subsequent investigation proved that he had. Immediate amputation of the finger was advised, and free excision of the ulcer on his shoulder. After a little delay these operations were done at his home in ——shire, and the specimens were forwarded to the Clinical Research Association. The report was as follows, December 13, 1899:—

"Both of these specimens are affected with squamous-celled epithelioma. In the finger the subjacent tissues are deeply infiltrated, and there is advanced keratoid change in the epithelial processes. In the ulcer from the back the epithelioma has penetrated to the level of the subcutaneous fat. The cells in this specimen are smaller and more diffused. There are very few cell-nests here."

(Signed) J. H. TARGETT.

A year later the scar of the amputation was sound, and so was that on the shoulder, but within an inch or two of the latter, towards the spine, was a rounded subcutaneous tumour, rather soft to the touch, and about as large as a hen's egg. The skin overlying this was loose and absolutely free from change. From the proximity to the scar, we could only believe that the growth was due to infection from the original ulcer. It was not like a gland, and it was in a position where no gland is present. The patient thought that a little nodule had been present at the time of the operation and had been overlooked. Excision was again done at the patient's home. This specimen was also sent to Mr. Targett, and the report was "soft carcinoma of the acinous type."

The following notes record the patient's condition in June, 1902: The scar of the amputation has become horn-like, and there is, crossing it, a deep crack, which shows a florid surface at the bottom. There is no papillary outgrowth. The palms of both hands are roughened by numerous corns, some of which are also present on the sides of his fingers, and even on their backs. About his wrists are some dry, scaly patches, like dry eczema. The scars of the two excisions on his shoulders, though of considerable extent, are quite

healthy, excepting that in the middle of the second some induration has recently taken place. There are many little patches of dry and roughened skin on various parts of the trunk and limbs, and a few senile verrucæ on his back. His soles are in the same condition as that shown in Plate CXV., only not so advanced. They show thickened cuticle on all the parts exposed to pressure, producing what might, were the condition less diffuse, be called very large corns. Over these patches, which involve the whole heel and tread of the front foot, and exempt the arch, there is white desquamation. On the outer side of one foot, quite out of the pressure-area, is a very peculiar patch. The horn-like epidermis is half an inch thick, and stands in columns, which are split vertically after the pattern of the Giant's Causeway. These are not papillary, but purely epidermic, as is proved by the fact that they occasionally break off. When they do so a clean surface is left, from which they are soon reproduced. Two attempts have been made, by the use of caustics, to cure this patch, but without success.

The patient's appearance is that of a florid, delicate-skinned old man. When, however, you inspect his face critically, you find many little scabrous patches here and there, any one of which may be the beginning of more serious changes. There are a few also on his bald scalp. As regards gland-enlargement, there are quite definite glands in both armpits, and also a few very hard but very small ones in the right posterior triangle of his neck. The latter are found with difficulty. He knew of them himself and directed attention to them. The details as to his former drug-treatment are as follows:—

About the age of 20 he developed an eruption which persisted a long time, and for which he says that arsenic was given. He does not recollect that it disagreed, and as to doses and length of treatment nothing is certain. This eruption, apparently psoriasis, continued to relapse throughout his subsequent life, and he was repeatedly for long periods under drug treatment. He does not know what was given him. A few years prior to the first consultation, however, he took arsenic under the advice of a medical man, who has kindly supplied details. It was given for the patient's old-standing eruption. He took seven minims of Fowler's solution three times a day for some months, until it definitely disagreed. The symptoms which it produced were loss of flesh, debility, some numbness in the feet and hands, and buzzing in the ears. It was laid aside for a time, but as the eruption had relapsed, it was, after an interval, again given, and again disagreed. It was from the date of this second course that the keratosis of his palms began to be noticed.

This patient is at the present date, August, 1903, still living and in good general health. He has, however, enlarged glands in many positions in his neck and axillæ. There is recurrence of growth in the scar of his hand, and a deeply-seated growth near to the scar on his shoulder. The multiple developments of disease are now of such a character that it is not proposed to do any further operations. It would be necessary to amputate one or both hands and to remove glands from six or seven different localities. There are, besides, many corneous patches on the skin which are in the way to form new independent foci.

Case 7.—*Multiple growths and repeated excisions.*

In 1894 Mr. Arbuthnot Lane recorded in the *Clinical Society's Transactions*,[1] a very important case. Its subject was a man, aged 63, who had taken arsenic for the cure of psoriasis almost half his life. In April, 1892, Mr. Lane excised from the back of his forearm an epitheliomatous growth two inches in diameter. In 1893 he again applied with three distinct cancerous ulcers on his scrotum, and in December, 1893, and January, 1894, he was again admitted for new ulcers on the same part. Counting the sore on the forearm as four (since it had resulted from the coalescence of four), there had been eleven different foci of these growths. All had been freely excised and all examined microscopically. Unfortunately, Mr. Lane does not describe the condition of the palms and soles, or give any particulars as to other symptoms of arsenical disagreement. The arsenic, it will be observed, was stopped in March, 1893, but growths continued to be produced a year later.

Case 8.—*Multiple growths and repeated excisions.*

At p. 339 of "Archives," vol. v., the case is mentioned of a gentleman, aged 35, who had three growths excised from different parts during seven years. He had also keratosis of his palms. In this instance an interval of ten years was alleged between the disuse of the arsenic and the development of the epitheliomatous growths. He might, however, have been drinking arsenical beer all the time. The keratosis of the palms occurred soon after the disuse of the arsenic, and persisted.

Cases 9 and 10.—*Lympho-Sarcoma after Arsenic.*

At p. 282 of vol. viii. of "Archives," are mentioned two cases in which tumours in the neck, probably glandular in site, but malignant in their course (lympho-sarcoma) occurred to those who had formerly taken long courses of arsenic for skin diseases.

Case 11.—*Lupus Cancer, with the history of long courses of Arsenic.*

At p. 186 and p. 233 of vol. vi. of "Archives," the case is mentioned of a lady who had taken arsenic for long periods for lupus. In December, 1888, her palms and soles were in a condition of keratosis, and the further use of arsenic was forbidden. In July, 1890, her palms and soles had quite recovered. At one time (in 1877), whilst taking arsenic, part of the edge of the lupus patch assumed the hard rolled condition of a rodent ulcer. It got well, however, under cauterisation with nitric acid.

Case 12.—At p. 224 of vol. ix. of "Archives" is a very important case. A lady of 45, who had taken arsenic, and who had for long suffered from keratosis of her palms, came under observation with a large isolated growth in her neck. It was as big as a child's fist. It was excised, and proved to be, not sarcomatous, but squamous-celled epithelioma. She had at the same time a growth under the skin in the left mammary region and there were also gland masses in one groin. Thickened and ulcerated portions of skin had on two occasions been excised from her palms, and the wounds

[1] Vol. xxvii., p. 102.

left had healed for a time and then relapsed. She died, insane and comatose, four months after the consultation, with suspicion of growths within the skull.

On looking up her old prescriptions, it was found that during 1879 and 1880, for twenty months continuously, she had taken ten minims of Fowler's solution per day. It was given for epilepsy. The condition of the palms and soles did not, according to these dates, begin until five years after the conclusion of her arsenical course. From some of her statements, however, it seemed probable that she had, unknown to her medical advisers, taken arsenic both before and after the course referred to.

CASE 13.—*Cancer developed some years after leaving off the arsenic.*

This case is recorded by Mr. Pernet in the *British Medical Journal* for 1901. The patient was an elderly man under the care of Dr. Radcliffe Crocker. The arsenic had been taken in early life and there had been a long interval since its suspension before cancer developed.

CASE 14.—*Long-continued use of arsenic in very small Doses. Keratosis of palms and soles. Epithelial cancer in four different Parts.*

The following extract is from *La Semaine Médicale* for December 10, 1902 :—

"CANCER ARSENICAL.

"M. J. Darier.—Voici un homme de quarante sept ans que j'ai eu l'occasion d'examiner une première fois en 1890. A cette époque il présentait sur la face et le cou un semis confluent de taches pigmentaires lenticulaires et de macules vasculaires. Les mains et les pieds étaient le siège d'une hyperkératose diffuse avec d'innombrables verrucosités cornées. Je l'avais perdu de vue depuis douze ans, lorsqu'il est revenu me voir au printemps dernier. J'ai alors pu constater que la mélanodermie et les télangiectasies s'étaient atténuées, mais que les verrues cornées persistaient. Quatre d'entre elles, trois aux mains et une au cou, s'étaient transformées en véritables épithéliomes; ce diagnostic fut vérifié par l'examen histologique pratiqué après que ces petites tumeurs eurent été enlevées à la curette. Actuellement, on voit à l'angle de l'un des yeux se développer un nouvel épithéliome. Or, l'origine de ces lésions cutanées trouve son explication dans ce fait que le malade, pour traiter une bronchite chronique avec induration des sommets, a pris quotidiennement, de 1886 à 1896, 12 gouttes de liqueur de Fowler pendant douze jours chaque mois et, depuis 1896 jusqu'en 1901, durante sept jours par mois.

"On sait qu'en 1887, M. J. Hutchinson soutint l'existence d'un cancer arsenical (Voir *Semaine Médicale*, 1887, p. 502-503). Cette opinion, accueillie à l'époque avec scepticisme, a été confirmée depuis lors par un petit nombre d'observations. Le cas actuel nous semble lui apporter un appui sérieux."

It would not be difficult to add to this list of fourteen cases which illustrate the occurrence of malignant disease in those who had previously taken long courses of arsenic. As the cases adduced, however, are from the observation of different authorities and from distant countries, and as most of them have been submitted to more or less public scrutiny, they will be accepted by most as fully proving the main positions. There are, moreover, remarkable similarities in some of them. The history of the antecedents and the final results are precisely the same. It would appear to be shown that the use of arsenic in prolonged medicinal courses gives not only to the skin, but to other and possibly to all the tissues of the body a definite proclivity towards cancerous modes of growth. Multiplicity is a feature which was eventually present in almost all the cases and recurrence after removal occurred in almost all in which operations were performed. In all the cases in which this point is noted, dryness of the skin with keratosis of the palms and soles preceded the development in cancer. In nearly all the cases the form of cancer was the flat-celled epithelial, but in one there was simultaneously with this kind of epithelial growths a subcutaneous tumour which was diagnosed on good authority, a "soft carcinoma of the acinous type." In another there was a tumour in the breast. Although the flat-celled epithelial type was recognised without hesitation in several cases, yet there were others, and of these some which ran the most definitely malignant course, in which skilled microscopists failed to find any proofs of such structure. Case No. 1 was a noteworthy instance of this, for observers in America, England and on the Continent, who had good opportunities of investigation, denied that the growth was epitheliomatous, and persisted in a diagnosis of syphilis. The same occurred in Case No. 5. Thus it is clear that this form of malignant action has its own peculiarities, and that these pertain to its naked eye features, as well as to histological characters. We may refer to the plates for proof of the first part of this statement. The conditions represented are not those usually seen in epithelial cancer. They more nearly simulate those of an ulcerating gumma in

some features, such, for instance, as excess of inflammatory swelling and absence of papillary or granulation growth. In almost every case a suspicion of syphilis was entertained in the first instance, and in several it was persisted in for long, notwithstanding the entire absence of history. Yet in all these the final recognition of malignancy was unquestionable. The gland disease is also to some extent peculiar. Sometimes the glands remain long without change and are very hard, whilst in others, a minority, inflammation and breaking-down occur early.

A very remarkable fact appears to be established in reference to the length of interval which may occur after the suspension of the arsenic before the development of the cancerous growth. It would seem that the latter in most instances waits until the advent of senility gives its assistance to the influence exerted by the drug. It may also easily be the fact that arsenical cancer occurs chiefly in those who have an inherited predisposition. Regarding it thus as only amongst several items of contributory causation, we cannot feel surprised that when once the tendency to malignant growths has been made manifest, it shows a proneness to increase rather than otherwise as time passes on.

This subject is one of extreme pathological and clinical interest in more directions than one. The proof that the influence of arsenic in the tissues can predispose to cancer and, indeed, induce malignant action of somewhat peculiar and of various forms, seems to strike at the root of all theories as to the parasitic origin of neoplasms. Clinically it also opens a new field of enquiry as to the causes of the recent increase of cancer, and suggests that this may have been in part due to the increased employment, medicinal or otherwise, of minerals, of which arsenic may be only one. A considerable majority of the cases in which cancer has followed the use of arsenic have been those in which it was given for the treatment of psoriasis. It must not, however, be forgotten, that there are other affections for which this drug is often freely used, and that it is possible that its influence may be much wider than is at present suspected. In the treatment of nervous diseases it is often very freely prescribed, and to a certain extent no doubt it is resorted to as a cosmetic. The affection known as lupus-cancer, in which the scars of lupus become the sites of epitheliomatous growths, may possibly be to some extent due to the arsenic so frequently used for that disease.

POSTSCRIPT.

Whilst these pages have been passing through the press, an important paper has appeared in the *Journal of Cutaneous Diseases*, from the pen of Dr. M. B. Hartzell, of Philadelphia. From this we extract the following:—

"Since Mr. Hutchinson first pointed out that arsenical keratosis may be followed by epithelioma a number of cases in which this has occured have been reported. A few years ago I had the honor to report such a case to this Association, and since the reading of that paper at least one other case has been recorded. Geyer, in a most interesting paper upon the changes induced in the skin by chronic arsenical poisoning, calls attention to the marked tendency of the so-called arsenic warts to be transformed into epithelioma, and refers to no less than six cases in which such transformation took place, reported to him by the physicians in a single district, Reichenstein, where a considerable number of the inhabitants suffered from chronic arsenical poisoning induced by arsenic-containing drinking water. In view of the facts, it can scarcely be doubted that a close relationship exists between arsenical keratosis and epithelioma."

The readers will find numerous references to the connexion between Arsenic and Cancer in the pages of the *Polyclinic Journal*, as well as in the *Archives of Surgery*. The influence of the drug is no longer supposed to be confined, in reference to cancer, to those cases in which keratosis is the first stage.

PLATE A.

RESULTS OF ARSENICAL POISONING.

(Dr. Reynolds.)

FIG. 1.—Pigmentation with desquamation.

FIG. 2.—Early symptoms: Great œdema, dilated heart, bronchitis, pains in feet and calves; pigmentation.

PLATE A

[illegible] POISONING.

([illegible])

[illegible] with desquamation.

[illegible] dilated heart, bronchitis, pains in feet and calves, pigmentation.

FIG. 1

FIG. 2

PLATE B.

RESULTS OF ARSENICAL POISONING.

(Dr. Reynolds.)

FIG. 1.—Papular and erythematous eruption.

FIG. 2.—Arm from the same patient as above, six weeks later.

FIG. 3.—Scattered and patchy pigmentation.

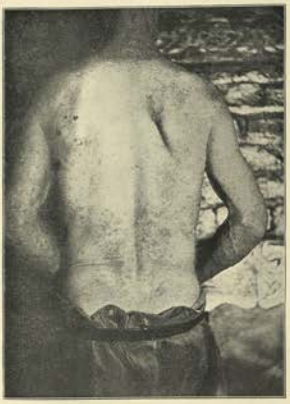

FIG. 1

FIG. 2

FIG. 3

PLATE C.

RESULTS OF ARSENICAL POISONING. KERATOSIS OF SOLES.

(Dr. Reynolds.)

FIG. 1.—Early symptoms: Great œdema, dilated heart, and bronchitis. There were pains in feet and calves and much pigmentation. The patient was the woman whose face and hands are shown in Fig. 2 of Plate A.

FIG. 2.—Keratosis of the soles of feet.

Fig. 1

Fig. 2

PLATE D.

RESULTS OF ARSENICAL POISONING. PIGMENTATION.

(Dr. Reynolds.)

FIG. 1.—Deep pigmentation of almost the whole surface. Patches of unpigmented skin are seen, proving that the general discoloration was caused by coalescence of affected areas.

FIG. 2.—Marked chocolate pigmentation affecting the trunk and limbs. The face was fairly free. (A healthy man is placed by the side of the patient to show contrast.)

FIG. 1

FIG. 2

PLATE E.

RESULTS OF ARSENICAL POISONING. PARALYSIS.

(Dr. Reynolds.)

FIG. 1.—Total paralysis of extensors and peronei (external popliteal nerve). From the same patient as Fig. 2 in Plate G.

FIG. 2.—Atrophy and paralysis of extensors and peronei (external popliteal nerve).

It is of much interest to compare this figure with Plate CXXIV., in which the same result is shown as a consequence of Leprosic Neuritis. It would appear that the external popliteal nerve is especially prone to suffer alike when the neuritis is caused by a mineral poison as when it is due to a specific bacillus.

Fig. 1

Fig. 2

PLATE F.

RESULTS OF ARSENICAL POISONING. BULLOUS ERUPTIONS.

(Dr. Reynolds.)

FIG. 1.—Late bullous eruption.

FIG. 2.—Late bullous and vesicular eruption.

FIG. 1

FIG. 2

PLATE G.

RESULTS OF ARSENICAL POISONING. PARALYSIS.

(Dr. Reynolds.)

FIG. 1.—Early total paralysis of diaphragm.

FIG. 2.—Total paralysis with wasting (and slight œdema) of hands and forearms.

FIG. 1

FIG. 2

ILLUSTRATIONS OF

URTICARIA PIGMENTOSA

INTRODUCTORY REMARKS BY THE EDITOR, PAGES 83 TO 92.

(Coloured)

PLATE CXVIII.—Urticaria Pigmentosa on the face of a boy.

" CXIX.—Urticaria Pigmentosa on the trunk of the same.

" CXX.—Urticaria Pigmentosa on face of a young man.

" CXXI.—Urticaria Pigmentosa on trunk, &c. of the same.

(Without Colour)

" E.—Urticaria Pigmentosa in a boy, front view. (Mr. Brougersma's case).

" F.—Urticaria Pigmentosa in a boy, back view of same case.

" G.—Urticaria Pigmentosa in a girl. (Dr. G. S. Fox's case).

" H.—Photograph showing the present condition of Subject of Plates CXVIII. and CXIX.

URTICARIA PIGMENTOSA

AND

ALLIED AFFECTIONS.

ROYAL ASI

URTICARIA PIGMENTOSA.

THE condition of the skin which has by general consent received the name of URTICARIA PIGMENTOSA is of great clinical interest. Although in its typical results it is rare, it introduces us to the study of causes which are very common. It was first described by Mr. Edward Nettleship in 1869, from a case under observation at the Blackfriars Hospital for Skin Diseases, and was subsequently investigated with care and given a name by Dr. A. Sangster in 1878. It has since been observed in various countries, and concerning its general features there is great unanimity of statement. The several Portraits which we now place in juxtaposition will fully confirm the inference that its features, when well marked, are fairly uniform. It must be remembered, however, that these Illustrations represent well-developed and what may be called consummated cases. The early stages of the eruption and its less well-characterised forms do not lend themselves so attractively to the photographer's art, nor do they indeed often come under the notice of the clinical observer. Nor, perhaps, is it by any means certain that the eruption, if submitted to observation at any early stage, would receive its correct designation. Its distinctive features may be supposed to be rather slow in development, and such terms as Urticaria perstans, U. perstans-papulosa, Lichen urticatus, Prurigo urticans, Urticaria hæmorrhagica, might very possibly seem applicable in the early stages.

DESCRIPTION OF SYMPTOMS.

It is not difficult to assign the conditions which denote Urticaria pigmentosa. Whenever an eruption, which has begun by a crop of urticarious wheals, persists for many months or years, tends to become of a yellow or brownish tint, that designation is justified. Considerable latitude must be permitted for minor deviations from type, but the characters just specified are usually definite and conclusive.[1] The wheals and their resulting papules may vary much in size and in thickness. Some may be mere blotches—the macular form—whilst others may be so much thickened that the term "nodular" has been thought applicable. As a rule, the eruption begins in early infancy, or at any rate in childhood, but in exceptional instances its advent may be delayed until adult age. Almost invariably the history given is of a sudden and quite local onset, and its advance is usually by equally sudden recurrences. Very often the statement of the nurse is that a few new wheals are often observed on taking the child out of bed in the morning. Scarcely ever

[1] Dr. Prince Morrow, recording the experience of our Transatlantic *confrères*, says that "Urticaria pigmentosa is a form that is peculiar to childhood, and differs from the ordinary forms chiefly in the repeated recurrence of wheals at the same points, where more or less stationary efflorescences are formed that are attended by pigmentation. . . . The disease begins within the first few months of life, and may at first present the ordinary features of urticaria. . . . New lesions are continually being formed, and the older ones deepen in colour, becoming brownish, and may resemble xanthoma patches, but have a firmer consistence. Bullæ may accompany them. . . . The process usually continues active for several years, after which the nodules or papules gradually subside and the pigmentation disappears."—*Morrow*, p. 775.

is there a history of a general eruption of wheals, such as is common in those forms of urticaria which result from errors in diet. The eruption becomes more and more abundant as time goes on, for a few fresh wheals are added from time to time, and only some of them disappear. The tint may vary from a deep lemon-yellow to brown, or almost black. All parts of the trunk and limbs may be affected, and the face rarely escapes. A peculiar feature is that if the scalp has but little hair some well-marked papules are usually seen upon it. The amount of irritation varies with the stage of evolution. Fresh wheals itch exceedingly, and may disturb the rest of the patient, and even cause fever, but old ones, when pigmented, rarely itch much. As age advances outbreaks of fresh wheals become less frequent and the wheals themselves less abundant.

Although the pigmented eruption may be assumed to consist of persistent papules which have been formed, a few at the time, during a protracted period, it must not be assumed that all the primary papules are still present. Probably a large majority disappeared quickly, and of those which lasted for some weeks it is not unlikely that many finally vanished. Careful observation of individual papules have made this fact of spontaneous disappearance quite certain. In a case which was carefully observed by Dr. Morrow the individual papules rarely lasted more than three weeks, but in most cases their duration is probably much longer than that.

Final Disappearance.

It is generally assumed that Urticaria pigmentosa disappears with the advance of age, but few observations are, however, on record which bear conclusively on this point. The eruption usually gives but little trouble, its subjects get tired of seeking advice, and cease to continue under observation. Only a few cases have been observed in those who had passed the age of 20, and the great majority were under 10[1] at the date of report.

Dr. Prince Morrow writes (November, 1895): "A careful observation of the clinical course of the cases of Urticaria pigmentosa[2] hitherto recorded would seem to show that it is essentially a disease of infantile life, due probably to some congenital predisposition, which shows a spontaneous tendency to disappearance towards the eighth or ninth year, and almost certainly before the period of puberty." Of a case which he himself records, he says, "its persistence with but slight modifications into adult life renders it quite unique."

Pringle states that the disease occasionally occurs in adults and may be mistaken for syphilis.

The General Health Remains Good.

Authors are unanimous that the general health does not suffer however protracted may have been the duration of the eruption, and usually the local irritations becomes less and less as years advance.

Simulation of Xanthelasma.

As has been stated, Urticaria pigmentosa may be described as a cumulative eruption. Its lesions go on increasing in number the longer the case lasts. This is very definitely true of its early stages, but less so of the later ones, for there comes a period at which new papules cease to be added, and this period of cessation may vary much under different circumstances. When that point has been reached, we have but to witness the slow devolution of those which have been produced.

In the later stages the papules may resemble, on the one hand, those of Xanthelasma, and on

[1] Morrow adds: "Arning believes that the cases in which the eruption has appeared for the first time from the fifteenth to the fortieth year are probably not Urticaria pigmentosa proper but ordinary urticaria ending with pigmentation." But who shall decide as to what is "U. pigmentosa proper" and what "ordinary urticaria?" Is urticaria *ab externis* ordinary urticaria, or are we to limit the term to the *ab ingestis* form only? If the production of the urticaria wheal is to be held, without regard to special causes, to be the characteristic of "ordinary urticaria"—and it would be difficult to dispute the point—then U. pigmentosa is unquestionably ordinary urticaria followed by pigmentation. There are endless modifications of the urticarial process, and we must not attempt to construct arbitrary and exclusive definitions.

[2] Sir Stephen Mackenzie brought before one of the societies a boy of 14, who had been a subject of Urticaria pigmentosa all his life, but the eruption had become quiescent. Factitious wheals could still be produced by scratching.

the other, those of Keloid. The latter is seen chiefly in cases where there has been much scratching. Several authors have noticed the simulation of Xanthelasma, and it was especially observed by Dr. Tilbury Fox, who in the first instance proposed for the disease the name Xanthelasmoidea. It has, however, no real affinity with Xanthelasma, unless, indeed, it may perhaps be the fact that the circulation of bile pigment in the blood takes some share in determining the colour. There is a fine portrait in the Clinical Museum (Polyclinic) which illustrates this simulation, and it occurred also in a remarkable degree in a case in the Leeds Infirmary, which was published by Dr. Barr.[8] In both these cases there was much debate as to what the nominal diagnosis should be. Both patients were young.

Proneness to Factitious Urticaria in the Subjects of U. Pigmentosa.

We can scarcely doubt that a condition of urticarial susceptibility is present more or less in most of the subjects of this affection. In many instances it is recorded that factitious urticaria could be easily produced, but in others that it was definitely absent. Its existence in high degree may be the cause of material modifications in the phenomena. We may infer its absence in cases in which the papules remain discrete and limited in number (see Crocker's plate and that given by Sangster), and its presence when the whole skin becomes erythematous and the primary wheals are abundant (see portraits in the St. Louis' Atlas and Prince Morrow's case).

Histology.

It may serve to make us cautious in accepting histological evidence when it is wholly at variance with clinical probability to remember that early investigators, Dr. Thin and others, declared that the cell structure of the pigmented papules was that of Lupus.

More recently the verdict of Unna has been accepted, that accumulations of "mast cells" *in the prickle layer are the cause of what* tumefaction is present. It is also in this layer that the pigment which gives the colour is stored.[1]

Hypotheses as to its Nature and Causes.

Several different suggestions have been made as to the essential nature of Urticaria pigmentosa. Most authorities regard it as what is termed "a tropho-neurosis of the skin,"[2] and admit inability to assign any cause. The theory has even been advanced that the wheals are not the primary lesion, but are developed over the sites of abnormal cell deposits which were congenital. This would bring the disease into the group of non-malignant new growths, and would place it by the side of such maladies as Molluscum fibrosum. It is to be observed, however, that the latter malady continues to increase both in the size and number of its nodules throughout the patient's life, whereas, Urticaria pigmentosa is self-terminable and rarely lasts into middle age. There is no tendency to aggressive growth. Other observers think that more simple explanations may suffice for all that we see in this curious malady, and hold that it is due mostly, if not invariably, to the idiosyncrasy of the patient in respect to certain kinds of external irritation. According to this school we need be under no great concern to differentiate between "Lichen urticatus," Urticaria chronica infantum," "Urticaria perstans," and Urticaria pigmentosa, since they are all for the most part due to the same cause.

The following is Duhring's description of "Urticaria papulosa":—

"Urticaria papulosa. This is a variety of the disease which, on account of its peculiar character and frequency, calls for special remark. It is also known as Lichen urticatus.

"Here the lesion possesses the form of a papule with all the characteristics of a wheal. It is observed particularly in young children, and shows itself as pin-head or split-pea sized, acuminated papules, which appear suddenly, and after con-

[8] Portraits of both these cases may probably be given in a future fasciculus of this Atlas.

[1] Unna has also, in addition to pointing out that the pigmentation is in the rete, very properly insisted that it is not due to extravasated blood, as some had supposed.

[2] Neisser (as quoted by Morrow) writes: "I have not the slightest doubt that in Urticaria pigmentosa we have to do with Mastzellen Tumoren; but how explain the connection between urticaria and the Mastzellen? I believe that the two conditions—urticaria and tumour-like formations—are two *entirely different things*, each for itself, and a causal communication between them is not clearly established. The tumours are of an inherited-form disposition, like the embryo deposits in tumours. The urticaria is only the chance cause of these apparitions."

tinuing hours or days, slowly disappear. They usually occur in a dispersed manner over the body and are rarely seen in great numbers. They are attended with intense itching. Owing to the scratching of the patient their apices are always more or less torn and become covered with a slight blood crust. The disease is most annoying at night. The affection is common amongst the poor, especially those who live in squalor."—*Duhring*, p. 148.

Two Groups of Urticaria.

The two great groups into which all forms of Urticaria should be divided are; those due to internal or systemic causes (whether blood or nervous system) and those caused only by external irritants.[6] Without in the least invalidating this classification, it may be freely admitted that idiosyncracy or individual constitution may greatly modify the consequences of external irritation. Every child is probably liable to irritation from nettle-stings, but some suffer more than others, and the tendency to produce wheals and the persistency of the latter may vary greatly. As regards the bites of insects, the differences are still greater, and it is also well known that fleas, bugs and lice appear to exercise definite preferences as to those whom they attack; one child in a family may suffer much from fleas, whilst others wholly escape. The common bed-bug is yet more preferential in its tastes, and there are many persons who are immune from its attacks.[7]

Certain broad lines of distinction between these two groups of cases of urticarial dermatitis may easily be established. When nettle-rash arises from internal causes it is, as a rule, general and symmetrical in its development, whilst when due to local causes it is restricted to the part which has been attacked. The wheals from external irritation are also usually limited, both in size and number, and they show but little tendency to spread at their borders, whereas the reverse is the case with urticaria ab ingestis. When an urticaria eruption is caused by an error in diet the wheals are usually very numerous and they may run over the whole surface. The wheals are also far more transitory in their duration than in the local form. The latter, indeed, rarely passes away quickly, and traces of its wheals usually last for at least some days.

---

[6] Dr. Bristowe, who was a very close and accurate observer writes that "Chronic urticaria, which supervenes in some cases on the acute form, is generally unattended by marked fever. It shows itself for the most part like it in successive crops of eruption, which come out daily or at irregular intervals, for weeks or months, sometimes for many years. . . . Wheals resembling those of urticaria are often due to the operation of local irritants. They are common in prurigo, scabies and phthiriasis. . . . They follow the bites of many insects, such as gnats, fleas and bugs. In this last case, however, the wheals are persistent, and often last for a week or ten days. *They probably constitute Willan's* Urticaria perstans."—See "Practice of Medicine," p. 311.

[7] The following extract is from *Archives of Surgery*, vol. vi., p. 137:—

"Two children, who were produced at a meeting of the Dermatological Society one afternoon in November, 1894, were the subjects, according to my diagnosis, of very severe eruptions from fleas. Both were covered on body and limbs with papules, pustules, and stains, in various stages of development and retrogression. One was about two years old, and the other fifteen months, and both had suffered from the very earliest infancy. One was exhibited as an instance of 'urticaria pigmentosa,' and the other as a form of 'urticaria bullosa,' for many of the spots had vesicated and formed bullæ. The father of one of the children, on being questioned, told me that the eruption had begun during a visit at a farmhouse, where the child had been dreadfully bitten by fleas. The mother of the other said, on being asked how the eruption had begun, 'It came out first as red spots on one thigh, and I thought they were only bites.'

"*Urticaria Pigmentosa—Persistence of the pigmented patches, with but little change for ten years—The flea-bite hypothesis.*

"An interesting fragment of evidence in reference to the nature of urticaria pigmentosa came to light in the case of a young lady whom I saw in 1894. Miss P——, a very tall girl of 15, was of very clear complexion, and had, so far as her face was concerned, a brilliantly clear skin. She was brought to me on account of a lateral curvature, and it was necessary that she should undress. I found her trunk and shoulders mottled over with deep brown, ill-margined stains, some of them as large as shillings, and the skin generally of a dark tint. None of the stains showed any thickening whatever, and there were no erythematous wheals.

"I was puzzled at first what to make of them, for there was nothing of an urticarious character about the condition. Her mother, however, having remarked that friction or pressure would often bring out red wheals, I suggested to Dr. Stocker, who had brought me the patient, that it must be a state allied to urticaria pigmentosa. 'That is what you called it seven years ago,' he replied, and I then found that I had seen the patient on account of these stains in 1887. She was then a child of 7. I looked up the notes then taken, which were as follows:—

"'Miss P——, 7, of fair complexion; mother rather dark. *Urticaria pigmentosa.* It began, aged 3, by a patch on the neck. Whenever she comes out of the bath the patches are raised and red; they subside when she cools. Her whole skin is said to be becoming darker. Her trunk is covered with brown, ill-margined patches, and there are a few on her limbs. She was formerly very fair.'

"Mrs. P—— told me that, verbally, I then expressed the opinion that the patches had been originally caused by fleas. The girl has not recently been liable to be bitten.

"An interesting point in this case is that the patient's mother believed that the individual patches now present were the identical ones which existed seven years ago. About some of these on the neck she feels quite sure, and the one highest up, which was the first noticed (now ten years ago), is, she is confident, the same as that now to be seen."

Differences in the Kind of Local Irritation.

It is necessary to remember that different kinds of local irritation produce different results. The punctures of lice usually cause very small papules with ill-defined erythematous areas; those of fleas produce wheals (in many persons) so exactly like those of ordinary nettlerash, that both by patients and medical men they are constantly mistaken for it. These wheals are, however, rarely larger than shillings and usually round. The bite of a bed-bug is rarely productive of a wheal, more usually an ill-defined, dusky patch of erythema is the result, with not infrequently considerable swelling. Some differences are also to be observed as to time of attack and the part selected. Bugs prey in the night only and often attack the face and scalp. Fleas are about at all hours, but prefer the covered parts and avoid the face and scalp. Concerning all the blood-sucking parasites, it is to be noted that their object is to obtain a meal, and that having secured this they cease for a time from their attacks. Thus, three or four punctures, usually near to each other, are all that are to be expected if the parasite be solitary.

Facts which Favour the Suggestion of Bites.

Amongst the facts which favour the belief that the original wheals of Urticaria pigmentosa are usually caused by the bites of insects are the following:—

(1) That it is well known that flea-bites (and others) often cause wheals indistinguishable from those of urticaria from internal causes, excepting by their arrangement and their constant limitation in size.

(2) That when fresh wheals occur in Urticaria pigmentosa they are usually arranged in lines and "constellation groups" like those of flea-bites.

(3) That these wheals are always limited in size, and often occur in rounded forms with definite margins.

(4) That a tendency to vesicate is often observed, which is a condition unknown in Urticaria ab ingestis, but well proven as an occasional result of flea-bites.

(5) That fresh spots are usually few in number, occur in a group, and are often developed during the night.

(6) That the liability to the eruption, and the degree of irritation caused by it, diminish in all cases with advancing years.

(7) That the subjects of the disease are almost always apparently in good health.

(8) That summer is the season in which the eruption is most apt to increase, and that in many instances it is in almost complete abeyance in winter.

(9) That the children of the rich are almost absolutely exempt.

(10) That when the subjects of it are removed from their homes and taken into hospitals the tendency to the production of fresh spots usually ceases.

(11) That in some instances the presence of pediculi or fleas has been conclusively proved, whilst it is highly probable in almost all.

How to Set the Question at Rest.

It may perhaps not be so difficult to set the question at rest as some may suppose. What is wanted is careful observation of newly-developed wheals. If these are always found in irregular groups, placed in utter disregard of bilateral symmetry, we may be almost certain that they are due to some external cause. If the tendency to them ceases whenever the patient is taken away from his home the inference is obvious. Search may be made in newly-formed wheals for the central puncture, which is often marked by a minute extravasation. It is, perhaps, needless to insist that the assertions—often very emphatic—of parents and nurses must be utterly disregarded.

Insect Parasites not the only Cause.

Those who incline to hold most clearly that Urticaria pigmentosa and its allies are usually produced by external irritation are by no means precluded from recognising constitutional predisposition; nor need they be unwilling to admit that in some instances no definite external irritant may have taken a

share. It may be the fact that U. ab ingestis is but very rarely persistent, and but very rarely followed by pigmentation, and that the wheals due to external irritation are far more prone to be so, and yet these statements may not be of invariable application. Any condition of pruriginous skin, if well scratched, may probably, in some instances, result in lasting and pigmented lesions. Insect bites may be peculiar only in being far more potent than any other lesion in the production of these conditions. It is possible that some of the cases of this disease are due to that peculiar condition of cutaneous irritability which sometimes follows varicella and vaccinia. In all cases much allowance must be made for scratching. Urticarious eruptions of all kinds are probably in this sense to a large extent factitious.

An Illustrative Case (Dr. Radcliffe Crocker).

In the case of which Crocker's Atlas gives an excellent Illustration the patient was a boy of one year, in whom the eruption had been present from the fifth week of infancy. In spite of it the child remained in good health. It is stated that fresh wheals would come out one or two at a time, on an average, not more than a dozen in a week. Latterly, however, one or two had appeared every day. Sometimes a bulla with clear contents would form on the wheal in its earliest stage. There were no fresh wheals to be seen when the child was brought to the hospital. He was kept in the ward for three weeks, and although no treatment was adopted no fresh wheals appeared. The portrait shows numerous discrete papules of yellow tint scattered over the back, face and limbs, and occurring also freely on the scalp. They are arranged in lines or in curves, or quite irregularly, and they show no tendency to become confluent. A very marked deviation from bilateral symmetry is displayed on the child's back, the right lumbar region being entirely free.

The facts which favour the suggestion of bug-bites in this case are:—

(1) The eruption occurred in the scalp, a part very liable to the bites of bugs, but one on which Urticaria ab ingestis is infrequent.

(2) That bilateral symmetry was not observed in the localisation.

(3) That the infant whilst kept in the hospital ward had no fresh spots, although whilst at home they had been coming out at an average of six or more a week.

(4) That the child appeared to have been throughout in good health.

Urticaria Papulosa a Form of U. Pigmentosa.

Fig. 2 in the plate in Crocker's Atlas, although designated "Urticaria papulosa," may be accepted as a minor form of U. pigmentosa. The eruption had been present from the earliest weeks of infancy, and the child was now four years old. Many of the papules show yellow staining. All are, however, of small size. A great many bloody points are seen. In this instance the bites of lice might be suspected rather than those of bugs, and had the portrait been given as one of phthiriasis certainly there could have been no objectors. The grouping of the spots is in lines and irregular patterns (constellation grouping). The eruption had been observed to be worse in spring and summer and better in winter.

In a third portrait in the same Atlas we have the arm of a young child showing an eruption of similar type, but which had been present only a few days. This portrait confirms the suspicions suggested as to cause. In both cases vesications or blisters had been observed.

An Illustrative Case (Dr. Hallopeau).

The case from which the portrait was taken which appears in the Atlas of plates selected from the St. Louis Hospital collection, was very carefully studied at that renowned institution. The final report on it was from the pen of M. Hallopeau. The date of the last report was 1892, and that of the first having been 1885, we have the advantage of prolonged and repeated observation. The eruption began at the age of six weeks, and had continued ever since to the age of eight, when the last report was

made. It had occurred in repeated outbreaks, attended by much itching and more or less of fever. Bullæ had often been observed, and some atrophic spots (thin cicatrices) had been left. Several of these thin scars are well shown in the portrait. The whole of the patient's skin is somewhat pigmented and the urticarious eruption is of a yellow-brown tint. At parts it is arranged somewhat in streaks, but many of the spots are round. It is so abundant that almost the whole surface is covered. Great stress is laid by M. Hallopeau upon the fact that the eruption had occurred in acute outbreaks, which were attended by fever.[1] In the first instance these outbreaks had been of almost daily occurrence, and the itching and fever would subside in from twelve to twenty-four hours, but of late they had been less frequent.

Cases Described by Dr. Tilbury Fox.

Dr. Tilbury Fox, in describing his case (*Clinical Society's Transactions*, vol. viii.), made the following statements: His patient was a healthy child of seven months. The eruption began when the child was six weeks old, in the form of two places on the inner side of the left thigh just above the knee. They looked as if the skin had been scorched. The next part of the body attacked was the neck, and then the trunk. Finally, all parts, including the scalp, the soles and palms and the penis were affected, and the infant was "spotted all over like a leopard." New spots itched somewhat, but the older ones caused no inconvenience.

In this instance the history of local beginning and of gradually advancing attacks on distant parts is more suggestive of insect-bites than of any other cause. The child remained under observation for a year and a half without material change.

Dr. Fox refers in the same paper to two other cases, which apparently occurred in private practice and in infants born to upper-class parents. It is significant that in these there is no mention of recurring attacks, and that the eruption was scanty, only twenty to forty blotches; and further, that in both cases it seemed likely that the eruption would in time wholly disappear "under tonics and alteratives." These facts would fit well with the suggestion that a single cimex had been introduced into the house by the wet nurse and had perished after its first campaigns on the infant's skin.

Need for Portraits Illustrating the Results of Insect Bites.

It is somewhat surprising, considering the zeal with which skin diseases have been studied in recent years, and the industry of dermatological artists, that no one has thought it worth while to collect graphic illustrations of the eruptions caused by insects. The recognition of these elementary lesions must surely be admitted to be of great importance, yet none of our Atlases give much help. Thirty years ago Dr. Balmano Squire thought it worth while to bring a *Pediculus vestimentorum* for demonstration to a meeting of the Pathological Society of London, alleging that he suspected that many of the members did not know what that parasite looked like. No doubt he had his justification, and good service was done by his insistence that what was known as "Prurigo senilis" was really, in most instances, due to lice. It would be well worth while at the present time to collect good delineations of the skin lesions which may be produced severally by the bites of bugs, fleas and lice. The drawings should be well authenticated in relation with their alleged cause, and they should display the various stages of each lesion. We have in preparation for this Atlas a very instructive plate representing several different forms of lesion which were known to have been due to flea-bites. The severity of the dermatitis would astonish any one not experienced in such matters.[1]

[1] The occurrence of febrile attacks is no argument against the suggestion of bites. Children have been made seriously ill by visits to the Zoological Gardens. In a recent case in which the writer was concerned, on two occasions a consultation was put off by telegram because the child had a fresh outbreak and was too ill to travel. The attacks were attended by fever and vomiting, yet they were certainly caused by flea-bites.

[1] Should any of our readers possess good drawings illustrating the results of insect bites of any kind, the Council of

It is possible, however, that unwittingly a number of good representations of these eruptions have already been published. Thus the coloured illustration to Mr. Morant Baker's case, given in the *Clinical Society's Transactions* of 1874, certainly represents well appearances which are not uncommon as the result of bug-bites. The patches are blotchy, ill-defined, and not rounded, and they evidently leave stains very like those from ecchymoses. They are quite different from the wheals caused by fleas. Mr. Baker's patient was a healthy year-old infant, and the spots had been present since the age of six weeks, when they began as small red pimples on the back. These were followed by others on other parts; the face was attacked last of all. During the last few months no fresh spots had been produced. The buttocks and back were covered, but the regions of the arms and the palms and soles were avoided.

In like manner, the portrait given by Dr. Crocker as Urticaria papulosa, and that by Jacobi as Chronic Urticaria of children, may both be claimed as not improbably representing the results of the presence of lice on the skins of children.

That of Urticaria pigmentosa in Jacobi's Dermocromes scarcely justifies any diagnosis, but may be supposed to represent bug-bites more nearly than anything else.

In the absence of all history of the case it is difficult to avoid a suspicion that Kaposi's Tafel, 287, named "Purpura urticans," represents the bites of some insect. In many of the blotches a central puncture appears to be well represented. The blotches are in very various stages, for the most part quite discrete, and they are not arranged in any order.

Imperfectly Developed Cases.

In connection with the suggestion which has been made that urticaria pigmentosa is only a very exceptional result of the bites of different insects, the further suggestion will occur that there ought to be a great many imperfectly developed examples of it. Most probably there are, but their cause being suspected they but rarely come under the notice of medical advisers. The following facts from the note books of the writer may perhaps be worthy of mention, as illustrating this branch of our subject.

Generalised Urticaria leaving Stains.

The case of a little boy, aged 6, was introduced to me in October, 1894, by a letter containing the following passage: "This little patient has been under my care for the past two or three years, and the present is his second severe attack of skin trouble. The eruption appears to be a combination of urticaria and pemphigoid spots which leave a brown stain behind them." The mother of the boy told me that she herself was very liable to nettlerash, and always had it if she took shell fish. In the boy shrimps always made the skin irritable, and once after taking them he had been kept awake all night. Oatmeal porridge was believed to have the same result. The boy was liable to diarrhœa and bronchitis, and very susceptible to cold. Although his urticaria undoubtedly left yellow stains which lasted for some time, it could scarcely be claimed that his condition amounted to urticaria pigmentosa, and it will be observed that he had experienced only two bad outbreaks. It must be left in doubt whether these attacks were due to some article of food or were caused by bites.

Urticaria Perstans in Three Sisters (Jewesses).

In 1874 and previous years I had under observation, in succession, three children in a Jewish family who suffered from what I then called "Prurigo urticans." In two of them it had begun in early infancy, and persisted in successive attacks for several years. The face was affected, and the wheals usually appeared in the night. They resembled nettlerash. The application of tar washes to the skin appeared to be of benefit, and in all three, as years advanced, the liability seemed to cease.

---

the Society will be much obliged by permission to copy them. The plan of the Atlas will permit of recurrence to the topic, and good illustrations of these important lesions will be much valued.

I have no doubt that I should now diagnose bites, indeed, there was at the time a strong suspicion in this direction.

Urticaria Perstans in Two Sisters (Jewesses).

In another instance two sisters, Jewesses, one three and the other two years old, suffered severely from urticarious eruptions, usually made worse at night, but sometimes absent for months together. Bullæ were present on hands and feet, and the hips were severely affected. The children were continually scratching and rubbing, and some of the wheals had become pustular. They were both in good health (1891). I suspected insect bites.

Urticaria Perstans tending to become Pigmented and to assume a Keloid Condition.

Miss P., a healthy girl of 14, was under observation in October, 1894. Her ailment consisted in a very pruriginous eruption, which was arranged in lines and irregular groups, and was most severe on her legs, thighs, and sides of chest, but occurred more or less on most parts. The papules were of a dusky tint, and some of them very hard. She dated the eruption about eighteen months back, when it began, she thought, after an attack of rheumatic fever. She stated, however, that from the earliest childhood she had suffered severely from flea-bites, as did also one of her brothers. Her only reason for not regarding her present papules as flea-bites was that they lasted so long; some on her forearms had been present, she felt certain, for at least six months. The eruptions had developed, as usual, in successive crops. Some of the papules were abraded by scratching.

Flea-Bite Urticaria attended by severe Febrile Disturbance.

Whilst these pages have been passing through the press two cases of great clinical importance have come to the knowledge of the writer. In one, communicated by a surgeon, the father of the patient, a child of 5 (one of five) is liable to severe constitutional disturbance when attacked by fleas. On several occasions her skin has been covered with an urticarial eruption due to this cause and there is usually febrile illness with temperatures above 102°. The fleas have repeatedly been caught, but whether they are those from dogs, or those from the human subject has not been determined. The patient's sisters suffer little if at all, but one of her grandmothers and one of her cousins are known to have been liable to be victimised with almost equal severity with herself.

In the second case a little boy of delicate skin has huge wheals form as the result of flea bites and is usually confined to bed a few days with sickness and high temperature. In him the wheals often vesicate.

Does Urticaria ex causis externis become Generalised?

The question as to whether urticaria, when produced by stings or bites, ever spreads to a distance from the part injured is of some importance in reference to diagnosis.

The author of the text to Jacobi's atlas asserts broadly that it does, but the statement is open to much doubt. Experiments with nettles might easily be tried.

The reporter to one of our Journals is responsible for the statement that "Dr. F. J. S. described an attack of urticaria from the bite of a jelly fish. Large wheals were raised on one arm, but intense irritation was felt on the entire body surface." It is, of course, absurd to speak of a jelly fish as biting, and nothing is more probable than that the body of the bather was touched at more places than one.

It is probably the fact that the wheals produced by nettles, insects, &c., remain restricted to the parts irritated. The adjacent skin may become erythematous and more or less irritable, but the irritation does not usually spread widely, and no wheals are developed at a distance. We may probably rely with much confidence on this fact as enabling us to distinguish between Urticaria ab ingestis and that from local causation.

CASES OF WHICH PORTRAITS ARE GIVEN IN ATLASES OF SKIN DISEASES.

In Kaposi's atlas we have the following three portraits illustrating Urticaria pigmentosa.

Tafel 352. The back of an adult woman with dark hair. The pigmented areas are in this case arranged in streaks and flecks. They are most abundant across the loins.

Tafel 350 represents the front aspect of an adult man in whom the eruption occurs chiefly on the chest, upper limbs, and front of thighs. In the absence of history the portrait is of no value. It is designated "Urticaria hæmorrhagica et pigmentosa."

Tafel 351. This is a very well characterised representation of the ordinary form of Urticaria pigmentosa in a female child. The eruption occurs over the whole surface, including the face. The child is of fair complexion.

In Dr. Radcliffe Crocker's atlas we have the following:—

A lithograph from a case of Dr. Crocker's, showing the eruption in a tuberous form on the back and side of face and the back and arm of a young child.

A lithograph of a girl whose back is covered with the pigmented blotches. The eruption is seen also on the thighs and arms. The letters U.P. are written on her shoulders in demonstration of the urticarious irritability of her skin. Her hair is light brown.

A coloured lithograph, companion to the above, showing the front aspect of trunk, arms and thighs of a young woman. The word URTICAIRE is written across the abdomen. Arranged in very accurate symmetry on the forearms, chest, and front of thighs, there are rounded areas which are white in the centre and have dusky borders. They occur in groups. There are no pigmented papules.

Reference has already been made to the portrait published in the Atlas of Selections from the St. Louis Collection. This atlas was edited by Dr. Pringle, and published by the Rebman Company. This portrait, taken from a wax model, is by far the best in which the phenomena of this eruption have as yet been portrayed. At the same time, it is to be observed that it probably shows an earlier stage in most of the spots than is exhibited in the majority of other portraits. The eruption is distinctly urticarial, showing raised wheals, whereas most others show rather the stains left by wheals which have long ago subsided. Many of the papules are exactly like those of recent bites, whereas others, in long streaks, resemble the factitious urticaria due to the patient's scratching. It is a pleasure to praise the beautiful plates contained in this atlas. They are so life-like that the clinical observer has the means supplied for forming his own diagnosis.

PLATES CXVIII. AND CXIX.

URTICARIA PIGMENTOSA IN A BOY.

This case is of especial interest because its subject has again come under our notice after an interval of ten years, and we are able now to give (see plate H) a good photographic illustration of his present condition. The spots at the present time have entirely disappeared from the face. Although very much diminished from the trunk they are still conspicuous, and are an annoyance to the lad, from making it disagreeable for him to bathe in public; otherwise he has no sort of trouble from them. They are not in the least irritable. There has been no tendency to the production of new spots for many years.

The particulars of the case are as follows :—

M. S., a Jew boy 6 years old, of respectable parents, was brought to Mr. Hutchinson in March, 1892. He was a rosy, healthy looking boy. The history given was that at the age of six months he had a temporary eruption, after the partial disappearance of which the skin remained very irritable and recurrences of eruption repeatedly occurred. For long he was covered with papules, which in consequence of his scratching often acquired crusts. Of late no new spots had come out, but the stains remained. The eruption had been most abundant on the trunk and back of neck.

The eruption was a well characterised Urticaria pigmentosa with a few round, whitish, superficial scars. The conditions being well shown in the portraits need not be described. The face was covered with spots.

The case was a well characterised one of Urticaria pigmentosa and the parents kindly allowed the boy to attend repeatedly at Park Crescent for purposes of demonstration. During a year there was no material change in the symptoms, and as the eruption gave no trouble, no further treatment was attempted, and the boy was lost sight of. It was through the courtesy of Dr. ——— that he was brought to the Polyclinic in October last, 1903, and an opportunity thus afforded of observing his present condition. The fact that the eruption had entirely disappeared from his face led to the question whether exposure to sun had been beneficial, and it was suggested that the Finsen light treatment should be used for the spots remaining on the trunk. They gave, however, so little trouble, that it seemed scarcely worth while to adopt this measure. The patient is now a well-grown young man, and he has throughout enjoyed excellent health.

This case affords a good illustration of what is common in Urticaria pigmentosa—that the eruption is produced in successive crops during the years of infancy or early childhood, and that the tendency to it then ceases. Not only are no further additions made, but the lesions already present tend to slowly disappear, leaving the face first. It is possible that the irritation of clothing may do something to perpetuate those on the trunk.

(*See also Plates CXIX. and H*).

West, Newman chromo.

PLATE CXIX.

URTICARIA PIGMENTOSA IN A BOY.

This portrait is from the same patient as the previous Plate. His present condition is shown in Plate H after an eleven years' interval.

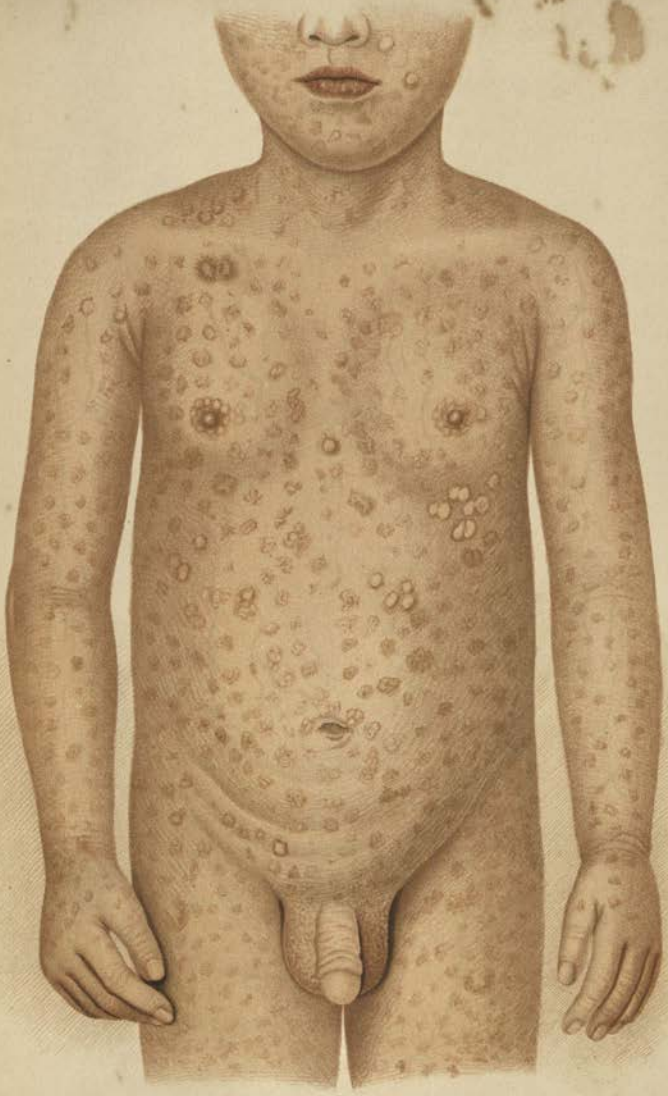

West, Newman chromo.

PLATE CXX.

URTICARIA PIGMENTOSA IN A YOUNG MAN.

The patient whose portrait is given in this and the following Plates attended repeatedly at the Polyclinic, and was the subject of demonstration. His case differed somewhat from what is usual, in that the liability was asserted not to have been observed in infancy. The following notes were taken on November 1, 1890 :—

He is a tall, spare lad, aged 19, and of Jewish birth.

The eruption, according to his account, began five years ago on the body. At the age of 14 he was in the London Hospital with a badly sprained ankle, and he is sure that he had no eruption then. He thinks that it did itch at first, although it does not now. He showed it to his mother, who said that "it would go as it had come, and that he need not mind it." After a little time it came on his face also. He thinks that it had been on the body three or four months before it appeared on the face.

It has never affected the scalp or the palms, but has appeared on all other parts of the body and limbs, even on the soles of the feet. In the latter position the papules are devoid of colour and are whiter than the surrounding skin. They occur just under the instep and not on the sites of pressure.

In the first instance we demurred a little as to diagnosis of Urticaria pigmentosa, for no fresh wheals were ever observed, and the eruption did not itch materially. Careful investigation was made as to any syphilitic antecedents, but with quite negative result, and the alleged long duration of the eruption seemed conclusive on this point. After the case had been for a year under observation, and we had repeatedly demonstrated that factitious urticaria could easily be produced on the skin, and that the eruption showed no tendency to change its character, all became convinced that no other diagnosis could be given. It was on account of the disfigurement of the face that the lad sought advice. He was in good general health, and the eruption on his body gave him little or no trouble.

It will be seen in the portraits that the papules are only of small size. They were, however, exceedingly numerous, and their general features were exactly similar to those of other cases. They were of a dusky brown tint rather than yellow, their deep colour being not improbably determined by the complexion of the patient, which was very dark.

It is not without interest to note that the subject of this portrait, as also that of the previous one, were Jews, and more than one of the appended case-narratives concern members of the same race.

West, Newman chromo.

PLATE CXXI.

URTICARIA PIGMENTOSA IN A YOUNG MAN.

A front view of the same patient as illustrated in the preceding Plate. The papules are not shown of sufficiently deep tint. For remarks as to their grouping see other Plates, especially Plate G.

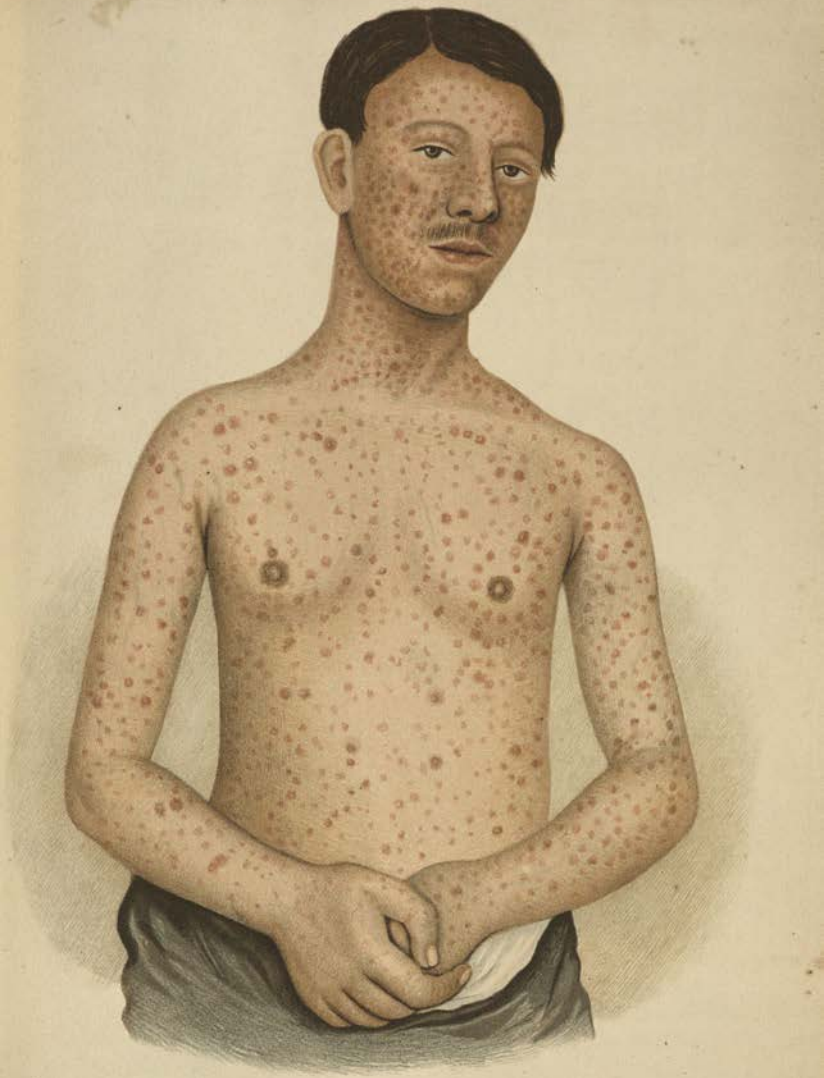

West, Newman chromo.

PLATES E AND F.

URTICARIA PIGMENTOSA IN A BOY.

These portraits are taken from a paper by Mr. Brougersma in the *British Journal of Dermatology*. They represent the whole surface as covered with deeply coloured papules, which are especially abundant on the lower extremities. The patient was a lad, aged 16, in whom the eruption was said to have commenced at the age of six weeks. In early life it was said to have come out in successive crops, and had been attended with much irritability of skin. There was some liability to factitious urticaria. The tendency to fresh crops had ceased at the time the portrait was taken, and the lad was in excellent health. Some slightly marked scars had been left, although there had never been any ulceration.

The portrait is chiefly of value as showing the distribution of the eruption, and the case illustrates the general fact that whilst the liability to new wheals usually comes to an end at or before puberty, the pigmented spots may persist long afterwards, with but little change and without any interference with the health.

PLATE F.

URTICARIA PIGMENTOSA.

Back view of the patient represented in preceding Plate showing the constellation grouping of the eruption.

[The blocks for this and the preceding Plate have been kindly lent by Dr. Galloway, under whose care the patient was; they had been previously used in the *Dermatological Journal.*]

PLATE G.

URTICARIA PIGMENTOSA IN A GIRL

This portrait is copied by permission, Plate XXII. in Dr. Prince Morrow's valuable System of Dermatology. It is of interest chiefly as illustrating the arrangement of the spots in the disease under consideration, and as proving that precisely the same phenomena are observed in the United States as in Europe.

The patient was under the care of Dr. George Henry Fox, for whom the photograph was taken. The facts as regards the development of the eruption were much the same as those in other cases. The commencement was in very early infancy, and the spots multiplied in successive crops. It will be seen that, although the eruption is bilateral and general, the arrangement is not accurately symmetrical, and that there is nothing suggestive of infection from one spot to another or of nerve distribution. The arrangement is quite irregular, and is that to which the term "constellation pattern" has been applied. The child is well nourished, and was in good health.

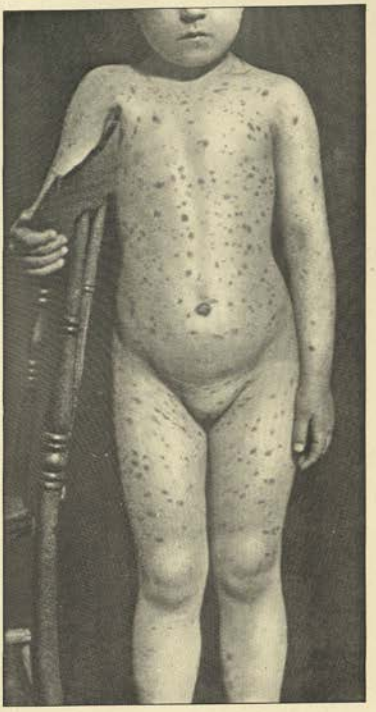

PLATE H.

URTICARIA PIGMENTOSA IN THE RECEDING STAGE.

This photograph represents the present (Oct., 1903) condition of the patient whose earlier state is shown in Plates CXVIII. and CXIX. The eruption has entirely faded from his face but still persists on the trunk. The spots are, however, everywhere smaller in size and more faint in colour. For more than ten years no fresh spots have appeared. There is but very little tendency to factitious urticaria. The youth has been throughout in excellent health.

The face as shown in the photograph is indistinct, having been out of focus when the portrait was taken. It was quite free from conspicuous spots.

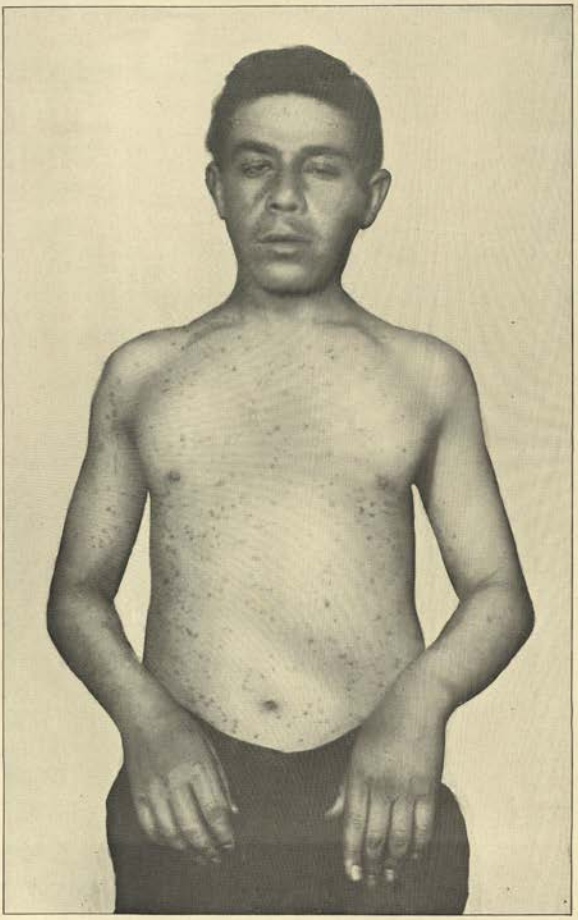

ILLUSTRATIONS

OF

THE PRINCIPAL PHENOMENA OF

LEPROSY.

INTRODUCTORY STATEMENTS BY THE EDITOR, PAGES 95 TO 98.

(Coloured)

PLATE CXXII.—Diffuse Leprosic Dermatitis in the stage of Resolution.
" CXXIII.—Diffuse Leprosic Dermatitis in the stage of Resolution.
" CXXIV.—Leprosic Neuritis (External Popliteal Nerve).
" CXXV.—Diffuse Leprosic Dermatitis with Swelling of External Ear.

(Without Colour)

" I.—The Macular Stage of Leprosy.
" J.—Vesications in Hands, &c.
" K.—Ulnar Nerve Paralysis.
" L.—Neuritic Leprosy in late Stage.
" M.—Paralysis of both Facial Nerves.
" N.—Neuritic Leprosy: Facial Paralysis.
" O.—Perforating Ulcers of Sole of Foot.
" P.—Early Stage of Tuberous Form.
" Q.—In an Advanced Stage of Tuberous Form.
" R.—Advanced Stage of Tuberous Form.
" S.—Advanced Stage of Tuberous Form.
" T.—Ulnar Paralysis with Acroteric Mutilation.
" U.—Tubercular in Receding Stage.
" V.—Mixed in late stage
" W.—Fusiform Enlargement of Nerves in Upper Arm.
" X.—Fusiform Enlargement of Nerves in Leg.
" Y.—Fusiform Enlargement of Nerves in the Foot.
" Z.—Two companion portraits of the same patient before the development of Leprosy and three years after it had commenced.

ILLUSTRATIONS OF LEPROSY.

Definition.

Leprosy may be defined as being:—*A long protracted, often fatal, but self-terminable bacillary disease, in which the peripheral nervous system and the skin are chiefly affected and loss of sensation, muscular paralysis, erythematous tumefaction of the skin and acroteric necroses are the usual phenomena.*

Pictorial illustrations of leprosy are very plentiful. The conditions displayed in aggravated cases are very conspicuous and lend themselves readily to the photographer and to the artist's pencil. For the most part, however, only aggravated cases are selected and it is the so-called tuberous form which is almost invariably delineated. Thus the leonine physiognomy, with its repulsive hypertrophies, has assumed a very false position in the imagination of those not personally conversant with the disease. It is thought to be the ordinary characteristic of the malady, whereas it is a comparatively rare one and always a transitory stage. There is in the present day no object in attempting to multiply representations of this condition. Our endeavour in selecting the subjects to be presented in this Atlas will be to illustrate typical forms of the different lesions and such as have direct bearing upon the pathology and mode of evolution of the malady.

The first, and perhaps still the best Atlas of leprosy portraits, was that given in the work published by the renowned observers Danielssen and Boeck. Since their time, Dr. Hillis has given in his work on the disease as observed in British Guiana, some graphic and well selected portraits. Prof. Léloir's portraits and those of Turck are also very valuable and finally the Atlas recently published by Dr. Grünfeld may be said to afford the reader almost all the advantages, without the trouble, of a visit to a leper home. This work comprises photographic portraits of 100 lepers in all stages of the disease, with brief particulars regarding each case. It deals with leprosy as observed amongst the fishermen near the mouths of the Don. From most of these sources, we have selected illustrations for reproduction in the present work. It may be for the reader's convenience if we commence by some brief general remarks as to the phenomena of the disease.

THE PHENOMENA OF LEPROSY.

It is a mistake to suppose that leprosy is always attended by great disfigurement. In its early stages in almost all cases there is little or none. These early stages often extend over several years, and during them the leper may mix with his fellows without the slightest risk of recognition, and he usually continues to enjoy good health. It requires a skilled observer and a good opportunity for observation to recognise the disease in such cases. In some the patient never gets beyond that stage and may recover without its ever having been discovered that he was the subject of this terrible malady. In others, and the majority, the course is, however, different.

The ordinary phenomena of the disease may help us somewhat in our conjectures as to its real nature. They are usually—perhaps invariably—displayed in the first instance by the

skin, but very important implications of nerve trunks follow in a large majority of instances. It may be safely believed that when such is the case the nerve trunks usually receive their infection from the skin originally affected. The progress is that of an ascending neuritis. Briefly, then, it may be said that the first symptom implying the presence of leprosy is the appearance of dusky brown patches on the skin. In a white person and on the trunk, the patches often look much like those caused on a sheet of paper which has been scorched. A single one may be present for a long time before others appear, but more usually many are developed together and they are usually arranged with fair bilateral symmetry on the trunk and four limbs. These patches are not at first deficient in sensation, but after a time white areas begin to appear in their centres, and where whiteness occurs there sensation is usually more or less completely lost. In many cases before this stage is reached the patches have coalesced, and the entire surface has become of a dusky *café-au-lait* tint. In these discoloured and erythematous areas, the skin is a little swollen, but often not so much so as to attract notice. In some cases, however, and especially on the face and hands, it is very greatly thickened and may be thrown into nodular folds.

The parts which are exposed to the sun and air—the hands and the face—often suffer in a manner peculiar to themselves. The thick skin of the face, as might be expected, shows the increase of thickness more conspicuously than other parts, and the features are greatly changed, more especially the sides of the nose, the eyebrows, the lobules of the ears and the lips; all these parts become tumid and firm. The hairs of the face and especially those of the eyebrows, fall out. The lumpy thickening of the parts just named so changes the features that a child may come to look like an aged dwarf. It is quite impossible to guess at the age of a leper in whom the face is affected. The hands and feet rarely show the brown discolouration which is so characteristic on the trunk. Owing to the feeble state of the circulation in them they usually become livid and dusky rather than brown. They are, however, always somewhat swollen and look clumsy. No doubt the process in them is the same as in the other parts, but it is modified by local peculiarities. There can be little hesitation in believing that the process is one of dermatitis, involving destruction, to greater or less extent, of the tactile organs of the skin (the "end-organs"), for as the swelling subsides, the parts are left defective in sensation. A leper in this condition may burn or cut his fingers without knowing it, or he may have sores form, or portions of his digits drop off without experiencing pain.

The loss of sensation and of perception of pain and of temperature, which are such well-known and common conditions in leprosy, may be brought about in two different ways, which it is important to distinguish.

It may be caused by damage to the end-organs in the skin itself, or by damage to the nerve-trunks. As already suggested, the trunks suffer secondarily and the end-organs are probably infected before them. In some cases the nerve trunks suffer but little, or it may be that they appear to escape. The severity of the skin affection is no measure of the risk to the nerve trunks, but rather the reverse. When loss of sensation in the skin itself results from damage to the end-organs, it may be compared to loss of sight from disease of the retina, and when it is from damage to a nerve-trunk it resembles blindness from injury to the optic nerve. In leprosy, however, the two conditions are usually present together, the one leading to the other. They may, however, be discriminated to some extent by their results, for the one leads to general and diffused numbness of the whole surface, often without any degree of muscular paralysis, whilst the other affects certain known regions of nerve-distribution, and is always, when the nerve is a mixed one, attended by corresponding muscular failures. A leper in whom the skin only has lost sensation, but whose muscles have not failed, and who retains the muscular sense, may be able to use his hands, and even manage carpenters' tools; but one in whom the muscles have suffered is deplorably helpless.

The statements which have been made apply chiefly to the early and middle periods of a leper's career. They are often the only ones, for contrary to general belief, leprosy may be arrested at any stage, and is by no means a necessarily fatal malady. If all lepers could be liberally fed and cared for, probably but few would die of the disease itself. Unfortunately, however, in the majority these conditions are not to be obtained and various complications may ensue which entail very serious results.

Following what has just been said it is very important to point out that although the leprosy processes are usually very slow, they are seldom stationary. They are either aggressive or retrogressive, and there is, if the patient survives, a very definite tendency to recovery so far as the destructive changes already accomplished may permit of it. The soundness of the cicatrisation which results, is often very remarkable and also the extent of restoration of nerve function. These facts strongly support the suggestion that the parasitic bacillus cannot maintain its activity in the same tissues indefinitely. The phenomena of leprosy are, as we have endeavoured to explain, the combinations in varying proportions of the results of dermatitis and of neuritis. Some of these results are primary or immediate, and others are remote or secondary. We may fairly grant that the bacillus may be present in the tissues without evoking symptoms either in the skin or nerves, and without causing inflammation of any kind. Probably it is so in many cases, and during very long periods of time. But of such conditions we know of no symptoms, and it is probable that none are produced. It is only when the bacillus assumes activity, and when either by itself or its toxine it begins to cause local symptoms, that we recognise its presence. When that stage is reached it is probable that its multiplication is usually rapid, for the phenomena in most instances are those indicating its general diffusion. They would seem to imply its presence in the blood either free, or as is more probable, in the white cells.[1]

[1] Hansen, and other observers, have both described and figured the bacillus in the blood.

The facts as regards bilateral symmetry imply blood poisoning, whilst at the same time they by no means exclude the occurrence of diffusion by the lymph channels, or of direct communication by continuity of tissue. Probably all three are in force at the same time and in all cases. The enlargement of lymphatic glands and the demonstrated presence of the bacillus in them proves the one, and the serpiginous extension of patches on the skin, and the fusiform swelling of long tracts of nerve-trunks implies the other.

In all cases, if carefully looked for, the phenomena of both neuritis and dermatitis will be found together, and that, too, almost from the beginning of the illness. They may occur, however, in very varying proportions, and present very different resulting conditions. The bacillus would appear to have a special tendency to attack the areolar investments of the peripheral nervous system, and to produce, probably by pressure, interruption of function; or it may be permanent disorganisation, more or less complete. We do not as yet know much as to the pathological process in the end organs of the skin—the dermato-neuritis—but numerous observers, beginning with Danielssen and Boeck, have recorded detailed observations on that of the nerve-trunks. Many authors have written as if they thought that the anæsthesia so commonly displayed by the skin in leprosy were always and solely the result of neuritis of nerve trunks. It is from it that the classification of leprosy into the "tuberose" and the "anæsthetic" groups has so long maintained its position. There cannot, however, be any reasonable doubt that all forms of leprosy are attended by some degree of anæsthesia, nor that there are, as has been stated, two quite different modes in which such anæsthesia may be produced. Peripheral neuritis, by which we may mean inflammation of nerve trunks, is only one, and it is perhaps of less importance because less nearly universal, in leprosy than is dermato-neuritis, or destructive implications of the nerve structures in the skin itself. The skin is, indeed, an outspread organ of sensation, and as has been suggested its sensory functions may be dis-

turbed in modes just as distinct and as widely different as are choroido-retinitis and optic neuritis in the case of the eyeball.

It is probable that no form of leprosic dermatitis leaves the skin intact as a sensory organ. The degree of loss may fall far short of complete anæsthesia, and may even be so slight as to be difficult of demonstration, but it is always present.[1] Now as there are many different forms of dermatitis in leprosy, so there are different distribution areas of the resulting paræsthesia. In some it is in well-margined patches, distributed either with symmetry or without, and in others it is either acroteric or obscurely diffuse, whilst in a few it is almost universal.

The differences which leprosy assumes in different cases may be assumed to be due chiefly to differences in the constitutional proclivities of the patient rather than to the bacillus itself. The latter is always essentially the same. It may be admitted, however, as not improbable, that after it has entered into symbiotic union with the cell elements of any one tissue it will tend more or less to restrict itself to that tissue. This is the pathological law under which we seek to explain the permanent differences in the several lupoid forms of tuberculosis of the skin, and it probably applies also to leprosy. The type once taken is kept to. Under this law —if it be one—the bacillus having once commenced its life-activity in a certain structure, will there produce infective cells, which will by preference develop themselves in tissues of precisely the same kind, it may be on exactly the opposite half of the body. If a nerve trunk have been attacked other nerve trunks will follow suit. Thus a certain sameness of type is often preserved throughout the case.

Although we assume that the lepra bacillus is the final cause of leprosy, and that it is present in all cases and in all lesions (that is, in their early stages), yet it is undoubted that its abundance and its energy of multiplication are very different in different forms. In the cases to which the terms "tubercular," "tuberose," "nodular," &c., are applied it is usually very abundant, whilst in those which approach the type of the "purely neuritic" it is often only scanty. In the former there is often much œdematous swelling of the parts affected, in the latter but little, or even none. In the former, the mucous membranes and internal viscera may be infected, in the latter they usually escape. A liability to ulcerative destruction of parts occurs in the former, leading to crippling of hands and feet, &c., whilst the latter are liable to muscular contractions and to the mutilations from gangrene and from loss of bones, which are the secondary and remote consequences of severe damage to nerves. The conditions referred to are, however, often inextricably mixed, and no strong lines of demarcation can, consistently with clinical truth, be drawn. Even the time-honoured and usually accepted division into "tubercular" and "anæsthetic" is an arbitrary one, and is productive of much misconception. As being to some extent convenient in a popular sense it will probably continue to be employed, but all clinical observers aiming at accuracy and clear ideas ought to lay it aside.

[1] It may be well here to remark that uneducated persons are prone to deny all slight degrees of anæsthesia. If they can feel at all they assert that they can feel well. It requires great patience and plenty of time to make certain on this point in many cases of leprosy.

PLATE CXXII.

LEPROSIC DERMATITIS IN THE STAGE OF RESOLUTION.

In this plate we observe the conditions produced in the receding stage of diffuse leprosic dermatitis. The whole extremity had at an earlier period been of a dusky brown tint and slightly swollen. Upon this areas of white had appeared, which by gradual extension had left only irregular patches and streaks which retained their colour and were still somewhat thickened. Sensation was very defective, though not absolutely lost wherever the skin had become white. On the patch near the elbow the thickening of the still swollen skin was not less than the eighth of an inch, and the decolorised areas were correspondingly depressed. The thumb and the two radial digits were in a similar but less marked condition. At the upper part of the arm the œdematous erythema was attended by still less tumefaction.

It will be observed that the little and ring fingers are bent forward into the palm. This was the result of muscular contraction from neuritis of the ulnar nerve, and the digits concerned were also wholly anæsthetic. Thus the conditions of neuritis and dermato-neuritis co-existed, as is very common. The phenomena of neuritis had been those which first attracted attention, and the boy had been under treatment for a year or more at a special hospital for "peripheral neuritis" without any suspicion of leprosy. His face was at this stage only dusky and a little tumid, but some years later it developed the leonine expression and was deformed by thick folds and tubercles of the most exaggerated type. This aggravation on the face occurred at a stage when the disease was receding on the trunk and limbs.

The patient (a boy who had been born in the West Indies), lived in London for about eight years after the commencement of his disease, and finally died with albuminuria and symptoms of chest mischief.

The case afforded an excellent example of tubercular lesions developing long subsequent to those of neuritis and diffuse dermatitis.

The conditions shown in the plate are not frequent ones and are such as are very likely to cause difficulty in diagnosis. Some excellent illustrations of conditions precisely similar to those shown in this Plate are to be found in other Atlases. We may refer especially to Portrait XLI. of Dr. Grünfeld's (of Odessa) Atlas "*Die Lepra in Dongebiete.*" It is an almost exact reproduction of the conditions which we have shown. The case was that of a man who had both macular and nodular lesions. The man's back shows plenty of patches but they are not attended by the great thickening which characterises those on the arms. This excessive amount of œdematous tumefaction of the skin usually characterises a severe form, and one in which the face is very likely to show nodulation.

West, Newman chromo.

PLATE CXXIII.

LEPROSIC DERMATITIS IN THE STAGE OF RESOLUTION.

The full particulars of this case may be found in Vol. i. of the "London Hospital Reports."

Like the preceding plate, it exhibits a slightly swollen, dusky condition of the skin, upon which abruptly margined areas of white have been formed. The process illustrated is not unlike that of Leucoderma. The white patches were aggressive, and they were destined ultimately to cover the whole surface.

The following details of the case are taken from the report just mentioned.

CASE I.—*Anæsthetic and tuberculous leprosy in a sailor, who had voyaged to the West Indies during many years.*

A well-built, intelligent sailor, born in Scotland, now aged 56, was admitted to the London Hospital in October, 1863, on account of an accident. He presented an excellent example of the anæsthetic form of leprosy, and my colleague, Mr. Adams, whose patient he was, was kind enough to permit me to investigate and record his case. Excepting the special disease from which he suffered he appeared to be in good health, being active and energetic. His voice was rough and hoarse. His face was covered with thick bossy folds of dusky and tumid integument, between which the skin was thin and pale. On his arms were large patches of bluish-white skin decidedly thinned, and in most places quite without sensation. Between these patches the skin was raised, thickened, hot, hyperæsthetic, and of a dusky livid colour. He complained much of "numbness and pins and needles" in his hands and feet, and the skin of these parts, especially of the fingers and toes, was thickened. These raised patches and folds of skin could scarcely be described as tubercles, either on his face or hands.

The state of the skin on his left thigh is well illustrated in a coloured portrait which was taken. It was very similar to that of the skin of his upper arms. The white anæsthetic portions made up the larger half of the surface. On these he could not feel when a pin was thrust into the skin. Between them the skin was thickened and of a brownish tint, being also exceedingly tender. The commencement of the change to the white condition appeared to be very gradual. On one occasion, whilst testing his power of sensation, I touched with the compass points a part on the upper region of the thigh which I believed to be yet unchanged, but to my surprise he said he could not feel. On looking more carefully I found that it was decidedly white and had an indistinct margin, but the change was so slight that it might easily have escaped notice. There was no doubt about it when once seen, and I demonstrated it to several students who were present.

The man stated that the disease had begun about a year and a half ago. He had for nearly thirty years sailed regularly to and from Barbadoes. His custom was to remain there about six weeks each voyage. During his stay there he always lived on his ship. He could not suggest any clue to the cause of his malady. He averred that he had never drunk spirits immoderately, nor ever suffered from syphilis. He was married, but had no family. He considered himself in excellent health when the disease began, and indeed should be so still "if he could only get rid of the pain and numbness in his skin." His muscular force appeared to be fairly good. He had no bullæ nor any scabs.

It is certainly difficult to conjecture as to what special endemic influence, excepting that of food, this man could have been exposed to. He had never associated with lepers. He had never lived on shore, nor ever stayed in port more than six weeks at a time. His frequent change to a healthy climate and his exposure to sea air had not sufficed to prevent the development of the disease; and from its still aggressive severity it seemed probable that it would run the usual course, with at least average rapidity.[1] (The sequel is not known.)

---

[1] Danielssen and Boeck assign nine years and a half as the average of the tuberculated or cutaneous form, and eighteen years as that of the anæsthetic. It would appear to be, sometimes, a more acute disease in India. In a case recorded by Dr. Carter the latter form ran its course and ended in death in eight months.

West, Newman chromo.

PLATE CXXIV.

ATROPHY OF EXTENSORS OF THE LEG FROM LEPROSIC NEURITIS OF THE EXTERNAL POPLITEAL NERVE.

Next to the ulnar nerve the external popliteal is perhaps the one most frequently involved in leprosic neuritis. Its implication involves all the muscles supplied by the anterior tibial and musculo-cutaneous. As, however, it is probable that the neuritis is an ascending one and begins from the integument, any of the branches may be affected separately. The portrait shows wasting of the anterior tibial muscles in the right leg, and at the same time a dusky dermatitis of both feet. The shrunken condition of the affected leg in comparison with its fellow is well seen.

On the dorsum of the left foot, in addition to the diffusedly dusky condition, two patches of deeper tint, which are beginning to become white in their centres, are seen. Both feet were more or less numb, and the areas supplied by the affected nerve in the right leg were almost wholly devoid of sensation. The patient walked with a characteristic limp, owing to inability to clear the ground with his toes.

The subject of the case was a young man who had been born in the West Indies. He lived for some years in London and was engaged as a clerk in a public office. He was apparently recovering from his leprosy when suddenly brain symptoms were developed and he became comatose and died in the course of a week. The autopsy disclosed numerous scattered tubercular deposits in the pia mater.

It is of interest to compare this atrophy of the anterior tibial muscles as observed in leprosic neuritis with that which occurs in the peripheral neuritis of arsenical poisoning. Fig. 2 in Plate E from one of Dr. Reynold's cases illustrates the latter. It may be suspected that in both instances the superficial course of the nerve trunk, where it winds round the neck of the fibula, exposes it in some way to causes of inflammation.

West, Newman chrom.

PLATE CXXV.

This plate is given in order to exhibit the peculiarities of the swollen ear, which often occurs in leprosy. It is also of interest in illustrating their similarity to those of lupus. It differs from the latter however, in that every part of the ear is almost equally involved, whereas in lupus the swelling is often restricted to the lobule and adjacent parts. The dusky tumefaction, however, is remarkably similar in the two diseases, and in both it is always the lobule which is the most swollen.

The subject of this case was a man of European birth, who had lived several years abroad in a country where leprosy was prevalent. His symptoms had been present for two or three years, and were those of the earlier or macular stage. The whole of his face was of a dusky brown tint, and the portrait shows that the skin of his forehead, just over the nose, was somewhat thickened and thrown into wrinkles. His eyebrows were, however, not lost.

West, Newman chromo.

PLATE I.

THE MACULAR STAGE OF LEPROSY.

In this portrait, which is copied from a Bergen photograph, we have a good illustration of the macular type of leprosy. Large irregular patches with abrupt and slightly elevated borders are seen on various parts, being especially conspicuous on the buttocks and thighs. They are arranged with tolerable but by no means exact bilateral symmetry. It is of the type most nearly resembling a generalised eruption of Lupus vulgaris. The patches were probably aggressive and still advancing at their edges, and might eventually cover the whole skin.

This portrait is Plate IV. in the excellent account of leprosy which we have from the pen of Drs. Hansen and Looft, where it is given as a typical example of "Lepra maculo-anæsthetica." No details are there afforded respecting the individual patient excepting that the patches had been present for two years, and that the white centres and slightly elevated reddish edges were very well shown.

The following extract from the work referred to descriptive of this form (or stage) of leprosy will be read with interest.

"After a longer or shorter period the typical picture of the maculo-anæsthetic form develops, the spots either appear stealthily or they may appear all at once with marked fever. Several forms of the eruption are described by investigators; in our patients usually only the erythematous and the yellowish or brownish pigmented ones have been noted. Usually both forms are seen on the same patient, for the simple erythematous spots become in time more and more pigmented—usually only at the periphery, where a bluish-red play of colours is often seen. Those eruptions which are all along pigmented and which develop very gradually, we have particularly noted in the intercostal spaces. Various forms—round, oval, gyrate—have been observed. The patches may be perfectly flat, or slightly elevated. The size varies from that of a pea up to that of the palm of the hand, and they may be even larger. At the commencement we have usually found these patches hyperæsthetic, anæsthesia is only found in the older patches. They do not always at once attain their full size; we can often observe their growth; one may run into another, and then the initial form is lost. The number and extent of these patches are very varied; some patients present great map-like eruptions on the face, back, and extremities; in others the patches are few and scattered. The seat of these patches corresponds in general to that of the nodules, but the back and the intercostal spaces are frequently the seat of patches, while on these areas nodules are only rarely, if ever, present. Plate IV. gives a good picture of the patches in the maculo-anæsthetic form—duration, two years. The white centres and the slightly elevated reddish edges are very well shown. A symmetrical distribution of the patches strikes one, and has been regarded as indicative of a central localisation of the leprous poisons of which the patches are a tropho-neurotic, vaso-motor symptom; but in many cases there is absolutely no symmetry, and the discovery of bacilli in the patches themselves prove them to be the direct result of the action of the lepra poison. The lymphatic glands corresponding to the position of the patches are always swollen, and the swelling may persist long after the disappearance of the patches. The duration is very varied, some are gone in a few days or even less, others may last for years. Pigmentation of the periphery and pallor of the centre indicate that the patch is already old, and the pallid centre is always anæsthetic, the anæsthesia affecting all or only some perceptions. The signs which Hillis indicates as diagnostic of the patches of the anæsthetic from those of the tuberous form, we cannot recognise. The patches of the tuberous form are certainly usually thicker, indicating a greater degree of infiltration than the anæsthetic, but as both are caused by the lepra bacillus it is evident that they may be absolutely similar."

It is probable, but not quite certain, that the subject of this case was, at a somewhat later stage, the same with that of Léloir's Observation XXIX. They were at any rate closely similar cases. Léloir's notes record that the patient was a man aged 22, engaged (as most of the Norwegian peasants are) in fishing and farming. His eruption had commenced about three years ago on the extremities, but some patches on the face had followed soon afterwards. His father and a sister were also the subjects of leprosy, but his mother and a brother were free. He was in good health. The hairs were lost on some of the patches, but sensation on most of them was but little diminished. In the extremities it was not affected.

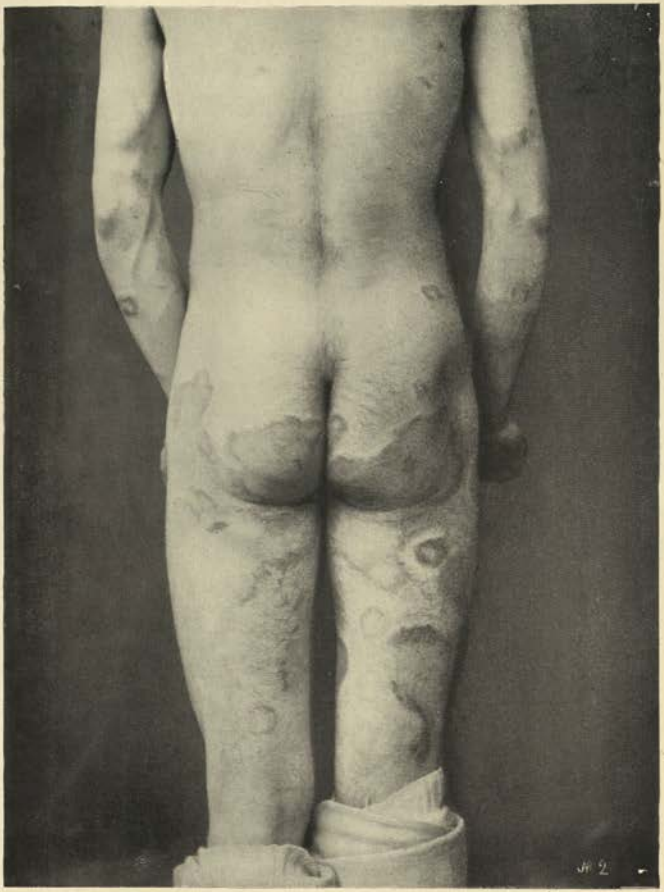

PLATE J.

VESICATIONS ON THE HANDS, &c., IN LEPROSY.

This plate, which is copied from a Bergen photograph, shows the vesications or bullæ which often occur on the hands of lepers. Some good observers doubt whether these are ever of really spontaneous origin, and believe that they are always preceded by some exposure to injury, especially to heat. It is certain that they are usually met with in association with great defect of sensation. In the present instance it will be observed that the location of the blisters might easily have been due to exposure of the backs of the hands for too long a time to the heat of a fire. There is no suggestion in their distribution that they had been located by nerves. There is no doubt that lepers do very frequently burn their hands unwittingly, and wholly without pain, and that vesications are a common result of such burns.

PLATE K.

STATE OF THE HANDS IN NEURITIC LEPROSY.

In fig. 1 of this plate we have the typical condition following leprosic destruction of the ulnar nerve. The little finger is strongly flexed and the ring finger slightly so. The whole hand looks thin. The muscular curve over the base of the little finger is wholly lost, and there is a deep hollow between the metacarpal bones of the index and the thumb. This latter feature, due chiefly to the wasting of the adductor pollicis, is one of the most conspicuous of those denoting ulnar paralysis. The ulnar nerve, as is well known, is the one which is usually first affected with leprosic neuritis, and often suffers almost alone.

In fig. 2 we have a good representation, from the palmar aspect, of all that is shown in fig. 1. The small muscles of the hand supplied by the ulnar nerve are wasted, and the ulnar finger strongly flexed. We have, however, in the flexed condition of the other digits, and the exaggerated hollows about the base of the thumb, proof that the median nerve, as well as the ulnar, had been severely implicated.

FIG. 1

FIG. 2

PLATE L.

NEURITIC LEPROSY IN A LATE STAGE.

This portrait is from a Bergen photograph and is also given in Léloir's valuable work. The patient was the subject of Observation XL. given at page 162. It is designated by the author, "*Lepra systématisée nerveuse; Atrophiés musculaires, Deformations des Extremités; Paralysie faciale double.*"

The wasting of the limbs and the clawed hands, with the entire absence of tubercular lesions are conspicuous features. There is but little in the man's face, excepting a slight drooping of the lower eyelids and an open mouth, that would suggest paralysis of the facial nerves. It is to be noted that there is no obvious mutilation of the hands.

The particulars of his case are published by Léloir. It was observed by him in the Bergen Hospital, where the patient, a man of 34, was engaged as a porter. The photograph is published by him and also by Drs. Hansen and Looft. The following facts are condensed from an excellent report of the case by the former of these observers. The leprosy had begun in childhood, and had, at the time the portrait was taken, existed for twenty-five years. Its early stage was a macular eruption, sometimes attended with bullæ, but for many years the skin had been quite sound. His father and his sisters were healthy but his mother was a leper. He had been admitted under Dr. Danielssen's care into the Bergen Hospital at the age of ten, in 1860, and at that time his eruption had been present for three years. At the time of his admission he had many patches on his face which were slightly raised, and there were other confluent patches on his shoulders and other parts. In the centres of some of these patches the skin was becoming white. The muscles of the hands were already somewhat atrophied, and the feet had lost sensation. At the age of 15 all maculæ had disappeared, and there was never afterwards any return of them. Paralysis of the face supervened gradually, and was not preceded by any neuralgic pain. At the date of Prof. Léloir's notes the man was thin, somewhat anæmic, but not of cachetic aspect. It is stated that at first sight it might have been supposed that he was the subject of progressive muscular atrophy with partial facial paralysis.

The atrophy of the small muscles of the hands was so complete that they were little more than "skeletons supplied with tendons." The deformations were absolutely symmetrical. The nails and the skin presented no changes. In the forearms the muscular atrophy was much more advanced in the left than in the right. The ulnar muscles on both sides had entirely disappeared.

The muscles of the upper arm were definitely shrunken, as were also the pectorals. He could, however, use his limbs to a certain extent, and provided he could look at what he was doing, could even employ his fingers. Although there was complete anæsthesia of all the extremities, there was no incoördination of movements, and there was no oscillation of the trunk when the eyes were closed. The muscles of the neck were unaffected. In the face all muscles of expression were partially paralysed. He could not shut his eyes or close his mouth, and there was involuntary overflow of both tears and saliva. The eyeballs showed but little congestion, and the eyelashes and eyebrows were preserved. The man had also a good beard. It is stated that he was in a good state of health, that he ate well and slept well, and that his intelligence was perfect.

It will be seen that we have possibly in this case an instance of the commensal communication of the disease. The symptoms began in very early life, and the boy's mother was a leper. The case is further of great interest as probably affording an instance in proof that leprosy is self-terminable. The skin affections which had been present in the early stage had long ago entirely disappeared, and so far as the narrative informs us there had been no aggression in the nerve phenomena for many years.

Dr. Hansen has informed us that the man is still alive, his malady having now existed for 46 years. The only trace of the long past eruption which Prof. Léloir could detect was a band of slight discoloration on the border of one scapula. This band was slightly anæsthetic.

PLATE M.

DOUBLE FACIAL PARALYSIS WITH ACROTERIC MUTILATION.

We have here the portrait of a woman in whom both facial nerves had been destroyed by leprosy, who was blind, and whose digits had been severely mutilated. The portrait has been copied from a Bergen photograph and has been repeatedly published. One ingenious author has given it as a typical representation of the melancholy which he supposes to be common in the physiognomy of lepers. What it does show is the absolutely expressionless face resulting from double facial palsy. The lower eyelids droop and the patient supports her lower lip with her hands and only thus secures closure of the mouth. It will be seen that most of the digits have been lost, and that short stumps only remain. Yet the patient evidently preserves considerable muscular power in the upper extremities. The eyes are in a condition of xerophthalmia from exposure. The face is quite free from tubercles, the eyebrows are not wholly lost, and there is a very abundant growth of scalp hair.

PLATE N.

NEURITIC LEPROSY WITH DOUBLE FACIAL PARALYSIS.

This portrait is taken from a Bergen photograph and the full particulars of the case are given in Observation XLI. of Léloir's work, page 166. It is designated "*Lepra systématisée nerveuse; Paralysie faciale double.*"

The subject of the case, as of that of Plate L, was a man under care at the Saint George's Hospital at Bergen, where his condition was very carefully studied by Prof. Léloir in September, 1884. The narrative constitutes observation XLI. in Léloir's work, see page 166, and from it we condense the following:—

The patient at the time of the notes was 55 years of age. He had been born on the Sogne Fjord and had been a fisherman. There was no known inheritance. He had suffered from leprosy for twenty-three years, the disease having commenced at the age of 22 as a macular eruption on his face and limbs. Anæsthesia of the limbs was observed almost at the same time as the eruption appeared, and some time later the left side of his face also became defective in sensation. Six or seven years later his hands were deformed "*en griffe*" and the digits were shortened by interstitial absorption of bone. At the age of 35 the facial paralysis was almost complete, and a little later his corneæ became hazy. When Prof. Léloir saw him he was pale, anæmic, and cachetic. He could not shut his eyes and was accustomed to sleep with them open. The eyelashes and eyebrows were quite lost. The corneæ were opaque and dry, he was almost blind, but could see light and even distinguish persons. The mucous membrane of the conjunctiva had become almost cuticular. The cheeks were motionless and the patient could neither laugh nor whistle. The lower lip was constantly drooping, and the saliva escaped. He ate with difficulty, for, although his teeth were perfect, his food constantly accumulated in the cheeks. There was definite defect of sensation in the buccal pouches and in the gums. This was most marked on the left side, on which side the skin of the face was also completely anæsthetic. On the right side of the face sensation was defective, but not wholly lost. The man complained much of a sensation of thirst and of dryness of the mouth.

PLATE O.

PERFORATING ULCERS OF THE SOLE OF FOOT.

In this Plate are shown the late conditions of ulceration of the sole of the foot consequent upon leprosic neuritis. They are very similar but often more extensive than those which occur in the perforating ulcer which not unfrequently attends tabes. Portions of necrosed bone are often picked out of the sores from time to time, and the feet gradually became shortened and clubbed. Precisely similar conditions are not unfrequently seen in association with other forms of impairment of nerve supply. Although very common in leprosy, they are to be considered rather as a sequlæ than as an essential part of the disease. They are frequently present many years after all evidence of aggression on other parts of the body have wholly ceased. The fact that such ulcers with exfoliation of bone rarely occur in the palm of the hand illustrates no doubt the influence of constant pressure in localising the disease in the sole of the foot.

PLATE P.

THE EARLY STAGE OF NODULAR LEPROSY.

We have in this portrait, which is copied from one published in Bergen, an illustration of the earliest stage of nodular leprosy on the face. The forehead is seen to be covered with small, partially-isolated, low papules, whilst there is comparatively little general thickening or alteration of the features.

PLATE Q.

LEPROSY IN THE TUBERCULAR STAGE WITH EARLY TENDENCY TO ULCERATION.

In this Plate we have the portrait of a woman showing a somewhat peculiar form of nodular leprosy. The tubercles occur in isolated patches and show a tendency to early ulceration. The diffuse œdematous thickening of the skin generally, which is seen in Plate S, is not here present. The nose is but little thickened, whilst a deep ulcer has occurred in the left ala. These conditions much resemble those not unfrequently seen in the lupoid forms of syphilis.

PLATE R.

NODULAR LEPROSY IN A BOY.

This portrait shows a most severe form of the nodular type of leprosy. The face is covered with isolated or confluent tubers, some of them partially constricted at the base. There is much less of diffuse thickening of the skin than is usual. On the lower lip and several other parts ulceration has occurred. The limitation of the disease to the face and ears is exactly the same as that noted in several other portraits, and which Prof. Léloir has described as resembling a mask. The hands appear to have suffered severely, the digits being thickened and ulcerated. Some ulcerated patches are also to be observed on the forearms, tips of elbows, and lower part of upper arms, whilst the trunk appears to have almost wholly escaped.

The features just described are those which are usual in the more typical forms of nodular leprosy, and they probably illustrate the influence of local exposure in the production of the lesions. The face and the extremities are the parts which suffer most, and those on which alone conspicuous and large tubers are observed. In this we trace a remarkable feature of resemblance to what is frequently seen in lupus valgaris when the face or the hands are affected. It is on these parts that the greatest amount of swelling is always observed, and the greatest tendency to ulceration. The cause is probably the same in the two maladies, a feeble circulation in the individual and susceptibility to the influence of cold.

This portrait may be compared with those of Plates U and V, of which it may be allowed to represent the earlier stages.

PLATE S.

NODULAR LEPROSY OF SEVERE FORM.

("*Léontiasis lépreux.*")

This portrait is, like several others, copied from a Bergen photograph, and belongs to one of the cases for the particulars of which we are indebted to Prof. Léloir's careful observation. It is the subject of Observation 11, in that author's work, page 80.

The subject of the case was a young man of 21; he believed that his mother, who was still alive, was the subject of leprosy, and one of his sisters had died of it in the Hospital. One of his brothers was still in the Hospital and was seen by Prof. Léloir, who records that the condition of the two was much alike. The disease had commenced at the age of 10, and the first symptom had been flattish nodules on the left knee, which were soon followed by nodules on other parts of the body. He had obtained admission to the Hospital about two years after the commencement of the disease, and the disease had made definite advance since his admission. Prof. Léloir publishes the portrait as a typical example of pure tubercular leprosy with accentuated léontiasis, and he invites his readers to use a lens to inspect it. The lesions, he writes, involve the face only, "which they cover as with a mask." He speaks of "*l'infiltration tuberculeux colossal.*" The condition of the face caused but little discomfort. The hypertrophic masses were not painful although they were still sensitive when pricked. They were in a completely indolent condition, and only a few of them showed a tendency to ulcerate. Thermal sensibility was diminished but not lost. On both upper and lower limbs there were nodules, and a few scattered ones on the trunk. The palms were free. The patient was much troubled with a laryngeal cough and hoarseness. His sexual system appeared to be but very poorly developed, but his general health was tolerably good.

Prof. Léloir records his interest in observing how closely some of the features of the case resembled those of lupus. He speaks of the case as one of tegumentary leprosy, and comments upon the fact that, although the disease was now of long duration, there were none of the ordinary symptoms of "*lèpre systematisée nerveuse.*" He does not, however definitely state that the ulnar nerves were not thickened, or that there was no anæsthesia of the extremities. Sensation to touch is stated to have been lost on the face.

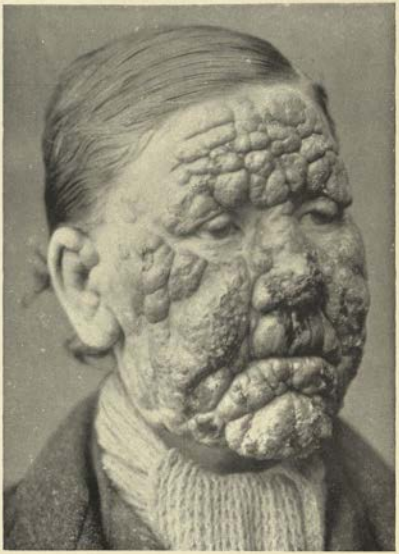

PLATE T.

DEFORMITY AND MUTILATION OF THE HANDS IN A LATE STAGE OF LEPROSY.

This Plate, copied from a Bergen photograph, shows the condition of the hands in a late stage of leprosy. The digits have been contracted by muscular atrophy and mutilated by acroteric ulcerations and interstitial absorption of bone. The wasting of the small muscles is well shown, the palm being cupped and the rounded outline of the ulnar border of the hand and of the base of the thumb quite lost.

The notes of the case have been carefully recorded in Léloir's work, under the date October, 1884. The patient was then in the twentieth year of his leprosy, it had commenced in boyhood at the age of eight. His father had died of leprosy fourteen years ago, but his mother and two brothers were in good health. He had lived in the manner usual to Norwegian peasants. His early symptoms had been neuralgic pains in the limbs followed by bullæ like those of pemphigus on the extremities, which had left white scars. About the same time he had numerous blueish macules on various parts of the body. The mutilations of his hands did not set in until the disease had been present nearly ten years. The conditions were symmetrical, and in each hand the thumb, although flexed, escaped mutilation. Crossing the upper part of the palm of the right hand was a deep ulcerated fissure. All the extremities were anæsthetic. There were some large patches of discoloration on the back, but these were not anæsthetic. The patellar reflexes were somewhat diminished, and the ulnar nerves were thickened. There was no facial paralysis. The patient ate and slept well, but he was thin and pale.

Professor Léloir points out that the deep fissure or "crévasse" in the left hand was to be regarded in the light of a perforating ulcer, it thus ranges rather with the secondary results of nerve disorders than with the aggressive changes of leprosy. The latter, indeed, appeared to have nearly come to an end, the eruption having disappeared. The presence of this ulcer is of interest in reference to the theory of commensal communication of leprosy, since it might easily have become a source of contamination to any articles of food which the hand touched. It might be suggested that the patient himself had derived the disease commensally since his father was a leper, whilst his mother and brothers had escaped. No information is given as to the state of the man's face. In the main the case is clearly one of the maculo-neuritic type. It is with this form chiefly that acroteric mutilations are associated.

PLATE U.

NODULAR OR MIXED LEPROSY IN THE TWENTY-SIXTH YEAR (SELF-TERMINATED).

This portrait, copied from a Bergen photograph, shows the face extensively scarred, the nose sunken, and the corneæ opaque. The sinking in of the nose implies destruction of the septum, and closely resembles what might have been consequent on syphilis. In the absence of history in the present instance that suspicion cannot be wholly excluded, but there is no doubt that in some cases the ulcerations of leprosy do produce conditions exactly such as these shown in this portrait. The eyes have been lost, and the lower lids droop as if from facial paralysis.

The following particulars of the case are taken from Léloir's detailed narrative:—The patient was a man aged 46, and he had been the subject of leprosy for at least 26 years. One of his sisters had died a leper, but his parents had remained healthy. His earliest symptoms occured on the face where he had tubercles which soon ulcerated. About the same period patches appeared on the legs. At the age of 25 he was admitted into the leper home at Bergen. He believed that for about 22 years he had been quite free from skin affections, the tubercles having disappeared, either by ulceration or by interstitial absorption. At the time Prof. Léloir observed the case he was very severely disfigured, and quite blind. He had double facial paralysis, and had lost both his eyelashes and eyebrows. He retained, however, a good head of hair. He had lost the sense of smell, and that of taste was much diminished. Enormous white cicatrices covered his limbs, shoulders and face, resembling exactly those left by large syphilitic gummata. There were some smaller scars on the trunk also.

At the time the above notes were taken the patient was somewhat cachetic and had a very large abdomen with, as M. Léloir believed, some enlargement of both spleen and liver. It was, however, twenty years since the active phenomena of leprosy had come to an end. The man had a good appetite, and was very fond of smoking. Although the notes state that the scars were exceedingly like those of syphilis, there is no information as to enquiries on that head.

Anæsthesia of the extremities with muscular atrophy was extensively present, and there was much deformation of the feet. The patient was liable to attacks of difficulty in breathing during his sleep, and had suffered from laryngitis.

Although we have assumed that the case was one in which the disease had for long practically come to an end, the notes are not quite explicit as to the dates of the several phenomena, they are definite only as regards the skin.

PLATE V.

A CASE OF SELF-TERMINATED LEPROSY WITHOUT RELAPSE DURING TWENTY-EIGHT YEARS.

This portrait is designated in Léloir's work (see Observation LIV.), as "*Lepra tuberculeuse, devenue trophoneurotique; Lepra mixte, variété, tuberculeuse systématisée nerveuse.*" In this case the destruction of the nose, upper lip, &c., remarkably resemble those sometimes due to syphilis, or those of lupus vulgaris, and the sex of the patient may perhaps leave the diagnosis of the former open to some suspicion. There is nothing, however, to make the diagnosis of uncomplicated leprosy improbable. The case is in the receding stage, or that of partial cure. There has been extensive destruction of skin, &c., but sound scars have resulted, and all tumefaction has disappeared. The eyes and the eyebrows have been destroyed.

The subject of this Plate was a Norwegian peasant. He was 54 years of age in 1884, when Prof. Léloir took notes of his condition. His father had died of leprosy, his mother had remained free but was now dead of other disease. She had borne to her leprous husband seven children, of whom no fewer than five had become lepers, and three out of these five were already dead. The disease in him had commenced at the age of 13 years, the earliest symptom being numbness of the extremities and face. At the age of 15 he had tubercles on the face and extremities, and about the same time began to suffer from the symptoms of double facial paralysis. He subsequently had corneal lesions and became blind. The disappearance of all tubercles had been complete for twenty-eight years. Before their disappearance, however, the nose and adjacent parts had been extensively destroyed. Prof. Léloir describes his appearance as that of a walking corpse, and states that the lower part of his extremites were reduced to skin and bone. He is definite, however, that no traces of active leprosy, tubercles or macules could be found. The skin of the face was covered with cicatrices, many of which were thirty years old. The eye-lashes, eye-brows and beard had entirely disappeared, but an abundant head of hair remained and was in strong contrast with the withered face. The face and the extremities had lost sensation. The skin everywhere had an earthy tint. The ulnar nerves still remained somewhat thickened. The man had a good appetite and bore his affliction with patient cheerfulness, "not for one moment desiring death."

Monsieur Léloir adds, not without a touch of sarcasm, "*Voilà ce que certain medécins Norvegiens considère comme un lèpre guèrie.*" Yet it is only to the expression "cured" that any exception can be taken. The case was one of self-terminated leprosy, and the patient had been for twenty-eight years free from aggressive symptoms. It is true he was blind, paralysed and mutilated, and using the word in its social sense the cure was lamentably imperfect. In a pathological sense, however, the cure, or recovery, was complete, and during a period of twenty-eight years there had been no tendency to relapse. The early age at which the disease commenced may be allowed to exclude the suspicion of syphilis as a complication which otherwise the appearances might suggest.

PLATE W.

FUSIFORM ENLARGEMENT OF NERVES IN LEPROSY.

This Plate, taken from Drs. Danielssen and Boeck's Atlas, shows a dissection of the front aspect of the arm, forearm, and hand. The median and ulnar nerves are displayed in the greater part of their length and fusiform enlargements are seen. These enlargements in the case of the median are greatest in front of the elbow and wrist joints, but in the ulnar the trunk above the elbow is much larger than at any other part. Those accustomed to examine this nerve for the purpose of diagnosis will be familiar with the fact that the nerve must be traced in the lower part of the upper arm, and not only beneath the condyle. It is often not appreciably enlarged in the latter position when a little higher up it is found as thick as a cedar pencil or even as a little finger. This clinical fact receives important exemplification in the Plate.

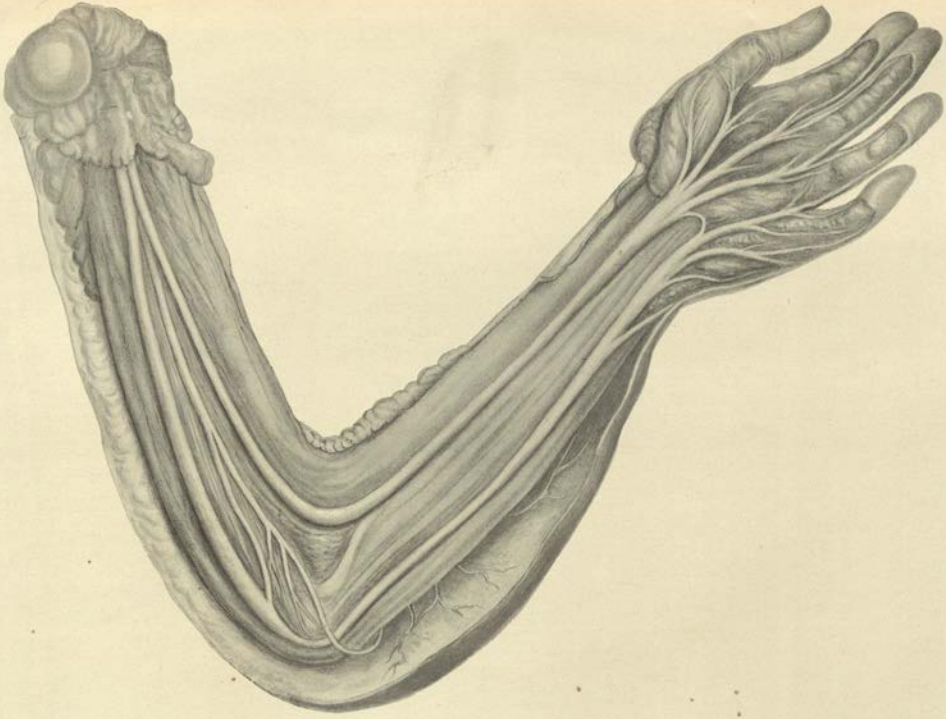

PLATE X.

LEPROSIC NEURITIS (POSTERIOR TIBIAL).

Like the preceding and the following ones, this Plate is taken from Danielssen and Boeck's Atlas. It shows enlargement of the posterior tibial nerve in the greater part of its length. It will be observed that the increase in size is greatest in the lower part of the trunk, and greatest of all in its plantar divisions. It is presumably from the same dissection as plate Y.

PLATE Y.

LEPROSIC NEURITIS (ANTERIOR TIBIAL AND SHORT SAPHENOUS).

This Plate is, like the two preceding ones, copied from one given with colour in the fine Atlas on Leprosy, published more than half a century ago by Drs. Danielssen and Boeck. It shows the enlargement of the nerve trunks which is such a common condition in Leprosy.

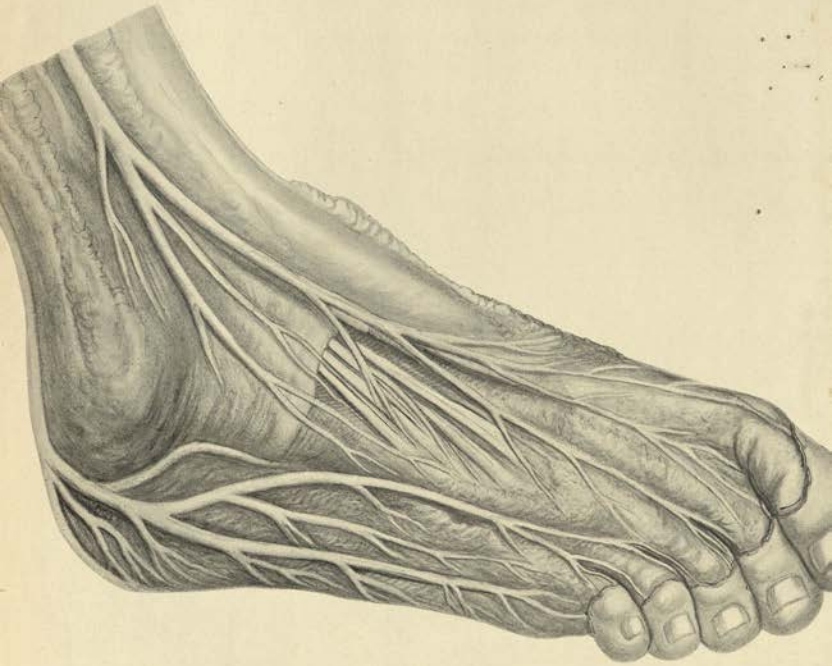

PLATE Z.

DIFFUSE LEPROSIC DERMATITIS WITH NODULATION.

(Two portraits of the same patient.)

The two portraits here placed side by side represent the same patient with an interval of nearly seven years. The first was taken three years before any symptoms of leprosy had shown themselves, and the second three or four years after their commencement. They are copied from the excellent Atlas of Illustrations of Leprosy, published in Berlin by Hirschwald, from the studio and pen of Dr. A. Grünfeld, of Odessa. This work, which has a preface by Dr. Lassar, of Berlin, contains 100 portraits of lepers, collected in the regions about the mouths of the River Don. The work gives very brief particulars of the individual cases, but usually states the patient's occupation, and it may be noted as a fact probably not without its meaning, that of the men a very large proportion were fishermen. The whole district is largely engaged in catching and curing fish.

The patient was a young woman, born in 1866, and who was in good health in 1889 when the first portrait was taken. She showed her earliest symptoms of leprosy in 1892, and the second portrait was taken in 1896. She was the mother of one child, which remained at the date of the notes in good health.

The second portrait offers a good illustration of the diffuse dermatitis which often attends leprosy. It will be seen that the whole face is tumid, and the ears especially thickened. The patient's likeness to her former self is quite lost. The digits, hands and forearms are also swollen, and on many parts the tumidity amounts almost to the production of nodules. The form of disease may be termed maculo-nodular, and it is very possible that at a later stage the nodular character became much increased.

Our object in reproducing these portraits is not solely to show, by contrast with the condition of health, how great may be the amount of hypertrophic swelling of the skin, but also to claim by a demonstration of its cruel ravages the sympathy of our readers with those who suffer from leprosy, and, through that sympathy, their zealous co-operation in the endeavour to discover its cause.

AN

ATLAS OF ILLUSTRATIONS

OF

CLINICAL MEDICINE, SURGERY AND PATHOLOGY

COMPILED FOR

THE NEW SYDENHAM SOCIETY

(A CONTINUATION OF THE "ATLAS OF PATHOLOGY")

FASCICULUS XIX. (Double Fasciculus)

Being X. & XI. of THE CLINICAL ATLAS.

Illustrations of Herpetiform Morphœa

PLATES CXXVI. to CXXXIV. (*Coloured*), and A to J (*without Colour*);

Radiographs Illustrating Colles' Fracture

PLATES K to S (*without Colour*).

LONDON:

THE NEW SYDENHAM SOCIETY

Agent—H. K. LEWIS, 136, GOWER STREET, W.C.

1904

ILLUSTRATIONS OF HERPETIFORM MORPHŒA.

(*Coloured*).

PLATE CXXVI.—Morphœa on arm and face of young man.
" CXXVII.—Morphœa on back of young girl.
" CXXVIII.—Morphœa patches under the breast.
" CXXIX.—Morphœa in bilateral zones (two figures).
" CXXX.—Morphœa in bilateral zones (two figures)
" CXXXI.—Morphœa in group on clavicular region.
" CXXXII.—Morphœa in temporo-malar region.
" CXXXIII.—Morphœa in patches on face and neck.
" CXXXIV.—Morphœa on face.

(*Without Colour*).

PLATE A.—Morphœa involving almost the entire surface.
" B.—Morphœa affecting the foot.
" B *bis*.—Morphœa affecting the short saphena nerve.
" C.—Morphœa followed by hemiatrophy of face.
" C *bis*.—Hemiatrophy of face (Nicholls).
" D.—Hemiatrophy of face in slight form (eyelid).
" E.—Hemiatrophy of face in a woman (Bruns' case).
" F.—Hemiatrophy in a Girl (Mr. Stanley Boyd's case).
" F *bis*.—Hemiatrophy of face.
" G.—Hemiatrophy of face and tongue.
" G *bis*.—Atrophy of one half of tongue.
" H.—Hemiatrophy of face (Dr. Byrom Bramwell's case).
" I.—Hemiatrophy of lower half of face.
" J.—Herpetiform Morphœa affecting one lower extremity (Mr. Sympson's case).

ILLUSTRATIONS OF MORPHŒA

(SCLERODERMIA.)

Amongst the many problems of absorbing interest which the study of disease offers for our investigation, there are few which can claim precedence over those with which we have to deal in the present Fasciculus. Next in order to the phenomena of Herpes itself those of Sclerodermic affections of the skin afford us our best opportunities for the appreciation—not perhaps without wonder verging on amazement—of the possible influence of the nervous system upon the nutrition of parts supplied and of the laws and limits under which that influence is manifested.

Nor is our subject without its claims upon the practitioner as well as the student of pathogenesis. Although in themselves of infrequent occurrence, these maladies are types of what is common ; they occur scattered over the whole community, and are as likely to present themselves to the village surgeon as to his hospital *confrère*. It is of importance, therefore, as well for the patient's advantage as the practitioner's repute, that all should be prepared for their recognition ; and it is obvious that such preparation may be the means of securing intelligent observation of new facts, and thus of advancing our knowledge. The illustrations now given, with their explanatory comments, will, it may be hoped, do something towards securing the object in view.

General Statements.

In connection with the disease, which was first known as "Addison's Keloid" or "Morphœa," and subsequently as "Sclerodermia," a large amount of very valuable information has recently been accumulated. Although the work has chiefly been accomplished by the zeal of dermatological observers, there can be no doubt that the affections which have been placed together under these names belong really to the neurologist. They are all due to disorders of nervous function, which display their results conspicuously on the skin, but which are by no means confined to it. It is even possible that in some of them the skin itself is not obviously affected, and in none do changes in it constitute the starting-point of the disease. In none, although local influences may take a share in the evolution of the phenomena, do they originate them. The advance of clinical knowledge has made it evident that under the names originally employed several different maladies, as denoted by groups of symptoms and by the course which they run, have been somewhat confused. A more or less close relationship with what is known as "Raynaud's malady" appears to characterise one form, whilst it is wholly absent in another. Whether or not these different forms have a mutual bond of connexion which entitles them to rank as one family is as yet open to debate, but there can be no doubt that their differences are sufficient to make it desirable that they should be recognised in our nomenclature. As regards the names which we employ it has been unavoidable during the rapid advance of our knowledge and the distance from each other at which some of their best observers have worked, that some differences of usage should

have occurred.[1] As it is of primary importance to a clear comprehension of the facts, and to further progress in their classification, that the terms which we employ should be used with some approach to uniformity, a few sentences may perhaps not be wasted in the endeavour to give them precision. We have in reference to our topic the following terms in more or less general use :—

Addison's keloid.
Morphœa (with various adjectives).
Sclerema, or scleriasis cutis.
Sclerodermia.
"Hide-bound" or "leather-like."
Sclerodactylia or "wooden-fingers."
Acro-asphyxia.
Acro-sphacelus.
Hemiatrophy of face.
Ivory patch.
Lardaceous patch.

Before offering definitions of these terms it may be convenient to enumerate the clinical conditions to which we have to allot our names.

"Sclerema infantum" and Sclerema of Young Children.

We have first a very rare and very peculiar affection occurring in new-born children, and usually resulting in death within ten days. The integument and subcutaneous tissues become hard as if frozen ; they may be congested or deathly pale. The temperature is below normal, and falls daily. The infant lies as if frozen. The skin is slightly œdematous. The affection usually begins in the lower extremities and advances upwards. Recovery is possible, and if it occurs, the skin is restored to a quite normal state. *Post-mortem* examination shows only slight œdema of skin and a stearine condition of subcutaneous fat.[2]

To this affection the term "Sclerema infantum" has been given. Next to it we have, occurring in young children at various ages, a somewhat similar condition, but unattended by loss of temperature, and usually resulting after a duration of some months in restoration to health. This has been known as "the Diffuse Sclerema of young children." Very few cases are on record in sufficient detail to permit of critical examination. It is to be observed that both these two affections are disorders of the subcutaneous fat rather than of the skin itself. In both the changes are diffuse and no patches are present.

The "Hide-bound" Sclerema of Children."

Distinct from these, unless indeed, it be a late stage of the latter, we have the condition known as "the hide-bound skin," which occurs in children, and is attended by emaciation and a general contraction with induration of the skin. The patient is as if cased in leather. The disease, if well marked, is a very serious one and usually ends fatally (*e.g.*, see page 112).

"Diffuse Morphœa," or "Sclerodermia."

Next in order should perhaps be mentioned conditions occurring chiefly in adults, and almost exclusively in women, in which the extremities, the face and upper part of the bust are involved in a hide-bound condition. The lesions are symmetrical and somewhat ill-defined, there being no patches. The digits suffer most, and Raynaud's phenomena are always conspicuous. Stigmata appear on the face, and the skin of the face bcomes more or less stiffened.

"Herpetiform Morphœa," ("Sclerodermia circumscriptum.")

Lastly, we have the most important group of all : one in which well margined patches, or groups of spots, occur on the face, limbs or trunk, between which the skin remains supple and

[1] So recently as 1869 Dr. Arnold, of Baltimore, described three cases of sclerodermia, and said that he believed that they were the first which had been observed in America. He refers to sclerodermia as distinct from morphœa. Since then numerous cases have been recorded by American observers, with very valuable comments. There is good reason to believe that the disease is as common in the States as it is in England.

[2] For the best summary of information on this most interesting malady see vol. ii. of Dr. Ballantyne's excellent work on "Ante-natal Diseases."

healthy. These cases may occur at any age excepting infancy, and are almost equally common in the two sexes. The patches may be single or multiple, and either one-sided or bilateral. However numerous and extensive, they are but very seldom arranged in accurate bilateral symmetry. The muscles are almost always affected and not infrequently the bones also.

Having thus enumerated the conditions with which we have to deal, we are now in a position to attempt definitions of our terms.

Definition of Terms employed.

The two words "sclerema" and "sclerodermia" are often used as if they were synonymous. If they were so it would be desirable to disuse one of them, but in fact the latter denotes hardness *of the skin* and the former only hardness in a general sense. Both are pathological rather than clinical designations, that is, they denote one particular feature in the disease and not its totality. It may be suggested, therefore, that it would be convenient to restrict them to their proper meanings and not allow either of them to supplant the much older clinical name of "Morphœa." Under this latter designation all cases may be suitably included which can be proved to be in any real relationship with the "Keloid of Addison"—the circumscribed "ivory" or "lardaceous patch." This is the disease originally described as "Morphœa," and the name has the advantage of having no special pathological meaning, and thus being applicable to the whole group of phenomena and the whole course of the malady, and not to one feature or one stage only. It is surely unsuitable to continue to apply the name "Sclerodermia" to a disease in which the muscles are almost always, and often very severely affected, and in which in some instances the skin may almost wholly escape. The expressions "ivory patch" and "lardaceous patch" may be easily understood to be almost synonymous, and to be descriptive of the well margined white areas, or groups of spots, usually somewhat thickened, and often smooth and polished, which suggest a comparison to inlaid ivory or the infiltration of lard. Both are applicable to a certain stage of the malady.

Taking, then, the word Morphœa as the best substantive name for the disease in its totality, we have to ask as to the adjectives which may suitably characterise its different forms.

For the present we may put aside the two forms of sclerema which occur to infants, since it is by no means proved that they have any real relationship to those met with at later periods of life. It is, however, not to be assumed as established that the notable differences which they display may not be explicable by the difference in the age of the patient and the stage of development of the tissues attacked. That is a question for future investigation.

Of the cases which occur in those of more advanced years, we have two well characterised forms, that, namely in which the changes occur in patches, and that in which large tracts are affected without any very definite limitations. The terms "circumscribed" and "diffuse" have been used to distinguish these two. Inasmuch, however, as the "circumscribed" cases display also other and yet more distinctive features, we may reasonably ask whether it is the best that can be devised. It is now generally admitted that in many instances these patches are grouped very evidently by the distribution of cutaneous nerves. Sometimes a one-sided belt exactly like one of herpes zoster curves round the chest or abdomen from the spine to the middle line in front. In others, the fifth nerve or one of its divisions may regulate the distribution, and in yet others the short saphena in the foot or the temporo-malar on the temple may be the one involved. Although very often bilateral, the patches in these cases are scarcely ever accurately symmetrical and often exhibit most definite deviations from such symmetry. These features imply such definite similarity to herpes zoster that in spite of the great difference in the characters of the local lesion, the length of its duration, and its frequent multiplicity, it would seem well to recognise

this most important fact and to use the term "herpetiform" rather than "circumscriptum." Nor are the features just mentioned the whole of those in which herpetiform morphœa in its essential nature appears to claim family relationship with herpes zoster.

Parallelism with Herpes zoster.

Both are affections from which the earliest years of infancy are practically exempt.[1] Both occur to children and to adults of all ages. Both observe stages; being evolved suddenly and completely, and tending ultimately to spontaneous decline. Neither of them, as a rule, occur twice to the same patient. In neither of them do the lesions ever become actively or permanently serpiginous. In both the muscular as well as the sensory nerve branches may be affected and paralysis may result. Both occur usually without obvious cause and to persons in good health.

The conspicuous features in which herpetiform morphœa differs from herpes zoster are that its patches are often bilateral and multiple; that they occupy months in evolution and years in duration; that they are almost always attended by implication of muscles, and that the local lesion is a cell-infiltration with ischæmia of vessels and not the formation of vesicles. None of these are, however, essential distinctions, and it remains a well-established probability that both result from pathological processes closely allied to peripheral neuritis.

Use of the term "Diffuse."

We may here remark that it is desirable to be very precise in the meaning which we attach to the adjective "diffuse." It is sometimes employed as if it were equivalent with "extensive" or "widely spread," a meaning which, although etymologically correct and in accord with literary usage, is very misleading in clinical designations. In Ogilvie's dictionary we have its clinical meaning well defined: "In pathology, applied to diseases which spread widely and have *no distinctive defined limits*, as opposed to those which are circumscribed." Thus, for example, a psoriasis eruption may be so abundant as to cover almost the whole surface, but if some healthy portions of skin are left and these abruptly margined, the term "diffuse" ought not to be applied, for the result has been produced by the coalescence of patches which were at first well circumscribed. It is essential to clearness in reference to the subject in hand that this term be applied only to conditions which do not, at any stage nor in any part, show abrupt lines of limitation, and as being opposed to the terms "circumscribed" or "herpetiform," without any reference to the extent of the surface involved.

No objection can be taken to the use of the term "diffuse" as applicable to those forms of morphœa in which there are no really definite patches or streaks, and in which the hide-bound state of skin shows no abrupt limitations. In these cases, however, since the digits almost invariably suffer and the condition of "wooden fingers" or sclerodactylia is produced, the designation of "acroteric morphœa" might perhaps be more clinically useful.

CONTENTS OF THE PRESENT FASCICULUS.

In the present Fasciculus we are concerned only with the herpetiform group of cases. Some portraits of acroteric or diffuse morphœa are in preparation, and will appear shortly, but none of those now given illustrate that form. One of our portraits (Plate CXXXI.) shows the earliest stage of the ivory patch, the lardaceous spots being still separate one from another, and looking much like a group of white herpes. Several others show the ivory patches in their more characteristic form, but few in number. Others show these patches in great multiplicity, and not only bilateral but even arranged in zones, whilst in

[1] NOTE ON THE EXEMPTION OF INFANTS FROM MORPHŒA. Infants do not ever suffer from the "lardaceous-patch morphœa." It may be that in them the development of the nervous system in not sufficiently advanced to permit of the production of these phenomena, and that in them the causes which would in adults produce such results are attended by other changes. The period of liability to herpes and to morphœa as regards age is almost exactly the same. Both begin to occur about the age of five, and are tolerably frequent and often severe between that age and the period of puberty. Both diminish somewhat in frequency as age advances, but either of them may occur even in the old, but when they do so are usually attended by certain features of peculiarity.

one they were so extensive as to cover almost the entire surface. Thus we are led on *seriatim* from the single patch to such extensive generalisation as to suggest the term "diffuse." Still, we have to insist that that term must be reserved for another group, between which and the cases now in hand definite distinctions can be drawn. A final series of our portraits illustrates not so much morphœa itself as the secondary or atrophic results which are observed years after its processes have ceased.

Some Account of Portraits, &c., from other Sources.

It may perhaps be for the reader's convenience if we here briefly refer to the principal illustrations of Morphœa which have been published in other Atlases or are contained in public museums.

Guy's Hospital Museum is, as might be expected, rich in illustrations—both wax models and drawings—of a disease, for the elucidation of which its medical staff—Addison, Gull, Hilton-Fagge, Pye-Smith—and others have done so much.

The Clinical Museum of the London Polyclinic contains, with some others, the original portraits from which most of our plates have been copied. It also contains the portrait published many years ago by Neumann, of Vienna, and a yet older one given by Cazenavè under the designation of "cancroide," and showing a large patch on a woman's breast.

Very few illustrations of Morphœa are contained in the older atlases of skin diseases. Erasmus Wilson, who wrote an excellent chapter on it, gave no portrait. Nor was there any in *Hebra's Atlas*; nor have we observed an original one in any of the atlases published in America.

In *Kaposi's Hand Atlas* we have the following.

Tafel 316, under the denomination of Sclerodermia femoris, exhibits both thighs and both knees of a patient in whom large patches, abruptly margined, are distributed in the main with bilateral symmetry. On careful inspection, however, some definite deviations from symmetry may be detected. Thus there is a patch below one knee which has no representative on the other. The case affords a close parallel to that shown in our plate CXXX. There is no statement that patches were not present on other parts.

Tafel 317 shows a state of patches the same in character as those in 316, but as only one upper arm and side of chest are displayed, we have no clue to the bilateral distribution. The patches are abruptly defined and have congested borders. Some of the size of shillings are almost round, but others are much larger and of irregular form. A remarkable one of crescentic shape curves under the left nipple.

These two are the only portraits under the head Sclerodermia which this invaluable atlas contains.

The Museum of St. Louis' Hospital, Paris, is rich in models of excellent execution. These are described in the catalogue under the designation *Sclérodemie en plaques, Morphée*. These models show the patches on various parts of the limbs and trunk. Respecting but few of them are any particulars given in the text. One (No. 1,142) is of interest because it exhibits lesions of the tongue. The thigh was affected, and the terms used are "Morphée blanche plane; plaques en voie de guerison" (see No. 841). Another, in which the arm was the part affected, is described as "Sclérodermie en plaques systématiques; Morphée linéaires (No. 1,055).

It will be seen that our French *confrères* use the term *Sclérodermie en plaques* as synonymous with Morphée. "*En plaques*" is much better than "circumscribed," (the adjective in favour with some English authors), but there appears no good reason for not allowing the substantative "Morphœa" to stand without the suggested equivalent "Sclérodermie." It is the older and, in many respects, the better name.

This celebrated museum does not appear to possess any representation of the hemiatrophy of the face which is an occasional sequence of fifth nerve morphœa.

Radcliffe Crocker's Atlas, in Plate XLIX., gives two portraits of "Scleroderma circumscriptum (Morphœa)." They are from the

same patient with a two years' interval, and show the disease on the forehead and neck of a young girl. In another plate (two figures) the disease is shown in one on the inner side of the thigh, and in the other on the outer side of one foot, in the distribution of the short saphena nerve. In the excellent letterpress which accompanies these plates, repeated reference is made to the zoster-like distribution which often occurs in morphœa.

Jacobi's Atlas (tab. L., figs. 92 and 93) has two delineations of the disease, on the forehead of one patient and on the upper extremity of another. Both show the zosteriform or patch type. Fig. 92 is of no great clinical value and might be supposed to represent only a deep fissure in the middle of the forehead. Fig. 93, however, shows with extreme accuracy the distribution of a long irregular patch, or group of patches, extending from above the elbow to the back of the hand. The artist has succeeded in exhibiting the shallow depressions of surface which result from the sclerosis, and has also given with admirable truth the bluish-white tint of the margins of patches. Such portraits as this will illustrate the distribution of the changes by nerves and justify the term which we have employed. A portrait published many years ago by Neumann represents a very similar state and arrangement.

The Stages of Morphœa.

In some cases a condition of tumefaction with œdema, which may be mistaken for erysipelas, is the first stage of Herpetiform Morphœa, but in the majority the initial stages are wholly overlooked. There is neither pain nor irritation, and the patches are not recognised until they become conspicuous to the eye. If there are many patches it almost always happens that it devolves upon the surgeon to discover some which the patient had not noticed. This fact is recorded in several of the case-narratives which we have given. Probably the earliest stage of the ivory patch is always a group of separate spots, such as is shown in Plate CXXXI.; but this stage is but rarely seen. In the course of a few months the spots become merged in a patch, which is thickest in the middle, of ivory whiteness, and has fairly abrupt boundaries. The most characteristic conditions of the ivory or lardaceous patch are always produced when the patches are either single or few in number, and not of very large size. If a large extent of surface is involved the next stage, that of atrophy, soon follows. In it there is removal of all fat and the skin becomes stiffened, contracted, and both in colour and texture like brown leather. In this stage ulcerations may occur, especially if the site of the patch is on the lower extremities. Several of our plates show these ulcers, which are probably due to slight injuries sustained by skin very inadequately supplied with blood. At the end of two or three years reparation sets in, the ulcers may heal, and the skin becomes less indurated, and may gradually resume a supple condition. The reproduction of fat is rarely complete, and even after almost perfect recovery as regards the skin itself there remains a subcutaneous hollow or trough due to the absence of fat. During these stages the muscles supplied by nerves in association with those of the affected portions of skin will always be found wasted and weak, but maintaining their normal electric reactions. As recovery progresses the muscles usually plump out again, but not always. An example of possibly permanent atrophy is shown in Plate G *bis*, in which one half of the tongue is seen to be shrivelled. Throughout there is little or no defect in sensation, but the hairs fall out, and neither sudoriparous nor sebaceous glands show normal activity.

The above remarks apply to all cases of herpetiform morphœa, whether the patches be few or many. They require, however, considerable modification in reference to those of the acroteric type. In the latter the first stage is usually sudden and attended by conditions which compel the patient's attention. There is definite swelling, with œdema of the parts about to be involved. This is usually greatest on the bust and neck, but involves also the upper extremities and the face. It is a passing condition, and a stiff leather-like condition soon follows it. A tendency

to sclerodactylia is promptly manifested and continues to steadily increase. Now occur also in a modified form the phenomena which are known as Raynaud's, that is, the state of the digits varies from time to time; they are easily influenced by exposure to cold and sores may form at their tips. Sometimes even gangrene of considerable portions may occur. Although there is great susceptibility to external influences there is rarely any approach to the blue stage of asphyxia. Under all conditions as to warmth and cold the fingers remain mottled and pale or even white. Thus it becomes clear that the obstruction to the circulation is persistent, and one in which the vaso-motor system takes probably a far less share than it does in the more characteristic forms of Raynaud's malady. Almost invariably in these stages the skin of the face as a whole becomes stiff, and stigmata are developed on the cheeks.

The evidence as regards spontaneous termination and restoration is much less definite in these cases than it is in those of herpetiform morphœa. There are, however, a number of facts which tend to show that as years advance a certain amount of improvement is usually observed. The patients are almost invariably women, and some relief is often obtained when the change of life is passed.[1]

A certain amount of contraction of the fingers is often witnessed, due probably to implication of muscles, and a common deformity is displacement towards the palm of the last phalanx of the little finger. The facts at our disposal do not enable us to assign any precise duration to the several stages of this form.[2]

[1] It is unfortunate that Raynaud included in his account of "Symmetrical gangrene of the extremities," cases which were probably examples of acroteric morphœa.

[2] An important case as illustrative of the changes in different stages of the malady has been recorded by Dr. Corlett, of Cleveland, Ohio. In it conditions which were diagnosed as morphœa, *i.e.*, ivory patches in connection with nerve distribution, had in the course of a year merged themselves into those of "diffuse sclerodermia." Dr. Corlett points out that American specialists make a distinction between these, and says that his case supports the views of European authorities that they may be stages one of the other, what is named sclerosis being the atrophic and contraction stage of that which at its onset was attended by swelling and assumed the conditions of the ivory patch infiltration. It may be that the œdema which precedes certain cases of diffuse morphœa is the analogue of the ivory patch.

Morbid Anatomy and Histology.

As regards the pathological anatomy of the morphœa patch, we have some interesting observations, but none, it must be confessed, which give any help to the clinical investigator. A recent English text-book does not even mention morphœa, and gives only a few sentences to what its author calls "the diffuse variety of the peculiar hard and shiny condition of the skin known as sclerodermia." Of this he says that the hardness is due to hypertrophy of the white fibrous tissue. "The collagen of the pars reticularis is thickened and new fibres have developed and formed a dense compact mass, from which the lymph-spaces have to a great extent, if not entirely, disappeared."[3] The blood-vessels, hair follicles and coil glands are also diminished or obliterated by the growth and pressure of the fibrous mass. It is left doubtful whether these statements result from the examination of a recent ivory patch, and also whether they are based on original research or the statements of others. Unna gives a much more circumstantial account. He describes, also, the case from which his specimen was taken, and thus gives us assurance that he was really dealing with herpetiform morphœa. He describes hypertrophy of the collagenous bundles as the principal change, and attributes most of the others to the effects of pressure by them. By this pressure the lymph spaces are narrowed almost beyond recognition, and the blood vessels to such an extent that the "capillaries have often completely disappeared." The coil glands and the hair follicles are likewise narrowed and stretched by pressure, and important changes result in the papillary layer.

Winkler, whose account had preceded that of Unna, described similar conditions, but was inclined to believe that they were secondary to an obliterative arteritis. He found changes which led him to associate the different forms of morphœa with each other on anatomical as well as pathological grounds. In this conclusion he was probably correct, although we must agree with Unna in rejecting his hypo-

[3] Unna, Histopathology, &c., p. 1106.

thesis of a primary arteritis. Unna describes as different diseases "card-like sclerodermia," morphœa and "sclerodermia diffusa," but it is tolerably clear that under the latter name he was still dealing with herpetiform morphœa, for he expressly states that in addition to the face, neck, arms and breast, a part of one thigh was affected. Sections were cut on four different occasions, and very carefully examined, but we are not told whether they are taken from the patch on the thigh or elsewhere, nor whether the digits were involved.

We may then take it as established that in all forms of morphœa an increase in collagenous substance is a chief feature, and that with it goes great reduction of blood supply consequent on pressure. These facts are much what might have been inferred from the peculiar whiteness and hardness of the ivory patch. It is to be noted that the observations we have quoted refer most probably to the early stages of the disease—the ivory patch which characterises cases in which only limited areas are involved—and not to the more diffused leather-like state observed in those in which the disease is more widely distributed. Next in importance to this increase of collagen, probably only temporary, is the entire disappearance of fat which is so often permanent.

It is perhaps not needless to remark that future histological observers should be careful to give particulars of the cases from which their specimens were obtained and of the stage to which the disease had advanced. As a negative fact it is to be recorded that no one has recognised any morbid changes in the peripheral nerve structures.

Possibly the sole published account of a *post-mortem* examination in a case of morphœa ("hemiatrophy of face") is that given by Mendel in the *Berliner klin. Wochenschrift* for May 7, 1888. Mendel (as quoted by Montgomery) found "a proliferative neuritis of the branches of the fifth nerve, especially of the second division corresponding to the area of the greatest intensity of facial atrophy. The roots and nuclei of origin of the fifth nerve were all normal, with the exception of the substantia ferruginea and the descending roots on the affected side, which were atrophied."

Recovery and Reparation.

It is of much practical importance to insist that all degrees of herpetiform morphœa are not only self-terminable, but self-recoverable. The integrity of the integument concerned is seldom if ever irreparably damaged. The lower limb has probably in more than a few instances been amputated, on account of its appearing to be hopelessly crippled by the contractions of morphœa. Yet it is an unquestionable fact that if time be allowed these contractions will relax, the hide-bound skin will again become supple, and the muscles resume their vigour. Reparation may occur to an extent which no one who had not seen such cases could have believed possible. Yet it may be noted that the facts that sensation is often but little impaired, that the paralysis of muscles is seldom quite complete, and that the electric reactions are to a large extent retained, might have prepared us for this result. The absolute disappearance of all fat elements appears to be one of the most definite features in the morphœa process, and it is probably but seldom that they are wholly restored. The skin, however, after having long been in a dried leather-like condition, may again become soft and supple. In this final state it may closely resemble that of the senile state in which, all subcutaneous fat being absent, the tendons become visible through a thin and semi-transparent integument.

These possibilities of recovery are not only great but they may be protracted over very long periods. Nothing is more remarkable than the way in which a portion of skin which had been shrunken and tight for several years may eventually relax, increase in thickness, and even approach a healthy condition. As already observed, the lower extremity has been amputated repeatedly on account of disabling contraction from which recovery seemed hopeless. The surgeon should, however, exercise the utmost caution in advising this measure, for however long the conditions may have been in existence, improvement is still possible. Although well aware of this, the writer once himself ventured to advise amputation. This was in the case of a boy who had been some

years under observation. The knee was contracted and so tight that a large ulceration had formed, the healing of which seemed hopeless. There was a second large ulcer on the ankle. The disease had then been present three years. Four years later the condition of the limb was so much improved that the boy could use it in walking and the ulcers were healed. It appears to be an invariable rule that the nutrition of the parts after this malady continues slowly to improve through the whole of the patient's subsequent life. Thus the deformity even of hemiatrophy of the face continues to become less and less the longer the patient lives. This remark does not apply, however, to the bones when their growth has been arrested.[1]

No Relapses or Second Attacks.

Neither relapses nor second attacks as a rule occur.

It is well known that herpes zoster always disappears after a time and shows no tendency to relapse. Its sores invariably heal soundly and manifest not the least aptitude for ser-

[1] In substantiation of what has been said above, the following notes of the case referred to may be of interest :—

"Note on the condition of Mr. F. G. M., in March, 1896, whose case has been described in *Archives of Surgery*, ii., p. 227, and iii., p. 46.

"*Patches on Abdomen.*—These two patches have now lost the white lardaceous appearance referred to in *Archives*, ii., 227, and are becoming pigmented. Their surface is now mottled, white and pigmented streaks alternating with one another. The two patches are about half an inch apart, being connected by some smaller white spots. The skin over these patches is now quite elastic, and can be readily pinched up.

"*Condition of Legs.*—The right leg has become more flexible at the knee, which can be bent up to a right angle, movement being especially free after cycling exercise. There is fairly free movement at the right ankle-joint.

"*Measurements.*—Right knee, 11¼ in. ; left knee, 12¾ in. ; right calf, 8¾ in. ; left calf, 10¼ in. ; right leg (above ankle), 5¼ in. ; left leg (above ankle), 6½ in. (Both legs had been affected, the right more severely than the left.)

"These measurements show that the circumference of the right calf has increased by ¾ in. since June 9, 1891 (*Archives*, iii., 46). Although the left leg is so much larger than the right it (*i.e.*, the left) is much smaller than it used to be before the attack, especially about the calf. The right leg is about ½ in. shorter than the left, but with a thick boot he walks with only a slight limp.

"*Perspiration.*—While the disease was in progress there was no perspiration over the affected parts. But since recovery commenced, perspiration over these parts has become excessive and streams down his legs, especially on exertion.

"*Growth of Hair.*—When the disease was at its height both legs were bare of all hair. Now, however, there is a luxuriant growth of hair over them both, that on the right being the longest.

"*General Condition.*—In other respects Mr. M.'s present condition corresponds to the published description, excepting that everywhere the skin is getting more supple and elastic. His general health is excellent, and he rejoices exceedingly that he did not consent to amputation of the right leg, as was once recommended."

The two following examples of recovery and reparation from differing forms of morphœa appear to be of sufficient interest to justify their insertion here :—

Hide-bound Condition of Skin Affecting the Four Limbs Symmetrically—No Paroxysms of Raynaud's Phenomena — Recovery — Description of the Patient's State Twenty Years later.

The following are my notes :—

"In the person of Mr. T—, a man, aged 42, who was brought to me in January, 1892, by Dr. Wheeler Brown, for another ailment, I had an opportunity of studying a case in which scleriasis of the skin had undergone very remarkable reparative changes. It was twenty-one years since the beginning of the malady. The patient had been in succession an in-patient at Guy's Hospital, and subsequently under the care of the late Mr. Startin, Sir Erasmus Wilson, and the late Dr. Tilbury Fox, all of whom had taken great interest in his case. It had been called a case of 'hide-bound skin.'

"As far as I could collect the facts from the patient, who was an intelligent but perhaps not very observant man, they were as follows : His skin had been quite healthy till the age of twenty-one, and the first thing that he then noticed was that the fronts of his arms were stiff and tight. In a short time all his extremities were involved in the same condition, but not his face. His fingers became stiff and somewhat wooden. The skin of the trunk was not materially affected. By very slow degrees the hide-bound condition had undergone resolution, the skin having been left, however, abnormally thin. When I saw him there was but little evidence of stiffening to be detected, excepting in front of his elbows. He was unable to straighten his arms perfectly, owing to some slight contraction which still persisted in these parts. In his forearms the tendons were very easily seen, as if all trace of fat and subcutaneous cellular tissue had disappeared. His fingers did not show anything very definite, but were perhaps slightly wooden. He said that they were not liable to die, and that he could wash in cold water with pleasure. I could not appreciate any change in the skin of his face, nor any in that of his trunk. In all other parts excepting his forearms there was a fair amount of fat. Mr. T—— consulted me for a disease which had no relation to his skin. He did not think that any measure of treatment had had much influence in his cure."—See *Archives of Surgery*.

Single-Patch Morphœa in a Healthy Man—Partial Disappearance.

"A man named James K——, aged 41, was sent to me by Mr. Herbert Miller, of Stoke Newington, on July 16, 1887. He had a single oval patch of morphœa on the right side of the trunk, just between the navel and the border of the ribs ; it was very hard from tallow-like infiltration of skin, and was surrounded, as usual, by a narrow lilac rim. He had discovered it by accident in passing his hand over the part. It had not caused him the slightest inconvenience. (This patient attended at one of the college examinations for the Fellowship, and was seen by many of my colleagues.)

"In February, 1889, Mr. Miller was kind enough to ask this patient to call on me a second time for inspection. Eighteen months had elapsed since I had seen him. The patch had, I found, to a large extent disappeared. It had thinned away, and a slight depression, with some pigmentation around it, was almost all that remained. There had not been the slightest extension at the borders. It was now very evident that the thick homogeneous patch had been made up by the coalescence of many small spots. The latter had again come into view as absorption had progressed."—*Archives of Surgery*, vol. ii.

piginous spreading. Once healed the scars remain sound. It is also well known that second attacks of zoster are extremely infrequent. The portrait published by the New Sydenham Society in its Atlas of Skin Diseases, Plate XXIII., showed a well-characterised eruption of zoster on the right side of the trunk of a boy, and just above this zone of vesicles is another of scars left by a similar attack some years before. This portrait, however, exhibits what is extremely infrequent, and no parallel to it has ever come under the observation of the writer.[1] Now precisely similar statements are true of herpetiform morphœa. As has already been said, its patches never, excepting in their early stage, enlarge by spreading at their edges. They never persist indefinitely or relapse, and with the rarest exceptions second attacks are never witnessed. The only exception to this latter statement which has come under the notice of the writer, or which has been recorded within his knowledge, occurred in the person of a young girl who had a single patch on the back of one shoulder, which after persisting some years finally disappeared. In this girl, about ten years later, another patch occurred on the same shoulder a little below the first. Her case presented an exceedingly close parallel to that of the boy just mentioned who had two attacks of herpes zoster. In both the patient was young and in both the region affected in the second attack was that of the spinal nerve immediately below that involved in the first.

The Fifth Nerve and "Hemiatrophy of the Face."

When the fifth nerve territory is affected in early life very remarkable and conspicuous deformity of the face may result. There is contraction of the skin, loss of all fat, and arrest of growth of the bones. A peculiar appearance of one-sidedness in the face is the consequence. The earlier in life the disease occurs the greater will be the deformity. In its more conspicuous stage, that is, years after the attack, it is not so much an atrophy as an arrest of growth. It has received the name of "Hemiatrophy of the face," a descriptive but in some respects an unfortunate name, as there can be no doubt that it is a late stage of morphœa.

In Plates C to H we have given a series of portraits, which taken together will afford a very good idea of the appearances produced. In the best marked examples the whole of one half of the face, from the top of the forehead to the chin is smaller than the other. Often a conspicuous vertical furrow passes down the middle of the forehead, nose and chin. Owing to the contraction which has resulted this furrow is seldom exactly in the middle line, the skin being drawn over to the affected side. Sometimes there are two furrows side by side. The roundness of the cheek is always more or less lost, and the somewhat puckered skin seems to cling to the bones and teeth. In Plate G, which represents a very severe case, shrinkage of one lateral half of the tongue is shown, proving that the muscles and fat suffer as well as the more superficial structures. As years go on these evidences of atrophy gradually diminish and become much less conspicuous, but as Plate I, which was taken from a middle-aged man, shows, they never wholly disappear. The bones, which have been arrested in their growth, never overtake their fellows of the opposite side. Most of our portraits are from cases in which all three divisions of the fifth nerve were affected. This, however, is not always the case. In some the upper division may suffer alone, and in some it may wholly escape whilst the middle and lower ones are affected. In some instances only a few twigs from one or more branches are affected, and multiple patches scattered over the face are produced.[1] It may be doubted whether any really well characterised case of bilateral atrophy (involving the whole face) is on record. The early stages of the disease which results in the conspicuous con-

[1] From this statement must be excepted certain well-known cases of recurring herpes, in which the group of vesicles reappear over and over again exactly on the original site. They are, however, never well-characterised cases of herpes zoster.

[1] See Portraits CXX. and CXXXIII.

dition shown in our portraits has hitherto for the most part escaped notice. All the cases appear to have come under observation after the atrophy had become conspicuous. The circumstances that the disease usually commences in childhood and that it is never attended by pain, may perhaps explain this. The proof that "hemiatrophy" is really a late stage of herpetiform morphœa is supplied by a number of instances in which one or more of the limbs exhibited the characteristic conditions of the latter. Thus, in the well-known case of the woman Nichols, whose portrait is given in our Society's Atlas of Skin Diseases (see Plate XLIV.), and who was one of Dr. Addison's original patients, one lower limb had been amputated on account of disablement from morphœa. The fact already mentioned that sometimes only one branch of the fifth nerve is affected, or only certain twigs of one or more, is also conclusive on this point.[1] It is of interest to point out that in all these facts as to its distribution, herpetiform morphœa shows a close similarity to its prototype, herpes zoster, when the latter affects the branches of the fifth nerve.

It is necessary to remember in dealing with the face that the fifth nerve is not its only supply. A branch from the great auricular comes forward in front of the ear and supplies the whole of the parotid region and neighbouring parts of the cheek. On this district, no doubt, twigs from both the second and third branches of the fifth interlace. When the fifth nerve territory is wholly without sensation this part of the cheek always retains it, and in morphœa it is not very infrequently seen to be affected alone. Sometimes, as in a case recorded in *Archives*, vol. ii., p. 230, symmetrical patches of morphœa are seen on this part. In several other cases a patch has been noted on the territory of the great auricular when there were none elsewhere on the face or neck.

There are some very remarkable cases in which, without the development of any ivory patch whatever, the sides of the cheek become stiff and board-like, whilst the nose and the lips, the central parts of the face generally, are unaffected. It is impossible to feel sure that the great auricular nerve explains these conditions, for the area involved may be very ill-defined, and in some instances the central parts do suffer in a slight degree. It must be noted, however, that this condition of exemption of the nose and lips differentiates these cases from those of Raynaud's malady, in which the nose itself is the part of the face to suffer first. Thus, on the whole, it seems probable that when the sides of the cheeks alone become hide-bound, the change is effected by the great auricular.

The cases in which single nerves, and those only small ones, such, for instance, as the short saphena, the great auricular and the humeral branch of the intercosto-humeral, are alone affected may be allowed to suggest the possibility that the disease is often a form of neuritis and does not originate centrally. They are, however, by no means conclusive on this point. Cases in which the morphœa patch is only a single one, or a single group implying the location by only one nerve, constitute only a minority of the cases, probably not a third of the whole. It must be remembered, however, that in the cases in which the patches are multiple, possibly very numerous and, it may be, for the most part symmetrical, there are almost always some patches which indicate the implication of isolated nerve trunks. The phenomenon of bilateral symmetry, which is by no means uncommon, may perhaps be allowed to imply the probability of an affection beginning in a certain segment of the cord rather than in single nerve trunks or nerve roots.

Several of our portraits show ivory patches developed on the faces of adults (see Plates CXXVI., CXXXII., CXXXIII., and CXXXIV.), but we have only one exhibiting this limitation of the disease in a child. It would appear that as a rule herpetiform morphœa is more severe in inverse proportion to age, and it is not difficult to understand that arrests of growth are far more likely to occur in young and immature subjects than older ones. The ivory patch is probably less characteris-

[1] See Portraits D., F. and I.

tically developed in very young children than in those who are more advanced in life, and hence the disease is often overlooked until the stage of shrinkage and contraction makes it obvious.

It is of interest to note that we have exceedingly few examples of involvement of the whole of one fifth nerve in an adult. The case mentioned in the subjoined footnote[1] is almost the only one which has come under the writer's observation.

Distribution by Special Nerves.

Our suggestion being that morphœa patches may, like those of herpes zoster, be located in the area of distribution of any sensory nerve or nerve twig, it becomes of minor importance to describe its occurrence in connection with special nerves. Without, however, making any attempt at completeness of enumeration, it may be of interest to mention a few. The fifth nerve has already been dealt with in speaking of "hemiatrophy of the face." In Plate CXXXII. we show an instance of a patch located by the temporo-malar, and it may be remarked that single patches behind the ear are by no means uncommon. Plates CXXXIII. and CXXXIV. show the patches as distributed by single branches of the fifth. In the upper extremity any branch may be involved, and good illustrations of anatomical distribution are not infrequently seen. The dorsal, intercostal and lumbar nerves are often affected, and in many instances a curved demizone is seen on one side of the trunk, exactly as in zoster.[1] On the lower extremity as in the upper, the illustrations of nerve distribution in the arrangement of the patches is often very obvious. One of some interest occurs now and then in the case of the short saphena nerve. Of this, illustrations are given in Plates B and B *bis*, and at least three portraits collected by different observers show the same distribution.[2] In these the outer part of the ankle and foot are the parts affected.

In herpes zoster it is often observed that the eruption transgresses more or less the territory of the nerve chiefly implicated, and this feature is yet more conspicuous in many instances of morphœa. It would seem as if

[1] Case of Slightly Marked Morphœa Affecting One Half of the Face in a Woman, with Dilatation of the Pupil and Loss of Accommodation.

"Through the kindness of Mr. Nettleship I had the opportunity of seeing an example of fifth-nerve morphœa in which the local changes were singularly slight. You could just notice in a good light that the left half of the forehead was slightly shrunken, and that on the left malar bone, left side of nose, and left half of upper lip, were white ivory-like ill-defined patches. These changes were definite when once seen, but might easily have been overlooked. The patient herself had, in fact, overlooked them. She was extremely lean, and the other side of her face was most unusually thin, and this no doubt helped to reduce the contrast, probably also it restricted the extent of change. By the finger it was scarcely possible to appreciate any hardness, and at no point was it impossible to pinch up the skin a little. It seemed probable from the woman's statement that the changes had been present nearly a year. She had consulted Mr. Nettleship on account of inability to see well with the eye of the affected side. Its pupil was dilated and motionless, and she had paralysis of accommodation. With a + 10" she could read well. The pupil measured about No. 12 in contrast with No. 4 in the other eye. She had been aware for nearly six months that her sight had been failing and the pupil enlarging. She had no deafness, and there was no paralysis of other orbital muscles. On the hypothesis that morphœa changes depend upon some disease of the vaso-motor inducing contraction of blood-vessels, the dilatation of the pupil might be considered to be readily explained, since spasm of arteries and dilated pupil are usually associated. It is not, however, so easy to account for the loss of accommodation, since that function depends chiefly on the third nerve. Indeed it is more probable—noting this combination—that the mydriasis is paralytic than spasmodic—due, that is, to paralysis of the circular fibres supplied by the third nerve. The complication is an exceedingly important one, and may perhaps help to the solution of the enigma as to the true nature of morphœa."—*Archives of Surgery*.

[1] Submammary groups are not very uncommon. Wilson mentions a case under the care of the late Mr. Wood, of Shrewsbury, in which a woman had a patch under each breast.

A group arranged exactly like shingles on the left side of the abdomen of a man is described at p. 329 of "Hutchinson's Lectures," and from *Archives of Surgery* we print the following:—

"Dr. Barlow brought me a gentleman named P——, aged about 32, and, excepting dyspepsia, in good health. For the last two months he had had a belt of erythema with slight induration on the left side of his abdomen. In the middle of this belt a number of white lardaceous spots had slowly developed. The belt was in form and in curve exactly like herpes zoster. It covered the side and front of the abdomen, ending just below the umbilicus. It passed the middle line a little, but not more than we often witness in zoster.

"The lardaceous spots, as big as sixpences, very numerous and ill-defined, were most characteristic, and in the middle of the group there was slight brawny induration. Above and below the group the skin was congested, red, and very slightly swollen. The margins of the erythema were not very abrupt, but still easily noticed. Scarcely any irritation had attended it."

This case is valuable as giving a description of the early stage of Herpetiform Morphœa, and showing that it is attended by erythema and some swelling, although there may be little or no irritation. The little lardaceous spots would appear to be analogues of the vesiclea which occur in herpes, and to be, like them, developed in an area of slight swelling and congestion.

[2] Dr. Bosseau du Rocher has described a case in which this nerve region on the left foot was affected. There were patches on other parts as well. The condition extended from the outer side of the foot over the dorsum.

the products of the process were in their earliest youth capable of infecting the adjacent structures, and of thus causing the patch to spread at its borders (Hunter's "Contagion of Continuity"). That they soon lose this power is quite obvious, for patches of morphœa which continue to extend at their edges indefinitely (as those of lupus do) are unknown. Yet it is impossible to explain the peculiar forms assumed by the patches of morphœa in many cases, without calling to our aid the hypothesis of serpiginous infection and spreading during the earliest stage. There is no doubt that the single spots which constitute the very earliest stage tend rapidly to coalesce, and to produce a patch which is thickest in its middle, and that the tendency to thicken continues for some little time. It has already been remarked that unlike zoster, morphœa is very often bilateral, and thus by the help of the sort of infection just suggested, we easily explain the broad belts which several of our portraits so conspicuously exhibit. It may require a little more ingenuity to account for the curious gyrations and curves which some of these show. It is possible that in the earliest stage the distribution may be influenced to some slight extent by local irritation or pressure. We owe to Dr. Hilton Fagge the observation that patches may be arranged circularly round the leg, apparently in connection with the garters, but this kind of distribution is extremely rare.

The Muscles are usually Involved in Morphœa.

In all severe cases of herpetiform morphœa the muscles suffer. They waste in size sometimes to such an extent that their fleshy parts can scarcely be detected. In others, whilst much wasted, they may pass into a condition of spastic contraction. Thus when the forearm is affected the hand may be fixed in a bent position.

It is desirable that future observers should pay especial attention to the muscular system. Much light may probably be secured by accurate observations in this direction as to the part of the nervous system which is usually involved. Cases of hide-bound skin when the trunk is involved often, perhaps usually, end fatally. It may be that in some of these the intercostal muscles are extensively involved. It is possible that further investigation may show that other yet more important muscles, the diaphragm and, perhaps, even the heart itself, may be sometimes implicated.

Dr. Cecil Biss has published, in the Clinical Society's *Transactions* (1889), the case of a girl, aged 15, in whom morphœa changes occurred in the regions of distribution of the right musculo-spiral nerve. The deltoid and triceps were much wasted and the extensors of forearm to some extent. The conditions had been present four years. Faradic and galvanic reactions of the muscles were unaffected.[1]

Arrest of Growth in Certain Structures.

A very marked feature in the atrophy which attends morphœa is the absorption of fat. This is usually very complete if the disease is of any severity. When occurring in a streak on one of the extremities it may leave the skin tightly stretched over an underlying bone, and when in the front of the forearm the tendons may stand out like cords without any protective padding. Now and then the fat of the orbit may to a large extent disappear.

Although the growth of hair on herpetiform patches of morphœa is not usually absolutely arrested it is almost always hindered. Thus the eyebrows on the affected side in cases of hemiatrophy of the face are never so strong as those on the other. So far as has been observed there is no defect in the shape or size of the teeth, although they may be deficient in number, or crowded owing to the smallness of the jaw. In some cases the salivary glands may

[1] Dr. Thibierge has recently devoted an important paper to the special consideration of the affections of muscles in sclerodermia. It commences with the statement: "Il n'est pas de sclérodermiques dont le système musculair ait conservé son intégrité." He found the reactions under galvanism and faradisation weakened, but not lost.

Mr. Nettleship has recorded a case in which, with morphœa patches on the left temple, forehead, side of nose and upper lip, there was mydriasis and partial cycloplegia. The eye symptoms were of three months' duration. *The patches on the skin had entirely escaped the patient's notice.* Subsequently another patch was found over the angle of the scapula.

appear to share in the atrophy, but upon this point more careful observations are needed.

An important example of arrest of growth as a consequence of morphœa was brought before the Polyclinic by Mr. Sydney Carr in April, 1902. A girl, aged 16, had her mammary gland on the affected side not half the size of its fellow. She had patches of ivory morphœa extending down the territory of the intercosto-humeral nerve and across the upper part of the chest. There was another on the inner side of the thigh of the same side (the right). There was some doubt as to the exact duration of these patches, all of which were now undergoing involution, but they had certainly been present for four years or more. It is not without its interest to note that absence of the mammary gland sometimes attends congenital absence of the thoracic part of the great pectoral muscle.

Influence of Sex.

In estimating the influence of sex in reference to morphœa, it is always necessary to carefully distinguish its different forms. Statements based upon data in which the herpetiform and the acroteric types have been taken together are of little value. The general impression of authors is that the female sex suffers much more frequently than the male. In a thesis presented by Dr. Eugene Collins to the Faculty of Medicine in Paris in 1885, a *résumé* of published observations is given. It comprises a total of 118 cases. Some of them, however, are given too briefly to admit of differential diagnosis. Taken together it represents the female sex suffering almost in the proportion of 3 to 1. If, however, we deduct 27 cases which are definitely of the acroteric type, we then find that the proportion is only 2 to 1. It is possible that if the diagnosis were kept strictly to cases of the herpetiform variety no very great difference in the sexes would be observed. The more typically acroteric forms are met with almost exclusively in women.

The attentive reader cannot fail, however, to have been struck by the preponderance of the female sex in the examples of hemiatrophy of the face which this Fasciculus contains. We have given eight portraits, and amongst these is but one the subject of which is a man. That males suffer with quite equal severity with women is well illustrated by this portrait, which represents an amount of deformation not surpassed by any other.

Is Acroteric Morphœa Always and Essentially Distinct from Herpetiform Morphœa?

It has, we trust, been made sufficiently clear that morphœa maladies range themselves in the main into two groups. In the one we have those in which patches occur—herpetiform or circumscribed—and the other in which there are no margined patches and in which the upper extremities, face and bust are affected with bilateral symmetry. The question now is, are these two groups allied or are they wholly distinct diseases?

Herpetiform morphœa is very deliberate in the evolution of its stages, and as these stages differ widely in the appearances which attend them, we cannot be surprised that they have been described and named as if they were distinct maladies. Thus we have such terms as morphœa lardacea, morphœa nigricans and morphœa atrophica. Indeed, one local form of the latter has even, under the name "hemiatrophy of the face," been assumed to be wholly distinct from morphœa. There can, however, be no doubt that the atrophic conditions represent merely a stage of morphœa and one which in greater or less degree is produced in all cases. It is not by any means always a persistent one, and it is never permanently aggressive. The tendency, after a certain condition has been reached, is always towards amelioration. The expression "*Morphœa atrophica progressiva*" is applicable only to an early stage. The atrophy involves not only the skin but the subcutaneous fat (often in very marked degree), the muscles and even the bones. The cases in which the evidences of atrophy are greatest are always those in which the disease has commenced in a

young person, and in some cases it might perhaps be quite as appropriate to speak of it as arrest of growth. This is a remark which especially applies to what has been called facial hemiatrophy.

As a rule, with but few exceptions, herpetiform morphœa is wholly unattended by acroteric phenomena. The digits are not involved, or if some of them suffer, the condition is neither general as regards the one hand, nor symmetrical as involving both. The face often remains unaffected, or shows only streaks or ivory patches. In spite, however, of these facts, there are others which imply relationship. Although acroteric morphœa is almost always attended by Raynaud's phenomena, yet it differs widely from other cases in which these occur.[1] In the best marked examples of the latter their paroxysmal character is well characterised, and in the intervals of the attacks the skin of the digits remains supple and soft. There is no hide-bound condition of the forearms, nor is the face, excepting the tip of nose and the lobules of the ears, involved. In the morphœa affection a tendency to sclerodactylia is manifest from the first. Lastly, we have the fact that in certain cases the conditions of diffuse acroteric morphœa with sclerodactylia, are present in association with well-marked ivory patches on other parts which may be scattered without bilateral symmetry.

We may then suppose that there are cases in which, with the liability to the peripheral neuritis which produces the ivory patch, there may occur such disturbance in the functions of the cervico-dorsal cord as may produce a hide-bound condition in the face, neck, upper part of bust, and both upper extremities.[1] In these cases the lower extremities are usually also involved but not to any extreme degree.

The history of the onset of the phenomena may often assist us in the recognition of the nature of the case. In those allied to morphœa the onset is usually rather sudden and the sclerodactylia and hide-bound condition of chest and face are developed in the course of a few months and simultaneously. There is no history of long preceding liability to cold extremities and the phenomena of "asphyxia" as described by Raynaud. Possibly, indeed, this history of onset is our safest guide in classification, but it must be remembered that very many persons, even in good health, are liable to exhibit, in minor degrees, Raynaud's symptoms. It may probably be the fact that it is in precisely these persons that, when they are attacked by morphœa the diagnostic difficulties arise.

Thus, then, it would seem highly probable that the diffuse morphœa of the upper extremities, face and bust, is closely allied to the herpetiform type. The occasional association of the two is strongly suggestive of this relationship, and there are many connecting links. Both are attended by the disappearance of fat. Whilst the herpetiform type is at least as common in women as in men, and just as well characterised, the acroteric or diffuse type occurs almost solely in women. It may be that peculiarities of constitution in connection with sex are very influential in giving peculiarities to the phenomena.

A case of much importance in this connection was brought under observation by Mr. T. J. Hitchins at the Polyclinic on several occasions in 1900.

A married woman who had suffered severely from Raynaud's phenomena (or rather acroteric morphœa), and in whom opium had been of

[1] Notes on the Connection between Raynaud's Phenomena and Acroteric Morphœa.

"As regards the association between Raynaud's phenomena, and acroteric scleriasis or morphœa, the following propositions may, I think, be stated.

"The most characteristic forms of Raynaud's malady, or 'paroxysmal asphyxia of the extremities,' are not attended by any induration of the skin.

"Acroteric morphœa may set in quite suddenly in patients who have not shown any tendency to paroxysmal asphyxia of the extremities. In such cases, however, some liability to paroxysmal asphyxia usually follows.

"In some cases after paroxysmal susceptibilities have been present for long, conditions approaching to acroteric scleriasis become gradually developed.

"Thus we have many cases in which one of these conditions exists alone, without any tendency being shown for the other to supervene; we have others in which scleriasis precedes Raynaud's phenomena, and, lastly, others in which Raynaud's phenomena precede and apparently produce scleriasis."—See *Archives of Surgery*, vol. vi.

[1] See several examples of this narrated in *Archives of Surgery*.

much benefit, had large patches of sclerosis of skin and subcutaneous tissues develop in the front of her left thigh and over the buttock. Beginning with slight swelling, these patches became subsequently as hard as bone. Their duration was uncertain, but they persisted without change as long as the patient remained under observation. There can be little doubt that they were really examples of herpetiform morphœa (*See Polyclinic Journal*, vol. iii., p. 242.)

Sir Stephen Mackenzie brought to the Dermatological Society, on February 9, 1893, two most interesting cases, illustrating the two forms of sclerodermia. Both patients were children.

Diffuse Morphœa attended by Sclerodactylia, and, with the exception of the Genitals, universal. Death.

The first of these, a boy of about 14, afforded an excellent example of what used to be known as "the hide-bound condition." His skin everywhere was stiff, and slightly indurated. This condition was, as usual, most marked on the extremities. His fingers were tapered, very pale, and as hard as wood: passing up the fore-arms the condition gradually diminished, but did not wholly disappear. The skin of the face was tight, and his features fixed: he said that he could not laugh; he could, however, shut his eyes and his mouth, the degree of induration being only slight. On the trunk the skin, although still slightly stiff, was much less affected; that of the scrotum and penis was absolutely free from even the slightest degree of induration. It contrasted markedly with that of the adjacent parts of the abdomen. The skin everywhere was very white. There was no actual pitting, but it still looked and felt as if it were in a slight degree swollen. The boy looked ill, and his abdomen was tumid. The account which he gave of his malady was that it had come on rather gradually at a time when he was in his usual health, about six months ago. He had previously had an attack of typhoid fever, but he thought that he had well recovered from it some months before any change was observed in his skin. He had just been apprenticed to a wood-carver; he had found the work too much for him, but he assured us that it did not involve any exposure to cold. Before this illness he had not been liable in any special degree to coldness of the extremities, and had been accustomed to mix with other boys on equal terms.

Conditions resembling those of Raynaud's phenomena had frequently been observed in his hands and feet, but there had been as yet no approach to gangrenous states. The conditions in this lad were both symmetrical and universal (with the exception of the genitals); the hide-bound condition differed only in degree in different parts, and these differences of degree corresponded exactly on the two halves of the body.[1]

Herpetiform Morphœa in a Young Girl. All four Extremities very severely involved but without Sclerodactylia.

Mackenzie's second case was one which some observers had regarded as, like the preceding, an example of "diffuse sclerodermia." From this opinion, however, others differed. The case appeared to the latter to be an example of localised morphœa, with an exceptional tendency to bi-lateral symmetry, which, although deceptive at first sight, ought not to be allowed to disturb the diagnosis. The conditions, although severe and extensive, were far from being diffuse and universal, nor was the symmetry exact. It was a case in which the limbs were chiefly affected, the head, face, and neck having escaped. There were numerous, and characteristic, ivory patches on both extremities, and one, which was small but very definite, on the left side of the abdomen, midway between the umbilicus and pubes. Both hands were bent forwards at the wrist, and there were patches, which appeared to be partially scars, on the back of both wrists.

[1] This boy died a few weeks after the date to which the above notes refer.

The skin on the front of both knees was also somewhat excoriated. Over the greater part of all four extremities the skin was tight and indurated, but this was not quite universal, even on those parts, and although very extensive, the changes were arranged more or less in patches and streaks. In marked difference from what occurs in diffuse sclerodermia, the digits themselves, both of hands and feet, had almost wholly escaped, and their skin was supple and soft. The skin also of the girl's face and neck showed no change whatever, and could be easily pinched up into large folds. The same statement is true, with the exception of a few small patches, of the skin of the entire trunk. The duration of the disease in this case was about a year. It appeared not at all unlikely that the lower limbs might be disabled almost permanently. The hands were in a more hopeful state, although somewhat crippled by contraction. This case may be compared with Dr. Bernard's given as Plate A.

Summary and Conclusion.

The illustrations which are to follow, will, it is hoped, enable the reader to appreciate without difficulty the principal features of this remarkable malady. He will observe the wide differences which may occur as to extent and severity and, at the same time, the essential sameness of the process in all. He will also, in tracing the different stages of the local affection, realise to how large an extent its special features may be modified by the stage which has been reached. The very earliest stage he will see illustrated in the herpes-like group of white lardaceous spots shown in Plate CXXXI. Following on from that, he will find the stage in which these spots have coalesced into one patch (the ivory patch), well shown in Plates CXXXII., and several others. In Plate D is shown one of the most restricted forms; the only evidences of the disease being some small white bands curving round the inner canthus of one eye. In Plates CXXVI. and CXXXIII. we have very similar patches, but involving the greater part of one half of the face. In yet more extensive development, we have in Plates CXXIX. and CXXX. the greater part of the trunk involved either in local patches or broad zone-like bands, and Plates C to H form a noteworthy series in which the whole, or almost the whole, of one half of the face was involved. The lesson will thus have become impressed that differences in the extent of surface involved are wholly without import in reference to the essential nature of the disease. The mind of the observer will even be prepared to recognise that certain cases in which the changes may at first sight seem to involve the entire surface, may yet be of the same nature as others which are strictly or even sparingly localised. Nor will wonder be felt that in the atrophic stage of fifth nerve morphœa the appearances have deceived nosologists and led to their being described under a different name and as a *sui generis* malady.[1]

Amongst the features which, amidst many and conspicuous differences, may be held to imply essential identity in all the maladies which make up the morphœa family, we have the following:

The sudden, though it may be insidious, origin.

The painless development of patches or of slight tumefaction of the part involved.

The peculiar ivory whiteness of the original patches in many cases.

The somewhat prompt disappearance of tumefaction or of thickened white patches, and the shrinkage or leather-like atrophy of the skin involved.

---

[1] In the able article by Dr. Charles K. Mills on what is there unfortunately named "Progressive Unilateral Facial Atrophy" in "Pepper's System of Medicine," we find important items of evidence as to identity of this affection with herpetiform morphœa and the "ivory patch." Dr. Mills, describing a case which came under his own observation, writes: "One of the first signs of the disease is the appearance of a white spot on the cheek. This was the first noticeable phenomenon observed in the above case. After a time this spot or patch may change in colour, becoming of a yellowish or brownish hue. A number of spots appearing and undergoing change, the skin after a time assumes a mottled appearance." He also expresses his suspicion that in those cases in which they had escaped observation "the white spots or patches were probably at first present."

We may add in reference to this point that no one can compare the portraits showing facial hemiatrophy with Plate J. which illustrates atrophy of one lower limb, without being struck by the sameness in the results attained.

The entire disappearance of all fat, interstitial as well as subcutaneous.

The occurrence of paralysis in those muscles associated as to nerve supply with the tracts of skin affected. (It may be of others also.)

The fact that at no stage do the muscles implicated show the reaction of degeneration, and that they remain throughout capable of partial recovery.

That the lesions once established are never progressive. The duration of what may be called the stage of development may be protracted over many months, but once accomplished there is no spreading.

That after full development, and possibly a somewhat protracted duration, a stage of reparation invariably sets in.

That no relapses ever occur, and that with rare exceptions attacks of morphœa occur but once in a life-time.

The occurrence to persons of all ages, and usually without any antecedent departure from good health.

Amongst the above features, common to all forms of morphœa, we may especially particularise the disappearance of fat. It is a most conspicuous character, and one which is scarcely ever absent. The interstitial fat of muscles and every particle of adipose material from the skin disappears, and in cases of reparation it would appear that the fat is the last to be reproduced.

In this implication of the fat tissues we have possibly a bond of connection between the acroteric morphœa (which involves the face, upper limbs, and bust) and the herpetiform morphœa. May it even be conjectured that in "infantile sclerema," an affection in which all the subcutaneous fat assumes stearine conditions and becomes hard as if frozen, the initial impulse is not wholly distinct from that which in older subjects originates morphœa? May it be that the differences in result are to be explained by the age of the patient and undeveloped state of the nervous system in the young infant?

Although we may put aside as improbable the suggestion of Winkler (see p. 103) that a primary arteritis is the cause of morphœa changes, yet there are many facts which seem to imply that a great reduction in the local supply of blood is always present, and is a very important contributory influence. To it we may attribute the disappearance of fat and the wasting of various structures, and the consequent arrest of growth. The leather-like state of the skin finally assumed is very similar to that of a dried-up corpse. How this ischæmia is brought about is the problem. That it occurs under the influence of the nervous system rather than from structural change in the vessels seems almost certain, and the term tropho-neurosis, although it may not help us much, is undoubtedly applicable. What we seem to be compelled to realise alike in morphœa affections as in those of herpes, is that it is possible for the nervous system by, as it were, a sudden and unheralded stroke to be subjected to a disturbance which shall reveal itself by peculiar and very definite local changes. In the case of herpes we know that although, in the majority of cases, we can assign no cause yet that some forms (H. labialis, &c.) are often associated with the phenomena of rigor, and that others are induced by a mineral poison (arsenic). As yet we know nothing of the influences which give origin to morphœa, and only guess that they may probably be of the same nature as those of herpes. Neither malady belongs in the least to country, race, or family, and neither the one nor the other is in any degree contagious.

MEMORANDA FOR FUTURE OBSERVATIONS.

Dr. Byrom Bramwell has affixed to his

In Dr. Mills' essay, already referred to, the following occurs: "Mitchell has reported a case of absence of adipose matter in the upper half of the body. I had an opportunity of examining this patient who was exhibited at a meeting of the Philadelphia Neurological Society, and noticed that both sides of the face presented a striking similarity to the affected side in cases of unilateral atrophy. Mitchell suggests the possibility of separate centres capable of restraining deposits of adipose tissue." Dr. Mitchell's case reads much like one of what some might call acroteric morphœa.

See "Atlas of Clinical Medicine," vol. i., part iii., p. 104.

excellent summary of facts as to "Hemiatrophy of the Face," detailed notes as to the examination of such cases, both during life and at the post-mortem. To this we may refer our readers, and must content ourselves with very briefly directing attention to a few salient points:—

1.—Be careful to record as fully as possible the facts as to the earliest stages.

2.—Note the state of the muscular system.

3.—Never neglect to inspect the mouth, tongue and palate.

4.—Record whether any condition of sclerodactyly be present; it is the cardinal symptom which distinguishes the diffuse or acroteric from the circumscribed or herpetiform group.

5.—If the skin be extensively involved, note carefully whether any parts remain quite healthy.

6.—Be careful to keep your patient's address, and make arrangements for occasional inspections during future years. Completed or well-extended case-narratives are incomparably more valuable than the fragments which are but too often all that are offered us.

Bibliography.

The literature of Morphœa is very extensive, and many excellent essays have been written on it.

A very extended, but yet very incomplete, *Tableau historique Résumé des principales observations de Sclerodermie*, will be found appended to the thesis of M. Eugène Collin, to which we have already referred.[1] This table gives the titles of no fewer than 118 papers.

Amongst more modern writers the essay of Eulenberg in Ziemmsen's "Cyclopædia" and those contained in Pepper's "System" and Bramwell's "Atlas" are amongst the most important. Dr. Colcott Fox, Dr. Radcliffe Crocker, and Dr. Bannister (U.S.A.), have all made important contributions to our knowledge, and in the *Archives of Surgery*, vols. i. to x., may be found the records of upwards of seventy cases, personally observed. Some of these are detailed, but others, unfortunately, are only fragmentary.

Without attempting anything in the way of an Index, the following references to important facts mentioned in our letterpress may perhaps be acceptable:—

A transitory œdema is often the first stage. See description of Plates A, C *bis*, I.

Atrophy of one-half of tongue is mentioned in description of Plates C, G *bis*, H.

Sinking-in of the Eyeball is mentioned in description of Plates E and I, G *bis*.

Association of hemiatrophy of face with herpetiform morphœa of limbs. See description of Plates C *bis* and G *bis*, footnote page 109.

Shrinking of Eyeball, see descriptions of G *bis*, I.

Arrest of growth of digits, G *bis*.

Teeth fallen out, Plate I.

Teeth retained in spite of severe arrest of growth of jaw, Plate G *bis*.

Ophthalmoplegia is mentioned at page 109.

Atrophy of Glands.

[1] This thesis, together with a very large collection of published matter from other sources, may be consulted in the Library of the Polyclinic. See Extract Books, vol. cxcix. and vol. cxcix A.

PLATE CXXVI.

HERPETIFORM MORPHŒA AFFECTING UPPER EXTREMITY AND FACE.

The subject of this case was a young man in whom the disease had existed for more than a year. Ivory patches of the ordinary characters were present on his face, neck and right forearm. They were everywhere abruptly circumscribed and there was no tendency to the diffuse hide-bound condition. The hands were not affected. On the face some of the patches were arranged with bi-lateral symmetry, but it will be seen that those which surround the outer commissure of the lips on the right side have no representatives on the left. The distribution on this part of the face is almost exactly similar to that shown in Plate CXXXIII.

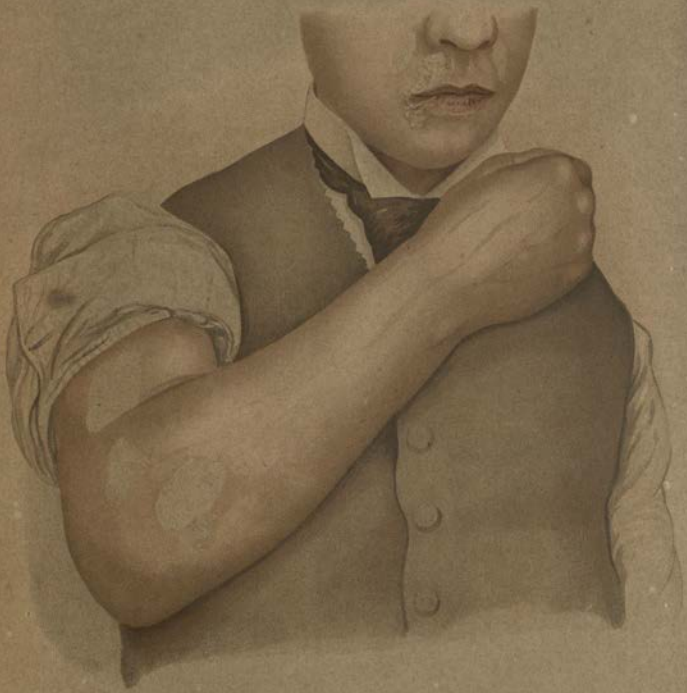

Hills & Saunders, Ltd., London.

PLATE CXXVII.

MORPHŒA IN TWO PATCHES ON THE BACK OF A CHILD.

In this plate, which shows the back of a girl of seven, we see displayed two ivory patches which are quite characteristic. They are placed one on the right and the other on the left of the spinal processes of the vertebræ, and the positions suggest location by the short posterior branches of the dorsal nerves. When herpes zoster affects the dorsal nerves it is usual to find—in addition to the well-known leash of vesicles curving forwards and a little downwards on the side of the chest—a small isolated group exactly in the same relation to the spine which these occupy. It will be seen that they are not on the same plane, the one on the right being two or three vertebræ lower than the other. In each instance an oval patch of bluish-white is surrounded by a border of reddish-brown, with a slightly marked lilac tint. They were of two years' duration.

These patches had no doubt been produced by the coalescence of a group of smaller ones, but the early stage had, as usual, escaped observation.

(Annie Halloran, *ætat* 7, April 14, 1897.)

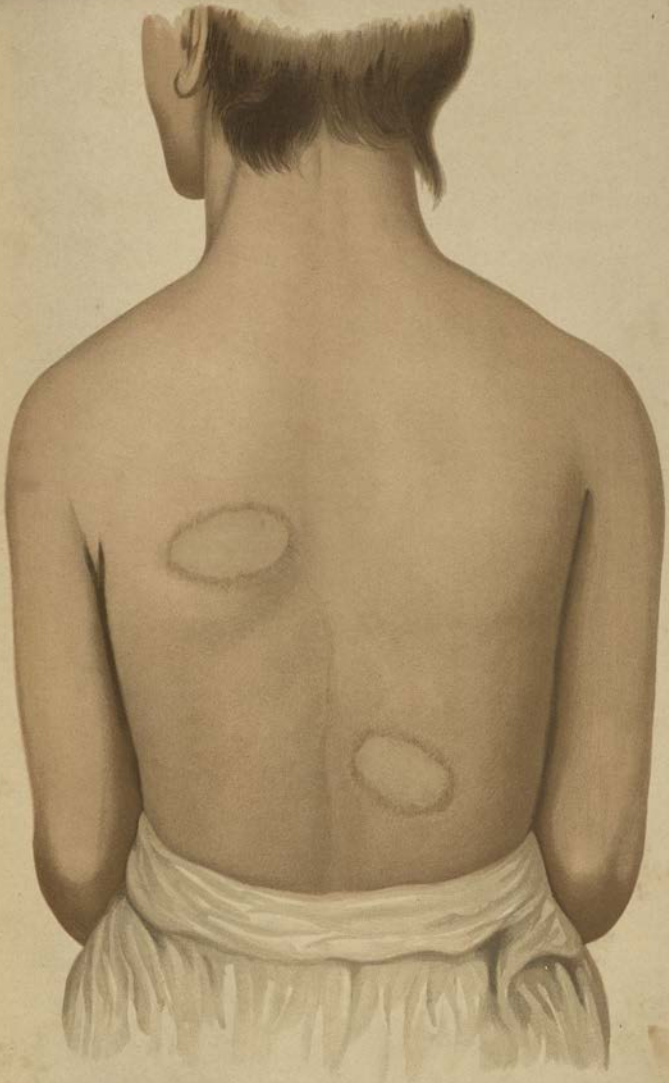

Bale & Danielsson, Ltd., London.

PLATE CXXVIII.

HERPETIFORM MORPHŒA IN GROUP UNDER THE MAMMA.

This plate exhibits the ivory patch of morphœa as it occurred under the left breast of a young woman in excellent health. The patch consists of two halves which have very nearly coalesced, and near to them are indistinctly shown a few other very small ones. The borders of the principal patches are very irregular, a condition caused no doubt by the junction of smaller ones.

The lilac-tinted margin which often surrounds these patches is, in this instance, not conspicuous. The patch had been present nearly a year, but as usual the exact date of its commencement had not been observed. It had ceased to enlarge.

Bale & Danielsson, Ltd., London.

PLATE CXXIX.

MORPHŒA HERPETIFORMIS ARRANGED IN BILATERAL ZONES.

Mrs. Emma A., aged 50, a widow of seven years, had had good health through her life. The first appearances of her present eruption were some small white spots on the abdomen. They itched a little but were not painful. Others soon appeared on the shoulders, &c., and the eruption in the course of two or three months was fully developed.

Mrs. A.'s case is of much interest, as an example of almost symmetrically bilateral morphœa in which the patches were arranged somewhat in zones. It affected her shoulders and chest, and her hips and fronts of thighs, wholly omitting all the mid-region of the back. The front of the abdomen, however, was not entirely free. It might be said to be almost a trunk eruption (leaving out, as just stated, the middle); for it did not pass so low as the elbows on the upper extremities, nor so low as the knees on the lower ones. The bilateral symmetry was not, however, exact; for one buttock and hip had very many more patches than the other. The patches were somewhat peculiar in themselves. They were of a white ivory tint, but very much less thickened than is usual. They were not attended by any of the brawny condition which is so frequent. They were also, at least some of them, somewhat rough on the surface, approaching the condition of the orange-peel state of lupus sebaceus. Some were even scaly and resembled psoriasis. There could be no doubt, however, as to their real nature. The patient was a widow-woman who gained her living by charing. She was in good health, and, excepting that she had been troubled with constipation and headache, she had not experienced any disturbance of health premonitory to the outbreak of the morphœa. Her impression was, as is usual in these cases, that the patches were increasing, but on pressing her on the point, there did not appear to be any reason to think that they had increased either in number or size since they had attained their development. They had probably occupied about two months in the process of coming out. The patient was under the care of Mr. Stephen Paget.

The original portraits by Miss Green are preserved in the Clinical Museum.

In association with this portrait it may not be without interest to append the following narrative, which describes an almost exactly parallel case. It is taken from *Archives of Surgery*, vol. vi., p. 363.

HERPETIFORM MORPHŒA OF EIGHTEEN MONTHS' DURATION—SEVEN PATCHES, MOST OF THEM SYMMETRICALLY PLACED ON TRUNK — NO SPREADING — PATIENT A NERVOUS WIDOW, AGED 58, LIABLE TO HEADACHES AND ATTACKS OF HORIZONTAL HEMIOPIA.

"The case of Mrs. S., a widow, aged 58, was of interest on account of certain nerve symptoms. She had had a great deal of trouble and mental anxiety. Her husband had suffered for four years from frequent attacks of angina, and she had been told that he might die at any time.

"Although in early life not in the least nervous, she had become exceedingly so of late. Amongst the symptoms that had been developed was a fixed headache in the back of her head and a liability of her fingers to become numb. She said that she was never free from a dull headache, which 'took all the spirit out of her.' She had been for twenty years a total abstainer. The skin of her scalp would sometimes become so tender that she could not bear to touch it.

"Amongst other more marked symptoms were a liability to attacks of hemiopia, with occasional blindness of the left eye, and the development of a few very superficial patches of ivory morphœa. On one occasion her left eye had become for a few seconds quite blind, and when she shut the other she was in total darkness; on three or four other occasions she had lost the lower half of the left field The attacks were always preceded by a few minutes of giddiness. The hemiopia rarely lasted more than a few seconds. There were no changes in the fundus.

"*The Morphœa.*—Mrs. P. thought she had had the ivory patches for about eighteen months; they had not increased, nor had any new ones formed. One was placed on the outer part of the right thigh; two large and symmetrical ones extended along the clavicular regions; one crossed her body below the navel, and another crossed the back. She called them 'white scars,' and they were so thin and superficial that they might have escaped observation; but they were of considerable breadth, and in an oblique light showed the distinct glistening of an ivory patch. They had been somewhat irritable when first observed, but not so recently."

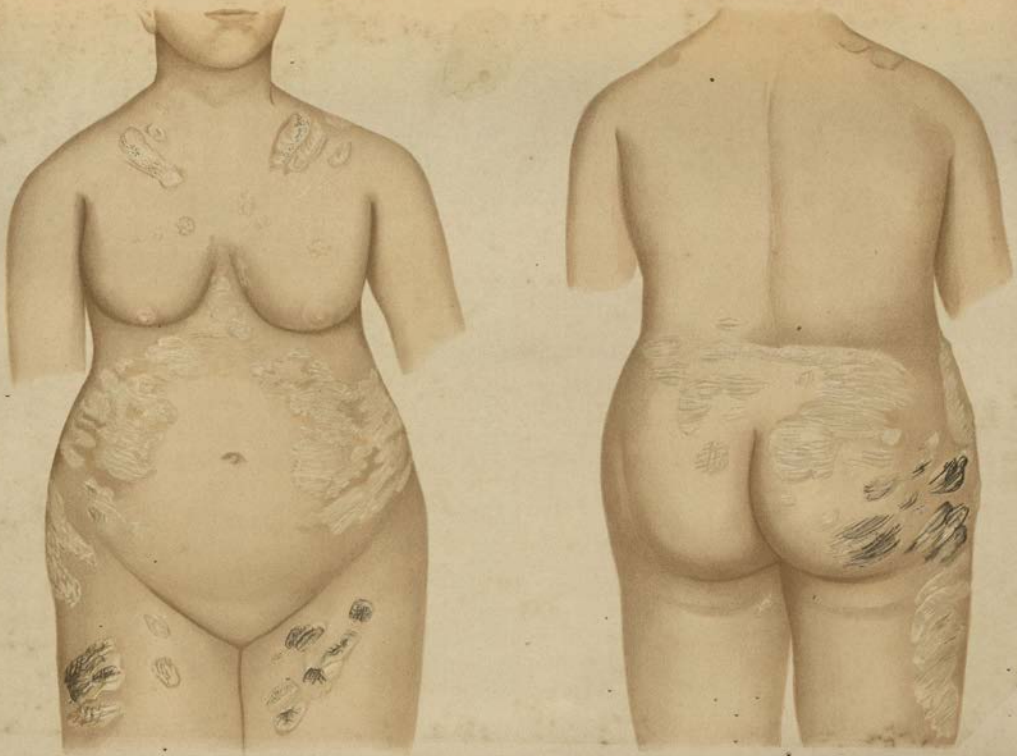

Bale & Danielsson, Ltd., London.

PLATE CXXX.

MORPHŒA HERPETIFORMIS ARRANGED IN BILATERAL ZONES.

These portraits—which must not be regarded as much more than maps indicating local arrangement—show the positions taken by patches of ivory morphœa in a young girl. The disease had been present for more than a year. The patient was otherwise in excellent health. It will be seen that the patches were arranged somewhat in zones, and that although in the main symmetrical, there were some definite deviations from bilateral sameness. Thus, there was a patch on the left side of the back of the neck which had no representative on the right, and one on the front of the right upper arm which had no fellow on the opposite limb. The patches which curled round the scapulæ were fairly symmetrical, and were continued on the front of the chest by a broad band passing under the mammæ, which was quite so. The symmetry was almost exact on the buttocks and fronts of the thighs. A large patch curled round above the crest of the left iliac bone, which had no definite representative on the other side. The limbs in this case were exempt, with the exceptions already noticed. No one looking at these plates can doubt that the patches were in some way arranged through the influence of the nervous system, but at the same time it is difficult to assign all the separate patches to the distribution of any known nerves.

See *British Medical Journal* for June 29, 1895.

N.B.—This plate has been, in error, numbered CXX. instead of CXXX.

Hale & Danielsson, Ltd., London.

PLATE CXXXI.

HERPETIFORM MORPHŒA IN ITS EARLY STAGE.

This plate is of great value as illustrating a stage of the morphœa process which does not very frequently come under observation. Small white lardaceous spots are seen grouped together in a long oval patch which in arrangement much resembles one of herpes zoster. It is also in a position (lying lengthwise over the clavicle) which is not unfrequently seen in herpes zoster. At a somewhat later stage these spots would probably coalesce and a single, thick, ivory patch would be the result. This early stage is very usually overlooked, since the condition is not attended by any pain or discomfort. In the present instance the patient had no patches elsewhere.



Bale & Danielsson, Ltd., London.

PLATE CXXXII.

HERPETIFORM MORPHŒA AFFECTING THE TEMPORO-MALAR NERVE.

In this plate a large, well-characterised ivory patch is seen on the left temple of a middle-aged man. It extends vertically from a little below the top of the forehead almost as low as the commissure of the lips. Its conditions are the usual ones: a dense, slightly raised patch of dirty white colour, thinning off at its edges, and surrounded by a narrow border of blue-tinted congestion. Its margins are for the most part abrupt and quite definite.

The patient had no other patches and was in good health. This patch had been recognised for more than a year.

Several cases, exactly resembling this, and showing morphœa changes in the area of distribution of the temporo-malar nerve have come under the Editor's observation. In all this nerve was alone affected.

[For notes of a similar case (in a Japanese) see *Polyclinic Journal* for September, 1903, page 446].

Hale & Jamieson, Ltd., London.

PLATE CXXXIII.

HERPETIFORM MORPHŒA AFFECTING BOTH SIDES OF THE FACE, BUT NOT WITH BI-LATERAL SYMMETRY.

This plate may be contrasted instructively with Plate CXXVI., for the distribution as regards the lower part of the face is almost exactly similar. White ivory patches are seen on both sides of the forehead; in streaks extending down each cheek from the side of the nose, nearly to the corner of the mouth; in an irregular patch surrounding the outer commissure; and in a large patch on the right side of the neck. Their arrangement would suggest location by various branches of the fifth nerve and of the cervical plexus. Although bi-lateral they were not symmetrical, for no patch surrounded the left commissure of the lips, nor was there any on the left side of the neck. The patient was a young man in whom the condition had been present for four months.

There was a patch behind the right ear but none behind the left. On the right side of the chest over the line of the tenth rib there was a patch which had no fellow on the other side.

The first patch had been observed in the lip about four months before the portrait was taken.

Hale and Danielsson, Ltd., London.

PLATE CXXXIV.

HERPETIFORM MORPHŒA AFFECTING THE FACE OF A WOMAN (SUBSEQUENT REPARATION).

This plate is of much interest in connection with the preceding one and Plate CXXVI. All three show that when the fifth nerve is affected with morphœa separate branches may be involved and not necessarily the whole nerve. The cases much resemble each other. In all three the upper lip is involved and on one side the commissure of the mouth. The subject of the present case was Miss P., then aged 29, who came under Mr. Hutchinson's observation in 1899 and again at his request in 1904 (see below). The portrait shows the condition on the first of these occasions, more than a year after the first symptoms had been noticed.

On March 24, 1904, the patient attended for demonstration of her recovery at the Polyclinic. All traces of the ivory patches had disappeared, but there remained depressions as of subcutaneous scars in several parts. A furrow not very conspicuous ran up the middle of the forehead. There was a definite depression near the top of the nose on its left side and a vertical brown stain crossed the upper lip. A number of dimple-like depressions were seen on the left of the chin and over an area the size of the end of the thumb, the skin was still shrunken and close down on the bone. No differences were observable in the state of the cheeks or the eyelids of the two sides. There was no absence of fat in the substance of the cheek, nor was there any degree of sinking in of the eyeball. The tongue was not in any degree wasted and there was no evidence of any muscular failure.

This case affords a good example of reparative chances. It seems quite possible that in the course of a few years there will be no obvious deformity remaining, and even at present what there is might easily escape notice.

It would appear that only certain portions of the fifth nerve were affected and that the middle division almost wholly escaped. The middle of the cheek never presented any changes, nor was the outer half of the forehead in any way affected.

Bale and Danielsson, Ltd., London.

PLATE A.

BILATERAL HERPETIFORM MORPHŒA INVOLVING ALMOST THE ENTIRE SURFACE.

The patient whose condition is shown in this plate was a boy, aged 14, under the care of Dr. Bernard, of Londonderry. Dr. Bernard took sufficient interest in the case to induce him to bring the lad to London at the time of the International Congress of Dermatology, when he was seen by many authorities. It is a good type case of the group to which it belongs, and the value of the narrative is much enhanced by the fact that it is brought up to present date and record made of an almost perfect recovery.

1895, aged	13.	Legs and arms became swollen and stiff. Seen in November by Dr. Bernard.
1896, ,,	14.	Consultation, June; conditions at their height. (Date of photograph.)
1897, ,,	15.	
1898, ,,	16.	Slowly improving.
1899, ,,	17.	,, ,,
1900, ,,	18.	,, ,,
1901, ,,	19.	Reported well, tall and stout; can walk as well as ever he did.
1902, ,,	20.	His fingers still contracted.
1903, ,,	21.	
1904, ,,	22.	Now living in Canada and quite well.

The photograph is unfortunately faded. It shows, however, well enough the atrophied condition of the limbs, an atrophy involving not only the skin, but the muscles also. It will be observed that the left forearm is more wasted than the right. In the original photograph there are bands of depression from contraction of the skin, just such as follow the ivory patch morphœa. They have unfortunately escaped reproduction in the copy.

Although it might seem at first that the term "diffuse" is applicable, and that the case differed in essential features from those of the herpetiform group, yet attentive consideration of the facts seem to make it clear that the difference was rather in its extent. It was preceded by a transitory œdema, and it was arranged in belts. Thus the uppermost part of the chest escaped, as did the abdomen, the buttocks, and the central parts of the face. Moreover, Dr. Bernard's notes describe white areas, behind the ears and elsewhere, in terms which fit well with the ivory patch in its minor form. That the muscular system was involved even more severely than the skin may be inferred from the fact that the mouth could not be widely opened, although the skin of the face for the most part escaped.

The following is a summary of Dr. Bernard's notes as kindly supplied by himself.

"On November 9, 1896, David Campbell, aged 13, was brought by his mother to my room walking with the aid of a stick, stiffly and cautiously, the heels being raised, the right more than the left. He is the youngest of nine children, and is of a neurotic inheritance. He had at all times good health up to April, 1895, when his legs and arms became stiff, and afterwards became swollen. He then commenced to lose flesh and the wasting became general, and he is now only 6½ stone. The left limbs are more wasted than the right, but the left thigh is very little less in measurement than the right. His skin is hard, brown and tight all over, except in the gluteal regions. He cannot open his lower jaw to protrude his tongue more than what will admit of the tip. Knee-jerks, taste, smell, hearing, sensation, normal.

"I did not see him again until Sunday, June 14, 1896, when I brought Dr. Donaldson and Dr. Fred Craig to search more minutely into his condition. Annexed is a copy of the notes then taken.

"In January, 1895, he first began to feel a little stiffness in his legs and arms, this stiffness increased so much that by May, 1895, it was remarked by his mother, who noticed that when sitting down in a chair he sat down "all in a piece."

"In June, 1895, his mother observed that his legs were swollen up to his knees, and that the swelling was of a hard character; this swelling gradually increased, so that by the end of three months from its appearance it had extended on to his thighs, body, face, head and arms. The swelling when fully developed remained for about three months, and then gradually disappeared from all parts of the body at the same time. With the beginning of the disappearance of the swelling a brownish discolouration of the skin set in on the legs, arms, back of shoulders and loins.

"*Present Condition*, June 14, 1896.—His body is wasted; he cannot stand or walk without assistance; he stands on his toes with his heels well elevated, his knees flexed, the right knee being more flexed than the left, so that more of his weight is thrown on the toes of his left foot. When he walks he treads on his toes. When walking

the skin over the point of his heels and Achilles tendons becomes blanched. The toes are slightly flexed and almost immovable, the toes of the right foot being more flexed than those of the left. The skin over the feet feels dry, hard and thick, with a shining surface; it is extremely tense, and cannot in any way be pinched up or moved over the subjacent tissues; it is discoloured in parts, especially around the ankles, by a brownish pigment. The skin over the balls of the toes can be slightly moved over the subjacent tissues. His legs are greatly wasted: the skin covering his legs presents the same characteristics as the skin over the feet, and gives one the impression as if it were firmly bound down to the bone, especially over the lower or tendonous part of the leg. The skin is slightly wrinkled over the front of the knees and inclined to be scaly. The skin over the right patella is redder and more tense than that over the left, and the right knee-joint is in circumference a quarter of an inch more than the left. The ankle and knee-joints can only be flexed and extended slightly. The thighs are wasted, the hide-bound condition of the skin is not so well-marked as in the legs, nor is it so well-marked on the posterior and inner aspect as on the outer and anterior; on the outer and anterior part of the right thigh it is more marked than on the left. The skin over the popliteal space is browner than on the thighs. The skin covering the penis and scrotum is perfectly normal. The skin covering the abdomen is scarcely, if at all, bound down or thickened, but it exhibits a slight patchy discolouration. The skin over the front of chest from the nipples down, for a distance of 3½ inches, is slightly bound down and pigmented. The skin over the pectoral muscles is normal in appearance and not bound down. The skin on top of the shoulders is firmly bound down, brown and shining. Around the loins and sacral region there is a well-marked bronzing of the skin, over the upper part of the scapulæ it is also bronzed; the skin over these bronzed parts is hard and bound down. The skin covering the lower six or seven dorsal vertebræ and ribs is normal. The skin over the lower part of the gluteal region appears normal, while that covering the upper part is markedly bound down and hard. His fingers remain in a semi-flexed position, they can be moved a little, but not sufficiently to grasp a small round object, such as one's finger. The thumb is straight and cannot be flexed to any extent. The thenar and hypothenar muscles are wasted, and the skin of the hands presents the same characteristics as the skin of the feet. The forearms are wasted and the skin tightly bound down and discoloured, the brownish pigmentations being more marked on the extensor than on the flexor aspect of both forearms. The elbow-joints cannot be fully extended, they can be fairly well flexed and he can feed himself. The skin is not so hard or so tightly bound down in front as in the back of the elbows. The arms are not so markedly affected as the forearms, and the discolouration is more marked over the triceps muscles. The neck is free except a patch under the chin, which is bound down and hard. Behind and below both ears, over the upper part of the sterno-mastoid muscles, there is a hide-bound condition of the skin, which on left side presents the appearance of a white cicatrix surmounted by a brown patchy discolouration. The eyelids are not affected. The hair and skin of head appear normal. He has no difficulty in swallowing. His knee-jerks are present. Sensation is unimpaired. His optic discs are normal. He has never suffered from any coldness, numbness or pains."

Report of Progress and Present Conditon.

The above notes bring the case up to the date of the Dermatological Congress, when the boy was produced in London. Fears were expressed on that occasion that some complication might ensue and bring about a fatal result. Especially was it thought possible that the function of respiration might become embarrassed. Fortunately, however, the upper part of the thorax was not implicated and nothing untoward followed. The boy returned home and continued for some time in much the same condition, but after two or three years slow improvement set in. The brief "space-for-time" schedule already given records the principal facts in orderly sequence. In December, 1901, the boy's father wrote in reply to Dr. Bernard's enquiry, "My son is in good health. He has grown tall and stout, but the joints of his fingers and toes are the same as when you last saw him. He can walk as well as ever." In reference to the present publication of the case, Dr. Bernard was good enough to again institute enquiries, and was informed that the patient, now a young man of 22, is engaged in business in Canada and in very good health. It is believed that some of his fingers are still contracted, but he can use his hands well.

This case may be compared with the two of Sir Stephen Mackenzie's, recorded at p. 118. Its true parallel is the second of them. It is of great clinical value as affording a connecting link between "Herpetiform Morphœa" and the hide-bound condition which has often been described as "Diffuse Morphœa."

PLATE B.

MORPHŒA AFFECTING THE SHORT SAPHENA NERVE (WITH OTHERS).

This portrait is copied from one which, in 1893, was kindly supplied to Mr. Hutchinson by Dr. H. Jones, of Liverpool. It was taken from the foot of a labouring man, aged 26, who was in robust health. The area of the distribution of the short saphena nerve was affected, but the morphœa conditions were not confined to it, for there was another patch on the inner side of the foot, and the sole was also involved. The ulceration near the heel is not dissimilar from that shown in Plate J, but more extensive. The whole area was of yellowish, tallowy whiteness, and, as is seen in the plate, the margins of the patch were were very abrupt.

Dr. H. Jones kept this man under observation for several years, during which time the condition of things very much improved. The ulcers healed and the hide-bound condition became much mitigated. The final result is, however, not known. The patient at no time allowed himself to be incapacitated from his work.

(Compare with Plate J.)

PLATE B *bis.*

MORPHŒA PATCH ON THE FOOT (SHORT SAPHENA NERVE TERRITORY).

The patient was a woman named Bruce, aged 63, whose case has been published in detail in the *British Medical Journal* and in the *Archives of Surgery*.

About a year before the portrait was taken she had first noticed a reddish patch on the dorsum of the foot near to the little toe. In the course of a month or two the whole outer side of the foot had become indurated and resembled in colour yellow ivory. The margins of the patch when she came under observation were quite abrupt, but the patch itself was very irregular in shape. There could, however, be no doubt that it was, in the main, located by the distribution of the short saphena nerve. The two inner toes were drawn upwards and fixed by the contraction of the skin. During the last month or two a hard-edged ulceration had formed at the upper border of the patch. The sole of the foot was not affected excepting in the middle part. There had been but little pain in the ivory patch itself, and no definite loss of sensation could be proved. The patient had no patches elsewhere.

This plate should be compared with the preceding one. For details see Extract Book **199,** A. page 121, or *British Medical Journal.*

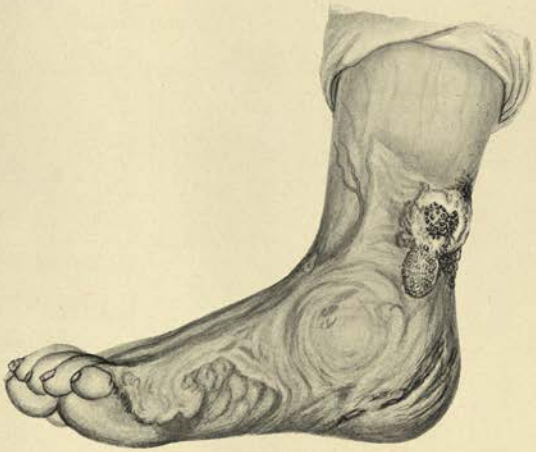

PLATE C.

MORPHŒA OF FIFTH NERVE FOLLOWED BY HEMIATROPHY OF FACE (TWENTY YEARS INTERVAL).

The following are the particulars of this patient's case, as recorded in the *British Medical Journal* for March, 1897, by Eugene S. Yonge, M.B., at that time Assistant Medical Officer at the Manchester Hospital for Consumption and Diseases of the Throat.

"The patient, a woman aged 41, first noticed something wrong with her face twenty-one years ago, when she had an attack of intense facial neuralgia on both sides, lasting, with short intermissions, about six months. Her friends remarked at this period that the right half of her face had become slightly different from the left, and the asymmetry steadily grew more noticeable until nine or ten years ago, since when little or no change has been apparent. At the present time the atrophy is found to involve the right malar bone to the greatest extent, the corresponding frontal coming next in order. The skin on the affected side is furrowed, wrinkled and thinned, and the superficial veins stand out in bold relief. A well-marked vertical furrow on the forehead separates the healthy from the diseased portion. The jaw, which is somewhat atrophied, is shorter and shallower on the right side, and that half of the face, in consequence, does not appear as long as the opposite half. The cartilage of the nose is wasted unilaterally. The muscles evidence no change in size, voluntary power or electrical excitability. The corresponding half of the tongue is slightly atrophied; sensation in the cutaneous area on the right half of the face is unchanged, and neither the temperature nor the secretion of saliva or tears is deranged."

PLATE C *bis*.

HEMIATROPHY OF THE FACE FOLLOWING MORPHŒA, AND ASSOCIATED WITH HERPETIFORM MORPHŒA OF ONE LOWER EXTREMITY.

This portrait is from a case which may almost claim historical interest, since it was one described by Dr. Addison himself. The patient (Mrs. Nicholls) was subsequently under the observation of Dr. Hilton Fagge, Dr. (now Sir) Hermann Weber, and lastly of Mr. Hutchinson. Her case has been published repeatedly, and will be found in some detail in the catalogue of our Society's Atlas of Skin Diseases. One of the woman's lower limbs was amputated in Guy's Hospital on account of the crippling consequent upon morphœa. The case is therefore of exceptional value as showing the association of fifth nerve morphœa with the same affection on other parts, and thus affording proof that the so-called "Hemiatrophy of face" is really a result of morphœa.

The following is a brief *résumé* of her case which was written in 1874. "The disease commenced in 1851, when she was 14 years old, and, according to her statement, very suddenly. She went to bed quite well, and in the morning found her left lower extremity stiff and painful. The stiffness was attended by cramp and was especially felt about the hip. This was quickly followed by swelling of the limb, which she describes as having been very great, and as involving not only the whole of the lower extremity, but the haunch and even the whole of the left side of the trunk. No other parts were at this time affected. She was confined to bed for some months with this state of things, and it was not till nearly a year later, when the swelling had a good deal disappeared, that the disease was first diagnosed. At this time changes had taken place at other parts of the body.

"About two years later, in December, 1854, she was sent into Guy's Hospital under Dr. Addison's care. She had previously been in St. Thomas's Hospital on account of an ulcer on the left instep, which had healed, but subsequently again opened. Under Dr. Addison's direction, at this date, nearly four years from the commencement of the disease, portraits were taken, which are now preserved in Guy's Hospital Museum (158[a], 158[b]). She was now 18 years of age, but had never menstruated. The left lower extremity was wasted, the knee, ankle, and great toe-joints stiff (probably also the hip), and the skin of the leg hard, smooth, and adherent to the tibia. There was a large ulcer on the dorsum of the foot. There was a patch on the left forehead, white in the centre, with a brown border, and some wasting of the skin about the left side of the chin. On the right shoulder was a patch of dull ivory-white colour, below which the skin was brown and desquamating. The right breast presented an irregular brown patch. Nearly the whole abdomen was of a yellowish-brown colour, this being especially deep beneath the breasts, and extending also downwards along the inner side of the left thigh and leg. The right arm and forearm were much affected, presenting white marks and spots, as well as yellowish-brown patches. On the back, the shoulders, loins and right gluteal region were all affected by similar changes.

"From the date of Dr. Addison's notes the disease appears to have been arrested, and the tissues affected have been in gradual process of repair. The ulcer on her left instep, however, never healed; and the limb being an incumbrance to her it was, as already stated, subsequently amputated. Dr. Hilton Fagge sought her out in 1867, and his notes describe in accurate detail very much the conditions which are now present. The reparation has really been wonderful. The tracts of skin which were formerly indurated and discoloured are now supple and show scarcely any peculiarities. The hip-joint of the limb amputated is quite stiff. The stump is sound, but shrivelled, and shows a little brown discolouration of skin. On the left arm there are two 'oval, flat, white, superficial cicatrices, the skin of which is quite thin and non-adherent."[1] There is another patch below the elbow, for the most part white, but crossed by livid trabeculæ. The remains of disease in the right lower extremity are exceedingly slight. The skin is a little less movable on the leg than usual and she states that she feels some stiffness in the limbs. It will be observed that the deformity of the face is very marked. A vertical line passes down the middle of the forehead, nose and chin, deviating, however, a little towards the left side, more especially in her chin. Her cheek scarcely shows any evidence of disease: it is simply less plump than that of the opposite side. The skin of the left side of her forehead, however, although it has improved during the last few years, is still very perceptibly brown, dry, thin, and slightly rigid. On the right shoulder, where at the time of Dr. Addison's report a white patch existed, there is at present only an obscure brown-and-white mottling. "Along the arm and forearm a distinct line of discolouration, about an inch broad, may be traced. This runs over the inner side of the biceps muscle, in front of the elbow, and down to the root of the thumb. On the dorsal surface of the hand, over the base of the second metacarpal bone, is a very slight brown discolouration. She says that there is still a stiffness in the hand and not the power in it that there is in the left hand. The skin of all these parts feels exactly like that of those which are healthy. There is not the slightest adhesion to the subjacent parts."

The following points in this case appear worthy of especial attention:—

(1) *The spontaneous recovery, to a very large extent, of some of the parts affected by scleriasis.* This also I believe to

---

[1] In this place as well as in several others I have borrowed Dr. Fagge's words.

PLATE C *bis.*—(*Continued.*)

---

be according to rule. I have witnessed this course of events in several cases, but I do not know of any recorded case in which it is so definitely illustrated as the present one.

(2) *The affection of the deeper structures as well as the skin.* This was shown in the limb which was amputated, in which the hip and knee-joints were anchylosed, the ankle and great-toe joints stiff, the muscles wasted, and the entire limb withered.

(3) *The occurrence of an attack of acute œdema in the limbs first affected.* This has been frequently noticed in other cases.

(4) *Although the changes were almost general in distribution they were nowhere bilaterally symmetrical.*"

A coloured portrait of this patient is given in the New Sydenham Society's Atlas, and the above particulars are abbreviated from the Catalogue.

PLATE D.

MORPHŒA PATCHES ON THE LOWER EYELID IN A YOUNG BOY.

This portrait is of interest on account of the restriction of the disease to a very small part of the face, and from the early age at which the disease had commenced. Some whitish ivory bands are seen extending from beneath the inner canthus of the left eyelids outwards and downwards on the cheek. The patient, who was a boy aged 5, had none elsewhere. The eyelashes above the patches were lost, and the lid slightly everted. The patches were said to have been noticed when he was two years old. The conditions had thus been present for three years at the time the portrait was taken, and they were quite characteristic. The part affected is one which not infrequently suffers in the minor forms of herpes ophthalmicus. The location of the patches was no doubt due to twigs of the infra-trochlear nerve. There were present also some peculiar appearances, whitish streaks, &c., on the hard palate of the same side. On the eyelid the patch included its edge, but did not extend upon the mucous membrane. The case illustrates the loss of hair which is usual when a morphœa patch involves a hair-growing region.

(Horace Chandler, under observation in July, 1870.)

PLATE E.

HEMIATROPHY OF THE RIGHT SIDE OF THE FACE CONSEQUENT ON MORPHŒA OF THE FIFTH NERVE.

This portrait is copied from one depicted in "Bruns' Atlas," and was probably the first published illustration of the so-called "hemiatrophy of the face." No particulars as to the patient's history are forthcoming, but as the portrait exactly resembles others which have more recently been the subject of detailed observation, we may feel confident that the history was also similar. No doubt the patient in childhood had an attack of fifth nerve morphœa which was followed by arrest of growth of the bones and some shrivelling of the skin and subcutaneous tissues. We have the same vertical furrow of the chin and forehead, which are shown in other portraits, and the same pushing over of the middle line of the chin towards the affected side. Had the patient's tongue been shown it would probably have presented similar appearances to those exhibited in Plate G *bis*. It will be seen that one eye looks smaller than the other and is less prominent, a condition probably caused by comparative absence of orbital fat. (See Dr. Payne's description of this condition in the case illustrated in Plate I.)

PLATE F.

ATROPHY OF ONE CHEEK WITH LOSS OF FAT.

The portrait which is here copied from a photograph published by Mr. Stanley Boyd, is of special interest as illustrating a minor form of facial hemiatrophy. The demonstrable changes, as described by Mr. Boyd, consisted almost solely in absorption of fat, though it may be assumed that some shrinking of skin went with it, as the case is designated "atrophy of one cheek." The patient was somewhat older at the date of her attack than are most of those in whom the more conspicuous forms of atrophy result. The wasting of the cheek had been noticed only about nine months.

The following are Mr. Boyd's published notes :—

"F. H., aged 14, came to my out-patient clinic at the Paddington Green Children's Hospital in February, 1887, complaining that her right cheek was wasting away.

"Two and a half years earlier she had received a box in the right ear, after which she had ear-ache, and a discharge which has occurred intermittently ever since. It is at least doubtful whether this had anything to do with the wasting of the cheek, which was first noticed eighteen months after the blow. The wasting increased very gradually for nine months, but more rapidly, the mother thinks, for the last three. It was preceded by no pain, eruption, or other sign of nerve irritation.

"The patient is the eldest of a family of eight children, among whom no history of inherited disease was discovered; there was no history of any nervous disease upon either the mother's or father's side. The girl was said always to have been healthy, though rather thin and small for her age; with the exception of measles, she had had no illness."

The subcutaneous fat of the right cheek, and particularly the mass which lies beneath the edge of the masseter, has almost entirely, if not entirely, disappeared. I could make out no difference between the sides above the zygomatic arch, and there was little or no difference between the halves of the lips and chin. Sensation was unimpaired, and the muscles upon the right side reacted to as faint a current as did the corresponding muscles on the left; all could be used with equal facility and power. So far as I could judge, the bones were as well developed on the right as on the left side. There was no striking difference in the colour of the cheeks.

Treatment with a stimulant liniment and with the constant current was adopted; but the patient soon ceased to attend.

PLATE F *bis.*

ATROPHY FOLLOWING MORPHŒA AFFECTING THE SECOND DIVISION OF THE FIFTH NERVE.

In this instance it would appear that the middle division of the trigeminus was chiefly or perhaps solely affected. At any rate the first division appears to have escaped. The sinking in of the cheek is considerable, but there is no want of symmetry in the forehead and but little, if any, in the chin. It may be compared with the preceding plate which shows similar conditions and of which a full description from life is given. In this instance we have no history. It is copied from a photograph of which the history has been lost.

PLATE G.

MORPHŒA OF FIFTH NERVE AND HEMI-FACIAL ATROPHY.

Girl's face. The want of symmetry in the face is here very conspicuous. The patient was a girl of 13 who was brought to Mr. Hutchinson's clinic in July, 1902. The affection had begun in early childhood, and was now arrested and in process of restoration. There was a furrow up the middle of the forehead and down the side of nose and middle of chin. The right half of the lower jaw was much smaller than the other, and the chin itself was consequently pushed over to the right. The next plate shows the shrivelled condition of the right half of the tongue.

PLATE G *bis*.

ATROPHY OF RIGHT HALF OF TONGUE CONSEQUENT ON MORPHŒA AFFECTING THE FIFTH NERVE.

This portrait is from the same case as the preceding plate. The right half of the tongue is shrivelled just as it is after section of the hypoglossal nerve. The tongue is pushed over to the affected side, the left half of the organ being perhaps hypertrophic.

See *Polyclinic Journal* for 1902, page 446.

Atrophy of one half of the tongue was observed also in a case which is recorded as Case 22 in *Archives of Surgery*, vol. iii., p. 37. The patient was a young woman, aged 23, under the care of Dr. Crewe, of Worcester. It is also mentioned in the description of Plates G and H.

In connection with this case, which illustrates the most extreme form of hemiatrophy of the tongue, it may be of interest to append the following narrative of perhaps the most severe form of facial atrophy which has ever been observed. It is taken from *Archives of Surgery*, vol. iii., p. 43.

HEMIFACIAL MORPHŒA FOLLOWED BY VERY SEVERE ATROPHY—SHRINKING OF THE EYE—SALIVARY GLANDS AND MUSCLES OF MASTICATION—HEMIATROPHY OF THE TONGUE AND PALATE—MORPHŒA PATCHES IN THE OPPOSITE UPPER EXTREMITIES.

"Dr. Hughlings-Jackson, to whom I have been indebted for several instructive examples of morphœa, was good enough to send to me, for examination, a young woman who was under his care in the Hospital for Epilepsy. Her name was Agnes B., and she was 18 years of age. Her case is very valuable to me in support of my assertion that the so-called hemiatrophy of the face is nothing more than the arrest of growth following an attack of fifth-nerve morphœa which has occurred in early life. The coincidence of morphœa conditions on the limbs was in this instance, as in several others, a conclusive proof as to the real nature of the atrophy. The case is, apart from this, of great value as an example of severe implication of the muscles and glands in the morphœa process. The atrophy of the face had also proceeded to a most remarkable extent.

"It was the left half of the face which was affected. A depressed line ran up the middle of the chin and forehead, being less appreciable, though visible, on the nose. The poor girl was so much disfigured that she was even unwilling to have her face looked at, and would not listen to the suggestion of a photograph. The following are some of the particulars which I noted while she was before me. The eyeball was shrunken and the orbit destitute of fat. I could find no trace of lacrymal gland, nor could any part of the parotid be felt, although the face was very thin. About the condition of the submaxillary salivary gland it was not possible to be certain. The line of the alveolus in the upper jaw showed scarcely any curve, and that of the lower was much less than normal. The teeth were of good form, but crowded and irregular. The left eyebrow was very thin, and the hair on the left half of the scalp was thin and weak. The angle of the lower jaw was lost, the bone slanting down from the articulation to the symphysis. I could not detect either temporal or masseter muscle. The left half of the tongue was shrunken, and the left half of the palate also. On the right half of the upper lip there was a good crop of downy hair, but on the left it was much less abundant. On the back of the right forearm over the upper part of the ulna there was a broad streak of depression, as if from absence of subcutaneous fat. The middle and ring fingers of the same hand were very slender and much shortened, the middle being the shortest. There was a streak of skin over the back of the hand and middle of the fingers which was much thinned, so that the tendons could be easily seen, and a similar condition existed in the corresponding part of the palm. No appreciable defect of sensation in the affected parts could be detected. Amongst the points worthy of especial note in this case are the atrophic shrinking of the eye, and of the lacrymal and salivary glands; also the conclusive proof of the arrest of growth which the disease induces, as shown in the shortness of the middle finger. Lastly, we have the circumstance that while the growth of the hair had been much interfered with, that of the teeth had not."

PLATE H.

HEMIATROPHY OF FACE CONSEQUENT ON MORPHŒA AT THE AGE OF FOURTEEN.

This plate is copied from a photograph kindly lent by Dr. Byrom Bramwell. The particulars of case are given in his well-known Clinical Atlas.

It will be seen that the girl's face is shrunken on the left side and that a shallow furrow passes up the chin and the forehead. This furrow is not exactly in the middle line, being displaced a little towards the affected side in consequence of its shrinkage. The hairs of the eyebrow, and possibly the eyelashes also, are much less well grown on the affected side than on the sound one. Freckles occur on both sides, but are larger and more abundant on the right. The case was no doubt in the stage of reparation.

Dr. Bramwell's patient was a girl of sixteen, in good health. The history given was that the disease had commenced about four years ago by a hard, painless lump in the cheek, just below the angle of the jaw. Gradually the whole cheek was involved in hardness. Subsequently the cheek wasted, and the conditions shown in the portrait resulted. During the four months that the patient remained under Dr. Bramwell's observation and treatment it was thought that some improvement took place; at any rate there was no advance of atrophy.

The following are some of the chief facts which were observed:—

The left cheek, although thin, still felt somewhat indurated; the patient complained of tightness, and the lip was drawn upwards so as to expose the teeth. The lips were wasted, as was also the ala of the nose. The left ear was smaller than the other. The left side of the tongue was markedly atrophied. The two sides of the face were believed to perspire alike and freely. The growth of downy hair on the left side of the face was much less than on the other; the left eyebrow was less marked than the right. There was a bald patch on the side of the head above the ear, and the scalp-hair generally on that side was thin. None of the special senses appeared to be in any degree impaired, and the two pupils were in all respects normal. The free movements of the facial muscles were considerably impaired, but none of these muscles were paralysed.

PLATE I.

HEMIATROPHY OF FACE AFTER MORPHŒA.

This case, like Plate C *bis*, is again of historic interest. The man was seen by Romberg in 1847, who published some details of it, and by Virchow in 1859, and more recently by Eulenberg, Charcot and other observers. He attended at a meeting of the Pathological Society of London in 1880, and an excellent account of his history and condition was given by Dr. Payne in the thirty-second volume of that Society's *Transactions*.

The man was a German by birth. His affection had commenced, he believed, at the age of 8, when a very considerable swelling of the left side of the face occurred. The swelling gradually subsided, and in the course of a few months had left only a yellow brown stain. After this the teeth on that side fell out, but otherwise nothing special was observed inside the mouth. From this time onwards increasing disproportion was observed in the two halves of the face. The left side assumed all the characters of old age, the skin being thin and wrinkled and there being an entire absence of fat, &c. The eye was deeply sunk in its socket.

The appearances described were conspicuously present when thirty-four years from the date of onset the man came under observation in London. Dr. Payne adds the following facts. The pupil of the left eye[1] was under all conditions larger than that of the other, and the hearing in the left ear was defective, as also were faculties of taste and smell. The left half of the tongue was considerably wasted and all the teeth were absent. When extended the tongue was pointed to the left. The hair on the left side of the head was thinner than on the right and there was an almost bald area above the ear. The eyelashes were deficient in the inner parts of the lids. There was no perceptible difference in the sensibility of the skin, nor in the temperature on the two sides, but it was believed that the left side of the face perspired less freely than the right. The left ear was smaller than the right. All the bones of the left half of the face were definitely smaller than the corresponding ones of the right.

Dr. Payne, in his comments on the case, points out that the lesions were apparently distributed by the fifth nerve, and that they differed essentially from those which result from paralysis of the sympathetic.

It is of much interest to note that in the first stage in this case there was considerable swelling of the parts. This has often been recorded of morphœa on other parts, but only rarely when the face was the part affected. Thus we have another link in the association of hemiatrophia facialis with herpetiform morphœa. We may note also the permanent sinking of the eyeball as evidence of absorption of fat. Several of our portraits show some degree of this condition and on some it is mentioned in the notes. (See plate G *bis*.)

[1] The eyes were examined by Mr. Nettleship.



PLATE J.

MORPHŒA AFFECTING EXTENSIVELY THE LEFT LOWER LIMB OF A CHILD.

This plate is copied from a photograph given to Mr. Hutchinson by the late Mr. Sympson, of Lincoln. Very extensive morphœa changes involved almost the whole of the left lower extremity. The leg was shrivelled and hide-bound, and the foot was drawn up by the contraction of the skin. It is, however, to be specially noted that the foot itself was not involved, thus offering a strong contrast with the conditions present in acroteric morphœa. A well-marked streak of induration passed upwards on the inner aspect of the thigh. The boy was otherwise in good health. No accurate information has been obtained as to his subsequent progress, but it is believed that during the next few years the condition of the leg was much improved. The case may be fairly taken as representing a not inconsiderable class in which the lower extremity is involved in herpetiform morphœa.

RADIOGRAPHS

ILLUSTRATING

COLLES' FRACTURE

(Mostly from the Jones-Morgan Collection).

(Without Colour).

PLATE K.—A recent Colles' fracture.

" L.—Colles' fracture with splitting of the Radius (side view).

" M.—Colles' fracture united without reduction.

" N.—Colles' fracture with slight displacement.

" O.—Colles' fracture in third week.

" P.—The same (side view).

" Q.—Colles' fracture in second week.

" R.—Colles' fracture (recent).

" S.—Colles' fracture after much treatment, but without reduction.

RADIOGRAPHS ILLUSTRATING COLLES' FRACTURE.

General Statements.

The designation Colles' Fracture is applicable to any fracture occurring in the expanded carpal extremity of the radius. For the most part such fractures are caused by falls on the palm of the hand, and although varying greatly in the amount of displacement produced they are remarkably alike in their general type. In a great many there is little or no displacement, the fracture being merely a crack in the bone which can be proved only by use of the Rays. In many others, however, there is the well-known displacement of the carpal fragment backwards with a tendency towards the radial border. In these there is never any actual riding of one fragment on the other, for the broken surfaces always remain in apposition to a greater or less extent. What happens is, that the carpal fragment is driven upwards and backwards in such a manner that its cancellous tissue is crushed by the lower end of the shaft. Impaction, with a certain amount of shortening, results; the end of the ulna is left projecting, and the wrist is thickened and assumes the curve which has been so aptly compared to that of the silver table-fork. As complications there may be vertical fissures in the lower fragment involving, of course, the joint, or the styloid process of the ulna may be broken off at its base by the traction of the triangular ligament. Now and then there may be one or more fissures in the lower part of the shaft.[1] None of these complications are of any moment, nor do they, with the rarest exceptions, necessitate any modification of treatment.

[1] See Plate I.

The advance in our knowledge of these matters which was made by Abraham Colles, when in 1814 he described the fracture which has since borne his name, was chiefly this, that in many cases which were diagnosed as sprained wrists the bone was really broken. He was led to this conclusion by observing that he could by moderate traction produce movement at the site of injury, for he had dissected few, if any, specimens. His observations drew professional attention to the subject and were soon confirmed by others. It was at once assumed that if these injuries were really fractures, they ought to be treated as such, that reduction ought to be effected and that splints ought to be used to keep the fragments in position. Numerous were the contrivances which were resorted to with these objects in view, and when it was found that, in spite of the best, deformity usually resulted, much anatomical industry was expended in the endeavour to discover what special muscle was most at fault. Of late years there has arisen a suspicion that this zeal was misdirected and that in truth the muscles are not materially concerned. Yet more advanced sceptics have even hinted that, after all, Colles' discovery has been a misfortune for many of the subjects of Colles' fracture, since it has led to measures of treatment not only useless, but actually injurious. Some of these believe that if it were still the practice to treat a large majority of Colles' fractures as if they were only sprained wrists, placing the arm on a cushion without either pressure or traction, and encouraging use at the end of a week, a far better average of results would be obtained than is now the case.

Although the Roentgen Rays in their application to the examination of fractures can scarcely as yet be credited with any definite improvements in practice, they have undoubtedly done much towards giving exactitude to our conceptions. It was not perhaps to be expected that they could do more, for, after all, the more important facts had already been well established. From this exactitude, and from the positive demonstration, now become possible, of what was formerly to some extent only conjectured, we may, however, hope in the future to reap practical benefits. It is possible that the form of fracture which we now purpose to illustrate may offer one of the most fruitful fields in reference to this method of investigation, and that a very important simplification in treatment may be the result. Colles' fracture is one of those which most frequently come under the care of the family practitioner, and which perhaps more often than any other entails a certain amount of discredit. Whatever can be demonstrated with certainty in respect to it is of great importance to the whole profession.

The Radiographs illustrating Colles' fracture, which we now publish, have been selected from a great number which have been placed at our disposal. We have chosen those which showed the conditions most definitely, and our Plates be regarded as fair representations of what is usual in this accident. Our object in reproducing these is to illustrate the exact conditions which the surgeon has to contend against in his treatment of this fracture. They have rather it may perhaps be said the result of showing that there is not so much for him to do as is generally supposed. All the plates show displacement of the usual and well-known kind, and inasmuch as it is seen to be the same in cases of old standing as in recent ones, the suggestion follows that, as a rule, no real reduction is effected by the surgeon's manipulations and his subsequent use of splints. Unfortunately we have no details as to the treatment which had been pursued in several of the cases. In Plate K, however, a most instructive radiograph is given, showing the results after very persevering attempts at reduction, and a long period of rest. In this instance the displacement of the bones remained much what it is seen to be in most of the other cases now illustrated, whilst in consequence of the long period of rest which had been enforced the wrist was much crippled by stiffening.

Those who now teach that in a large majority of Colles' fractures it is neither advisable to make any attempts at reduction, nor to use any kind of splint, base their recommendations upon the following facts.

Reasons for Abstaining in the Majority of Cases from Attempts at Reduction.

(1) That the displacement which is present results directly from the direction of force at the time of the accident, and not in any material degree from the action of the muscles.

(2) That the bone at the site of fracture being much expanded, the exposed surfaces are large and do not easily move one upon the other.

(3) That, in addition to the immobility which the apposition of large surfaces necessarily implies, there is often very definite fixation by impaction, the end of the shaft being driven into the carpal fragment.

(4) That the carpal fragment being very short and susceptible of movement only by dragging on the attached ligaments, etc., or by direct pressure, it is usually very difficult if not impossible to move it.

(5) That it is quite possible by traction to effect an apparent removal of deformity without having really altered the relative positions of the broken fragments in the least. Thus the hand may be carried over to the ulnar side and thus the projection of the ulna concealed.

(6) That it is but seldom that either mobility or crepitus at the site of fracture can be detected.

(7) That the locking of the fragments together is often such that the patient can from the first lift the limb and allow of pronation and supination to a certain extent without any material pain.

(8) That the locking of the fragments is usually such that it prevents any risk of sub-

sequent increase of displacement, and thus renders the use of apparatus for immobilisation wholly unnecessary.

Thus it will be seen that in the main the contention is that for the most part reduction is not practicable, and immobilisation quite unnecessary.

It is fully admitted that there are exceptional cases, attended with unusual deformity to which the above considerations do not apply, and it is recommended in all cases in which the displacement is considerable that it should be ascertained by traction in a straight direction whether there is, or is not, movement at the site of fracture, and whether any better position can be obtained.

Dr. Carl Beck on Colles' Fracture.

We may suitably take a Lecture[1] recently given in New York by Dr. Carl Beck, as an up-to-date exposition of the usual and more orthodox methods of treatment. Dr. Beck is a thorough believer in the possibility of reduction, and in the necessity for immobilisation, and he enforces his creed and practice by appeals to the Roentgen rays. He makes, however, some rather remarkable admissions.

First amongst these we have the confession that he has found it *impossible to feel sure, that reposition has been effected without the aid of the radioscope.* He insists that this aid to diagnosis ought to be had recourse to in every case, and not only before reduction but after the plaster of Paris case has been put on. If at the latter stage the adaptation is found to be imperfect, the limb is to be again uncovered and another attempt made. How many times this is to be repeated we are not told. Every practitioner is to be provided with a Ray apparatus, and to make himself skilled in its employment. Thus we read :

"In order to accomplish exact reposition, the degree and the direction of the displacement, as it is shown by the Roentgen rays, must be first considered. It is true that an experienced surgeon will often *guess* right, but he will never *know*, except by his infallible adjunct, the Roentgen rays. The only safe method is the self-control by the Roentgen rays. It may appear to be unjust to demand of the struggling practitioner that he should supply himself with an expensive Roentgen apparatus, but after all there will be no other choice. The public is cruel, and the patient's interest concentrates itself almost entirely in his own welfare. These principles apply to most other fractures situated near a joint. Contusion and distortion are sometimes taken for fissure and often for non-displaced fracture and *vice versâ*, as the symptoms—local pain and enlargement of the wrist—are common to all. *Crepitus and false motion are absent*, and this is not surprising."

A few pages further we have the admission to which allusion has been just made :—

"I confess freely that I have often thought I had reduced a displaced fragment thoroughly because palpation seemed to give thorough satisfaction. But I was sometimes not a little surprised that the Roentgen plate showed me most impolitely how ill I had succeeded in my alleged reposition. In a former publication on the subject I have advised as a method of self-education, the drawing of an anatomical sketch of one's silent diagnosis and then comparing it with the skiagraph. Thus we learn on one hand that we cannot always depend even on a highly cultivated palpatory talent, and on the other hand we are taught to improve the power of judgment by comparing our sketch with the lifelike picture as it is given to us by the Roentgen rays. Thus we perfect our clinical experience, for which the Roentgen rays should by no means simply be substituted."

We may join most freely with Dr. Beck in admitting that in the ordinary forms of this fracture, with a wrist much swollen—as it is after recent injury—it is often, indeed usually, quite impossible to feel sure that re-apposition

[1] The title of the lecture is "The Modern Treatment of Fractures of the Lower End of the Radius, as Indicated by the Roentgen Rays." *

Dr. Beck introduces his statement as follows: "The old dictum, *Qui bene diagnoscit, bene medebitur*, applies pre-eminently to the treatment of the fracture of the carpal end of the radius, generally known as Colles's fracture. In fact the laws that govern the treatment of this much disputed fracture, and last but not least, the final result, are entirely determined by a correct diagnosis. The principles of treatment are then reduced to a few points of simple common sense."

"Such complete and correct diagnosis could not as a rule be made before Roentgen's great discovery. It can safely be maintained that in most cases skiagraphy has revealed conditions that were not expected and required the original diagnosis to be more or less modified.

"The questions most frequently asked of a surgeon, 'How do you treat Colles's fracture?' 'Do you use long or short splints?' 'Do you prefer the plaster of Paris dressing or a splint?' 'Are you fond of Dumreicher's, Roser's, Schede's, Braatz's Gordon's, Koelliker's, Moore's, Carr's, Bond's, or Middlederpf's bilateral, or of the old pistol splint of Nelaton?' 'Are you in favour of immobilisation or of early motion?' &c., show that the essential points are generally overlooked, fracture of the lower end of the radius being regarded by many as of a constant type, uniformly characterised by the fracture of the bone 10-30 mm. above the articulation, and followed by a silver-fork-shaped deformity of the wrist. This point of view is inadequate and erroneous."

* Read at the stated meeting of the New York Academy of Medicine April 3, 1902.

of the fragments has been accomplished. This statement applies to most of the cases illustrated in our Plates and it may be supplemented by the expression of doubt as to whether such re-apposition is in itself possible. There is impaction and the broad surfaces of the two fragments are locked together, the cancellous tissue of the carpal fragment is more or less crushed and thus facilities are afforded for its slipping back after partia reduction. This lower fragment is very short and but little accessible to manipulation. Extension can be effected only through the medium of the soft parts. The latter readily allow of restoration of the straight axis and of carrying the hand over to the ulnar side without any movement whatever at the site of fracture. Not improbably the result recorded in the cases referred to by Dr. Beck is the usual one. If it can occur in the practised hands of a hospital surgeon of Dr. Beck's skill, how much more in those of younger and less experienced men. After all, are the revelations of the radiograph so entirely free from risk of misinterpretation as is here presupposed? Our Plates have been executed from very excellent radiographs and are exceptionally clear, yet the reader will admit that excepting when the displacement is unusually great they do not afford much guidance as to treatment. Those showing only the palmar aspect are of very little value. If the displacement were great the rays would undoubtedly show it, but in those cases the contour of the limb and finger examination would also sufficiently reveal it. It may be doubted therefore whether for practical purposes in this class of cases the Rays do really give much help: that their revelations are of great interest of course no one can doubt. Dr. Beck writes as if he had frequently determined by their aid the exact position of the fragments before reduction and subsequently demonstrated their perfect coaptation. He does not, however, give any illustrations of this.

It is obvious that the most precise determination of the lines of fracture by the Rays does not necessarily lead to improved treatment. It may be that the surgeon is still left to his old expedients: extension till all deformity is apparently removed and the use of the plaster case or the pistol splint with pressure by pads where thought necessary. Nor are we offered in this lecture any new light on these matters. Dr. Beck prefers the plaster of Paris case in the first instance and as has been said he always takes another radiograph after its adaptation. Even in cases in which the evidence of the second is satisfactory the plaster case is to be removed after a few days and substituted by splints. Instructions are given as to the application of pressure at various points.

Now inasmuch as these measures are precisely those which were employed before the introduction of the X-rays and probably, with almost as much painstaking then as now, it is of interest to note that the general results do not appear to have been very satisfactory. Dr. Beck speaks repeatedly of the "gibbous wrist," as if it were common, and counts it among "the inevitable inventory of surgical clinics." So that perhaps, after all, the results would have been much the same if the cases had been left without attempts at reduction and without immobilisation. Dr. Beck admits that in cases in which there is no displacement, there is no need for replacement, but he still insists on immobilisation. That he has been accustomed to see a good deal of stiffness remain may be inferred from his speaking as if in certain complicated cases in elderly persons ankylosis of the wrist is to be expected, and is even to be desired.[1]

Those who oppose the employment of splints do not therefore dissuade from attempts at replacement in cases where malposition of the fragments is evident. They believe that if the lower fragment can be moved and brought more nearly end to end with the upper one the largeness of the surfaces in apposition will usually suffice to prevent renewal of the displacement. If any tendency to such renewal is manifested an immobilising apparatus—splint or plaster case—should be resorted to; otherwise it is not needed and is usually injurious. They oppose as bad in principle,

[1] "Immobilisation is best kept up with a moss bracelet until ankylosis of the wrist takes place" (p. 29).

all attempts to exercise permanent traction on the fragments, or to press them into position by pads, &c. Such expedients are, they think, not only useless but liable to injure the tendons and soft parts which are made to bear the pressure.

A wrist more or less "gibbous" they regard as almost inevitable in all cases of definite displacement, but in the large majority they hold that it is of no consequence whatever as regards the use of the limb, and scarcely indeed ranks as a disfigurement. On the other hand the restoration to use is rapid and it is without the stiffness which is such a common consequence of painstaking treatment.

It is matter of note that Dr. Beck appears to attach more importance to certain minor complications than English surgeons do. Two of our plates show detachment of the styloid process of the ulna, the result doubtless of traction on the triangular ligament.

Helferich's Opinions.

We have taken Dr. Beck's Lecture for comment, not in any critical spirit, but simply because it contains the opinions of a surgeon of great experience and well versed in the use of the X-rays. If we now turn to the

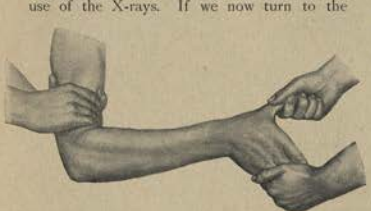

FIG. 1.—"Method of reducing impaction in a case of Colles' fracture." (Helferich.)

chapter on Colles' fracture in Helferich's treatises on Fractures, &c.,[1] we shall find opinions of a very similar character. They are, in fact, the general creed of the day, Helferich tells us (see page 99) "It should be noted that the ordinary symptoms of a fracture are not always pronounced; for instance, abnormal mobility may be absent owing to impaction, and in any case is difficult and unnecessary to produce. The same applies to well-marked crepitus." It might almost be supposed that if it be unnecessary to produce abnormal movement at the site of fracture all attempts at reduction are precluded. Yet a few lines lower down we read "the prognosis depends chiefly upon the treatment" and that "reposition must be effected by direct pressure and traction on the hand whilst the latter is forcibly bent." It is added that the reposition is best done under an anæsthetic and that two assistants are desirable. Two illustrations of the method of reduction are given, in both of which the hand is carried strongly towards the ulnar side, and the direct traction is made chiefly by the thumb. Our author states clearly that "there is, as a rule, no tendency to new displacement," yet he insists on the use of an immobilising apparatus, plaster of Paris or splint, with the hand carried to the ulnar side.

FIG. 2.—"A slightly different method of making traction from that shown in the previous figure." (Helferich.)

FIG. 3.—"Colles' fracture treated without splints by bands of strapping and suspension."

Helferich mentions, however, as of special value, a method which is illustrated in the appended woodcut, and which abandons splints altogether. It is thus described: "after com-

[1] On Fractures and Dislocations, "New Sydenham Society Library," vol. 167.

plete reduction of the deformity, and full adduction of the wrist, a band of strapping 10 cm. wide is applied around the lower end

FIG. 4.—"Position of the hand on a palmar splint bent in two directions, as recommended by Schede. The splint is shown along side, and the direction of the turns of bandage indicated by arrows." (Helferich.)

of the forearm, whilst a second one surrounding the forearm a little higher up leaves a gap through which suspension can be arranged.' It is difficult to see what advantage this method possesses over a simple cushion and sling, which would probably be much more comfortable, whilst it is clear that it can be safe only in the supposition that the bones are so locked together that there is no tendency to renewal of displacement. This is precisely what the advocates of disuse of splints contend for. As regards effecting "complete reduction of the deformity" we have seen that Beck, who used the X-rays, fully acknowledges that

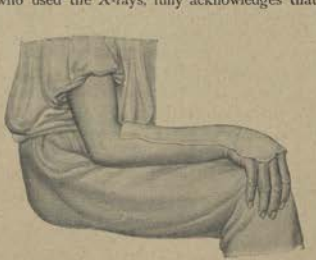

FIG. 5.—"Application of plaster of Paris splint after reduction of the displacement. The patient's thigh serves as a support for the forearm, whilst the hand is bent over the knee." (Helferich.)

excepting by their aid it is impossible ever to feel sure that replacement has really been effected. It is easy by altered position of the hand to conceal deformity, but in most cases exceedingly difficult to alter the relative positions of the bones. Helferich figures Roser's apparatus, but remarks respecting it that it seems unnecessarily cumbrous and suitable only for exceptional cases. He

FIG. 6.—"Roser's apparatus for treating Colles' fracture in full supination." (Helferich.)

further remarks that it must never be forgotten that Colles' fracture requires frequent change of apparatus, early massage and active motion." The advocates of no splints say that no massage is ever needed, and that passive motion may be encouraged almost from the first, and they further agree most entirely with the remark, "*It is certainly better that such a case should recover with slight displacement but with perfect mobility of the fingers and wrist than without displacement but with greatly impaired mobility.*" At the same time they scarcely admit that the alternative is exactly that which is suggested in this sentence, since they believe that the choice is usually between permanent deformity and good motion, and permanent deformity with stiffening in addition.

Helferich well says, "This form of fracture is very common and of the greatest practical importance, *its symptoms are remarkably constant.*" When he states that the cancellous tissue of the lower end of the radius gives way rather than the strong anterior ligament of the joint "he probably makes a needless suggestion, but he hastens to correct it by adding, "At the same time the violent pressure transmitted through the upper carpal row has probably a good deal to do with the fracture." Further on he writes, "The displacement to the radial side is due far more to the line of action of the force which produces the fracture than to any muscular con-

traction." It may be suggested as probable that neither ligaments nor muscles have any share either in producing the fracture or influencing the displacement of the carpal fragment. The direction and force of impact are the all-important agencies in the matter.

His statement that the symptoms are commonly obvious enough, but that a very careful examination should be made in any doubtful case, may be met by suggesting that when the symptoms are not obvious there is no object whatever in "careful examination" for the displacement is not important in degree, and if not interfered with will never become so, all such cases will do perfectly well if let alone, and the less they are handled the better. This remark applies with especial cogency to the suggestion that when other symptoms are absent "there will probably, however, be tenderness exactly over the line of fracture," and that "digital examination to determine this will be of great assistance."

Opinions of Colles and other Authorities.

The reader who wishes to examine for himself the voluminous literature of Colles' fracture will find that distinguished surgeon's original papers reprinted in full in Vol. xcii. of the New Sydenham Society's Library. With it are also given valuable comments by the Editor, Dr. Robert McDonnell, and liberal extracts from the papers of Dr. R. W. Smith, Voillemier, Rhea Barton, Bond, Gordon, and others. The remarkable discrepancies which these authors display, not only as to opinion but as to measures of treatment, may amuse the surgical cynic, but can scarcely do less than excite feelings of melancholy in those who reflect how seriously the comfort and usefulness of many thousands of forearms have been at stake. Mr. Cline is quoted as recommending (before the days of Colles) that no splint should come below the wrist, and that the hand should be allowed to hang towards the ulnar side, and thus by its own weight keep the bones in place. Mr. Colles himself taught that reduction by direct traction was easy, and that by the use of straight splints the fragments could be kept in position with the most satisfactory results. Dr. Bond, some years later, writes, "This mode of dressing, by long, straight splints, not only increases the danger that the fracture will result in rigidity, but that when it does occur the hand will be left unsightly, inconvenient and useless." Although he does not approve of Mr. Cline's recommendation of short splints as being "too indeterminate and as endangering an artificial joint," he yet adds, "Nevertheless I am persuaded that with Mr. Cline's method of treatment . . . there would be fewer cases terminating in deformity and loss of use of the hand, than when the arm and hand are tightly swathed in long, straight splints." Concerning fractures in elderly people prone to rheumatism he writes: "In such cases, if the usual authorised mode of treatment be adopted, the result will be a most awkward, unsightly, useless member." We have already quoted Dr. Beck's opinion to the effect that anchylosis at the wrist in such cases is to be expected.

Mr. Colles records that in his experience reduction by straight extension was always easy of accomplishment, but we now have the testimony of Dr. Beck, to the effect that it is not possible, without the aid of the X-rays, to tell whether reposition of the bones has been brought about or not. Mr. Colles is clearly of opinion that in the first instance the fragments are immovably locked together, but that after they have been separated by the surgeon's extension, they can be made easily to move on each other. He writes: "For this purpose, (*i.e.*, the detection of fracture,) the surgeon attempts to move the broken pieces of the bone in opposite directions; but although the patient is, by this examination, subjected to considerable pain, yet neither crepitus, nor any yielding of the bone at the seat of fracture, nor any other positive evidence of the existence of such an injury is thereby obtained." As regards reduction he states: "If the surgeon lock his hand in that of the patient and make extension even with moderate force, he restores the limb to its natural form, but the distortion of the limb instantly returns on the extension being removed. Should the facility with

which a moderate extension restores the limb to its form induce the practitioner to treat this as a case of sprain, he will find after a lapse of time sufficient for the removal of similar swellings, the deformity undiminished."

Inasmuch as these expressions clearly imply that restoration of form may be accomplished without eliciting any conclusive indications of fracture, and may leave it open to the surgeon to believe that he is dealing only with a sprain, the suspicion is obvious that after all movement of the bones at the site of fracture is often not affected. This, however, was not Colles' view, for he asserts that as soon as liberation of the fragments has been accomplished the signs of fracture become obvious. "As soon as this" (restoration of form) "is effected let him move the patient's hand backward and forward and he will, at every such attempt, be sensible of a yielding at the fractured ends of the bone, and this to such a degree as must remove all doubt from his mind." No mention is made of crepitus.

Much waste of labour has occurred from the want of clear comprehension by all concerned, as to what we are to mean by "impaction." R. W. Smith contended that these fractures were not impacted, and Gordon went so far as to write, "Colles' fracture is not, nor can it be, an impacted fracture; its mechanism declares impaction to be a mere phantom of the imagination." Such an expression is possible only under some misconception as to what the word "impaction" should be held to mean. No one can look at the radiographs which we now publish and doubt for a moment that the extremities of the broken bone have been so crushed together that the outer shell of the one fragment enters the cancellous tissue of the other, and thus effects a mutual fixation. It is to this condition, one which permits of movement of the broken bone in one piece, prevents further displacement, and defeats the surgeon in his attempts to elicit crepitus, that the term "impaction" is applicable. We are not to suppose that it implies penetration of the one fragment by the whole thickness of the other. In such a sensé it may be admitted that the carpal end of the radius presents conditions which render impaction impossible. The lower end of the broken shaft is far too large, and there is besides such displacement backwards of the lower fragment as would make it impossible for the latter to enter it. What has been called "reciprocal impaction" is, however, quite possible, and probably does often occur. Under this term it is implied that the dorsal edge of the end of the shaft penetrates the cancellous tissue of the carpal portion and the palmar edge of the latter the cancellous tissue of the shaft. Nor was it left for the X-rays to give the first confutation of the assertions of Smith and Gordon as to the non-existence of impaction. Professor Bennett in Dublin, Mr. Callender at St. Bartholomew's, and many others had supplied conclusive evidence on that point. We may now take it as established beyond dispute that in most cases of fracture of the carpal end of the radius with displacement there are conditions of impaction which prevent movement of the fragments until they have been liberated by the surgeon's traction. It remains an open question whether, after reduction by traction the fragments again become locked together in the rectified position, or whether there is a tendency for the displacement to be re-assumed. Colles held that the latter was the rule, but as has been already seen Helferich and some others deny it. It is a most important question in reference to treatment, and it is one upon which we may hope to soon obtain, by use of the Rays, conclusive evidence.

Colles' treatment was by traction in the straight line, the application of a front and back splint with a pad placed transversely across the "anterior surface of the limb" just above the fracture, in such a position as to press back the lower end of the shaft. He averred that "the cases treated on this plan have all recovered without the smallest defect or deformity of the limb in the ordinary time for the cure of fractures." This is a record which certainly none of the advocates of more modern methods can surpass. The perusal of recent writings on the subject certainly gives the impression that gibbous wrists are still very

common, and that great stiffening and disablement is far from infrequent.

Summary as to Treatment.

Although it would be going beyond the scope of the present work to attempt to lay down rules for treatment, yet, having regard to the very conflicting nature of the quotations which have been given, some of our readers may possibly be thankful for a little guidance. It may thus, we think, be assumed

That in cases in which the displacement is slight it is quite safe, after duly warning the patient that some deformity will necessarily result, to make no attempts at reduction, to dispense with splints, and using only a cushion and sling, to allow of passive movements from the end of the first week.

That in elderly persons it is especially advisable to avoid splints.

That in cases in which the displacement and deformity are considerable, reduction by straight traction should be attempted.

That if reduction by traction has been accomplished, it is desirable to apply a pad and straight splints after the manner recommended by Colles (see page 132).

That, *pace* Dr. Beck, the aid of the X-rays, although of great interest and value, is by no means essential to good practice; since, if the displacement is so little as to escape recognition by the fingers, there is no object in making further efforts to reduce it.

One fact is considered, by those who disuse all splints and make no efforts at reduction, to be established beyond controversy. It is that no sort of disability results from their negative practice. They assert strongly that the injured hand is fit for use again in a much shorter time than if splints have been employed; that little or no subsequent treatment by massage or other expedients is usually required to restore free motion, and that in ultimate usefulness the hand is just as good as its fellow. A certain amount of unavoidable deformity is, they assert, the only drawback to their practice. All that is needful is to prepare the patient's mind for this, and then but little disappointment will result.

Further Investigation asked for.

No one can have read what we have here written and examined carefully the appended Plates without experiencing an almost impatient desire to see these questions set finally at rest by a more systematic employment of the X-rays. What more easy than by radiographs taken before attempts at reduction, and others after them, to determine whether any real alteration in the relative position of the fragments is in the majority of cases effected by manipulation? In cases in which the deformity is unusually great it is very probable that some restoration is accomplished. Having ascertained that this had been effected it would next be of great interest to determine whether when extension is relaxed there is any tendency to reproduction of displacement. Most of our large hospitals now possess extensive collections of radiographs of Colles' fracture, but few or none have been collected with the definite object of determining these all-important questions. It would make a most interesting and practically useful addition to the next Annual Museum of the British Medical Association if those interested in this subject would bring their radiographs with especial reference to this point. The plan of this Atlas will permit of our returning to the topic and giving in a future fasciculus any illustrations of importance which may be offered to us.

PLATE K.

A RECENT COLLES' FRACTURE.

In this instance the radiograph was taken a few hours after the accident. The patient was a woman, aged 66, who had fallen on the palm of her hand. The deformity was the usual one, the ulna projecting and there being a hard prominence in the wrist. The radiograph was taken with the palm down and shows the carpal fragment displaced backwards. From the top of the styloid process of the radius this fragment measures three-quarters of an inch in length. The extremity of the shaft is apparently impacted in the carpal fragment. The styloid process of the ulna is not broken, but the end of the bone projects owing to the shortening which has occurred in the radius. It will be seen that the axis of the forearm is not much altered. A side view shows considerable displacement of the carpal fragment backwards. This plate exhibits well the ordinary conditions of Colles' fracture in cases in which the displacement is not unusually great. (See also plates N, Q, and S.)

(From the Jones-Morgan Collection.)

PLATE L.

COLLES' FRACTURE WITH VERTICAL SPLITTING OF THE RADIUS.

This plate illustrates the position of the bones in a united Colles' fracture of eight weeks' standing. The patient was a man, aged 35, who had received his injury in a fall of thirty feet from scaffolding. The fracture is in the usual place and almost transverse, but is attended with the unusual feature of a vertical split in the carpal end of the shaft. There is deep impaction. The fracture was of the right limb, and the radiograph was taken with the internal surface down.

(From the Jones-Morgan Collection.)

PLATE M.

COLLES' FRACTURE AT THE EIGHTH WEEK.

This radiograph, taken in the eighth week, exhibits the palmar aspect of the bones, and shows the carpal end of the shaft displaced forwards and deeply impacted in the lower or carpal fragment. The styloid process of the ulna has been broken off, a complication which is not unusual owing to the dragging force, at the time of the accident, exerted through the radio-ulnar fibro-cartilage. In this case the displacement is the same in character, but greater in degree than in Plate K; and, again, we may note that the axis of the limb is not materially altered, nor would it appear that the ulna projected much. No particulars are forthcoming as to the treatment, or as to the condition of the bones when examined soon after the accident. It may be presumed that the usual splint-treatment had been adopted, and that no real reduction of the fracture had ever been accomplished. Probably the deep impaction shown in the plate is exactly what was present immediately after the fracture.

This plate may be instructively compared with Plate S in which case the treatment is recorded.

(From the Jones-Morgan Collection.)

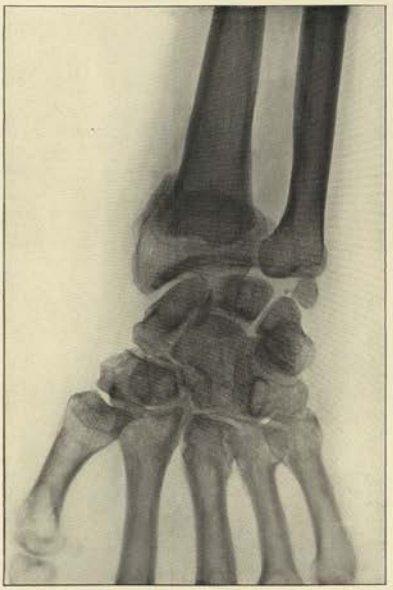

PLATE N.

COLLES' FRACTURE WITH IMPACTION AND VERY SLIGHT DISPLACEMENT.

In this plate we have represented one of the conditions of but slight displacement in a Colles' fracture. The impaction is shallow and, as proved by the position maintained by the ulna, there has been scarcely any shortening of the forearm. Yet the styloid process of the ulna has been snapped through, although without displacement; and on tracing the line of the radius down to its styloid process, it will be seen that there is definite though slight impaction. A side view which was taken at the same time confirmed this.

The radiograph was taken six days after the accident, the patient being a woman, aged 49, who had fallen on her hand. It will be obvious that in cases such as this, there could be no useful object served by attempts at reduction or by the use of splints.

(From the Jones-Morgan Collection.)

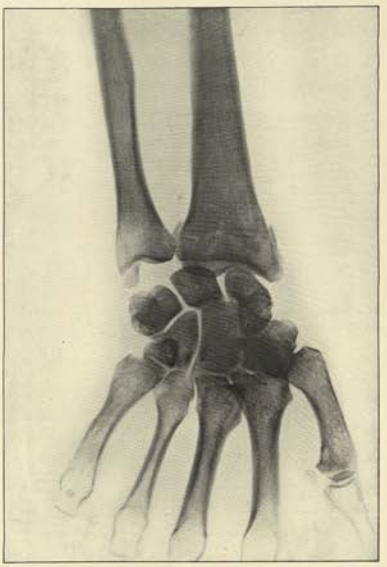

PLATE O.

COLLES' FRACTURE IN THIRD WEEK.

This Plate exhibits the palmar aspect of a Colles' fracture with the usual displacement. The impaction is deep, the carpal fragment being unusually large. The next plate, which is a side view of the same bones, shows the displacement yet more clearly. The radiograph was taken seventeen days after the accident, the patient being a man, aged 24. We have no mention as to what efforts at reduction had been made in the first instance, but clearly they had not been effectual.

(From the Jones-Morgan Collection.)

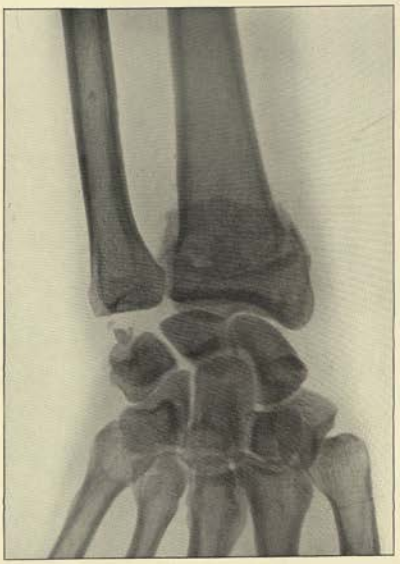

PLATE P.

SIDE VIEW FROM PRECEDING CASE.

This Plate represents the condition of a fracture in a man, aged 24, who had fallen on the left hand seventeen days previously. Another radiograph shows the position of the bones as seen with the external surface down. The displacement is, as usual, with impaction of the shaft into the lower fragment, and displacement of the lower edge of the latter towards the palm. The palmar edge of the lower end of the shaft is seen, in side view, to present a sharp border; this would no doubt have become rounded off as processes of repair advanced. It is to be noted that although probably the usual measures of treatment had been adopted no real reduction had been effected, the displacement being exactly that seen in other cases.

(*From the Jones-Morgan Collection.*)

PLATE Q.

COLLES' FRACTURE IN THE SECOND WEEK.

Colles' fracture with the usual conditions. This portrait, taken with the palm down, (left hand), shows the position of the bones eleven days after the fracture. The patient was a woman, aged 49, who had fallen on her palm. There is considerable displacement of the carpal fragment backwards with deep impaction and some shortening. The hand is carried somewhat towards the radial side, and the styloid process of the ulna projects strongly. A side view which was taken showed the displacement yet more definitely.

(From the Jones-Morgan Collection.)

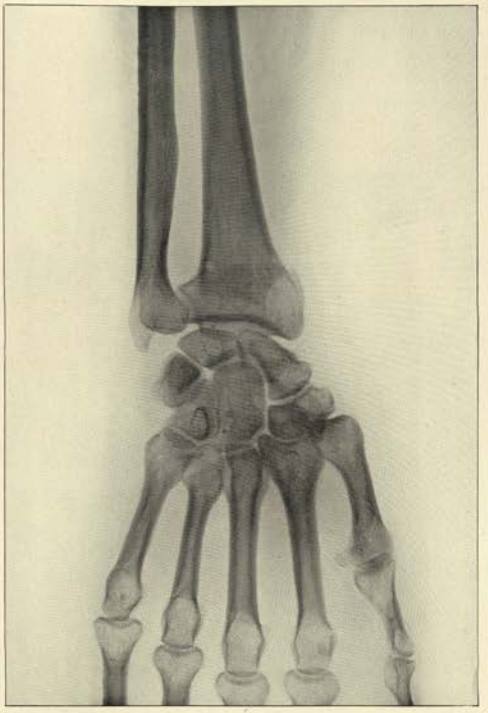

PLATE R.

RECENT COLLES' FRACTURE.

This Plate shows well the position of the fragments in an ordinary form of Colles' fracture. The fracture is transverse and has crossed the carpal end of the bone about half an inch above the articular surface. It has been displaced backwards and towards the ulnar side, causing great projection of the ulna, very definite shortening of the radius, and a projection of the lower and outer part of the carpal end of the shaft towards the radial border. The axis of the limb would not apparently have been much altered, excepting that there must have been very definite projection of the ulna. The accident had occurred two days before the radiograph was taken.

(From the Jones-Morgan Collection.)

PLATE S.

COLLES' FRACTURE AFTER PAINSTAKING TREATMENT.

This portrait illustrates the position of the bones in an ordinary case of Colles' fracture after very careful and systematic treatment. Thirteen weeks had elapsed since the woman had fallen on the palm of her hand and sustained the injury. She was admitted at one of our largest London hospitals soon after the accident. The fracture was (as was then believed) reduced and the limb was placed, *secundum artem*, in a plaster of Paris case. All was supposed to be going on well and the case was kept on for five weeks and two days. When it was taken off there was found to be considerable stiffness, and massage was ordered. The hand was carried in a sling during the next week, at the end of which time the patient was advised to try to use it. At the expiration of another week, the swelling having disappeared, there was observed to be very considerable deformity. Chloroform was now given and an attempt made to effect better reposition. The limb was again put into plaster for a few days, and finally, for three weeks, wooden splints were applied. The radiograph here published shows the condition at the end of this period. It will be seen that there is still an impacted fracture, with displacement of the carpal fragment to the radial border. The impaction appears to shorten the radius to the extent of a quarter of an inch. The carpal fragment, measured from the tip of the styloid process of the radius is an inch in length.

No case could better illustrate the rule for which Dr. Beck contends, that the X-rays are necessary, after the plaster of Paris case has been applied, in order to ascertain whether the fragments are really in apposition. Opinions may perhaps differ as to whether after the first attempt at reduction the bones had again slipped, or whether they had never really been in any degree altered in position. There can, however, be little doubt that they remained permanently exactly as they were after the plaster case had set. It is then perfectly clear that the surgeon may be mistaken as to whether he has or has not effectually readjusted the bones and that nothing short of the employment of the Rays can give conclusive evidence on this point. At the end of thirteen weeks of the well-skilled treatment which this patient had had the usual deformity remained conspicuous and in addition the wrist and fingers were much stiffened.

AN

ATLAS OF ILLUSTRATIONS

OF

CLINICAL MEDICINE, SURGERY

AND

PATHOLOGY

(CHIEFLY FROM ORIGINAL SOURCES).

FASCICULUS XX., OR XII. OF NEW SERIES.

MISCELLANEOUS.

PLATES A to K.

RADIOGRAPHS ILLUSTRATING

FRACTURES AND DISLOCATIONS.

PLATES L to Z.

LONDON:
THE NEW SYDENHAM SOCIETY.
1904.

ILLUSTRATIONS OF
MISCELLANEOUS SUBJECTS.

PLATE A.—Sprengel's Shoulder.
" B.—Paralysis of the Serratus Magnus.
" B 2.—Paralysis of the Serratus Magnus in Woman.
" C.—Group of Sporadic Cretins.
" D.—Family Albinism.
" E.—Bazin's Malady.
" F.—Accessory or Supplementary Thyroids.
" G.—Case of Leprosy in Gibraltar.
" H.—Syphilis Maligna.
" H 2.—Syphilis Maligna.
" H 3.—Syphilis Maligna in Indian.
" H 4.—Syphilis Maligna, frambœsiform, Cingalese.
" H 5.—Syphilis Maligna.
" I.—Chancre on hand of Midwife.
" J.—Serpiginous Lupoid Syphilis.
" K.—Corymbiform Syphilitic Eruption.

RADIOGRAPHS OF FRACTURES, &c.

PLATE L.—Detachment of the Upper Epiphysis of Humerus.
" M.—Detachment of the Upper Epiphysis of Humerus.
" N.—Fracture of Greater Tuberosity of Humerus.
" O.—Vertical Fracture of Carpal end of Radius.
" P.—Fracture of Radius and Ulna.
" Q.—Fracture of Shaft of Radius.
" R.—Commuted Fracture of Radius.
" S.—Fracture of Radius united with overlapping.
" S 2.—Fracture of Radius united with overlapping.
" T.—Fracture of Shaft of Ulna.
" U.—Fracture of Olecranon.
" V.—Dislocation of Radius with Fracture of Ulna.
" W.—United Fracture of both Bones of Fore-arm.
" X.—Multiple Fractures of Bones of upper extremity.
" Y.—Dislocation backwards and outwards at Elbow.
" Y 2.—Dislocation backwards and outwards at Elbow.
" Z.—Needles in the Knee-joint.
" Z 2.—United Fracture of Femur in upper third.
" Z 3.—Fracture of both Bones of Leg.
" Z 4.—Fracture of Metatarsal Bone of Little Toe.

PLATE A.

SPRENGEL'S SHOULDER.

By different observers during the last twenty years, cases have been described in which the scapula of one side is smaller than that of the other, and more highly placed. The whole shoulder is small, the clavicle is short and slender, and sometimes other defects in development are observed. The cases are all examples either of congenital defect or of changes occurring very early in infancy. We owe, perhaps, to Dr. Brown-Sequard the first reference to these conditions, and they were subsequently carefully investigated by Dr. Hughlings Jackson, who published, in the 'Illustrated Medical News' for February, 1889, an important case, with woodcuts. Both these observers examined the facts from their neurological aspect, and regarded the deformity, if it deserve that name, as probably due to partial paralysis of the lower part of the trapezius. Somewhat more recently (1891), however, Dr. Sprengel, in ignorance possibly of the opinions of these authorities, investigated the subject, and collected several examples of it. He for the first time recognized that the bones concerned were dwarfed and somewhat altered in form, as well as malplaced, and, making probably no detailed enquiry as to paralysis, was inclined to suspect malposition of the fœtus *in utero* as the cause. Following Sprengel's descriptions, Dr. Pisclinger, in 1897, collected all the cases which he could then find on record—seventeen in number—and subjected them to critical examination. In most of them the scapula was simply elevated, without any material obliquity. Unfortunately, in all, the electric examination of the muscles was omitted, and the fact that no paralysis was conspicuously present must count for but little. The question as to the real nature of the cause of the malposition must therefore be allowed to remain to reward the industry of future investigators. That something more than congenital defect in the development of a single muscle is concerned, is made probable by the fact that the bones are usually dwarfed; that it has been observed that one side of the face is often smaller than the other; and that now and then such deformities as congenital luxation at the hips, talipes valgus, and some others, are also present. In the meantime, avoiding the risk of *suggestio falsi* in the name used, it may be convenient to know the condition in its totality as "SPRENGEL'S SHOULDER."

The case which afforded our illustration (Plate A) was that of a girl of 10, who was brought by Dr. Travers Smith to the Polyclinic in 1902. From the 'Polyclinic Journal' we quote the following description and remarks:—

"Dr. Smith's patient was a well-grown girl of ten. It was seen at a glance that one shoulder—the right—was higher than the other, and when we examined closely we found that the scapula of this side was in all its dimensions smaller than that of the other. Its base was probably not less than an inch shorter, and the rest of the bone in proportion. The clavicle of the same side was more than half an inch shorter than its fellow, and was more slender. The scapula could easily be pushed down level with its fellow, but after the hand had been attempted it returned immediately to its place. All the muscles appeared to be perfect, but the shoulder was obviously smaller as a whole than that of the opposite side. As regards the child's face, the general verdict of those present was that the right half of the face was smaller than the left. The want of symmetry was, however, not great, and we must not lay any stress upon it. The child had good use of the limb, and in the fore-arm and hand the two extremities were alike. The condition had been present from birth."

To this statement we must add (quoting from a subsequent number of the same Journal) that the child was afterwards examined by Dr. Hughlings Jackson and Dr. Beevor, and that it was established that the lower part of the trapezius was certainly weak. No part of the muscle was absent, nor any completely paralysed, for all its strands could be brought into action by electricity; but the lower part was definitely defective.

It may be added that the conditions involved in "Sprengel's Shoulder" usually cause but little inconvenience. The hand and fore-arm are quite normal, and in the upper arm it is only the parts about the shoulder that are deficient in bulk. The ability to elevate the limb at the shoulder is usually somewhat restricted, in some cases more than in others. The projection of the upper angle of the scapula is often conspicuous, and its somewhat hook-like form has several times led to a mistaken diagnosis of exostosis. In the supposition that this might have some influence in limiting the movements of the limb, needless excisions have been performed. It has, in these operations, always been found that the supposed exostosis was merely the misplaced angle of the bone.

We must regard "Sprengel's Shoulder" as an addition—and one of great interest—to the large group of congenital defects which prove that it is possible for some influence (of the nature of which we know nothing) to interfere with bilateral symmetry in the development of the muscles and bones of the limbs and face.

REFERENCES.

'Rev. Mens. des Maladies de l'enfance,' March, 1900.

'Pediatrics,' vol. vi. (1898), p. 285; vol. vii. (1899), p. 351; vol. ix. (1900), p. 386.

PLATE B.

PARALYSIS OF THE SERRATUS MAGNUS.

In juxtaposition with "Sprengel's Shoulder," it may be useful to exhibit the deformity resulting from paralysis of the serratus magnus. This considerable muscle is liable to failure of function almost alone, and the symptoms which disclose its condition are very definite. During rest, with the arms at the side, there is no deformity; but when the patient carries his arm forwards and separates it from the trunk, the shoulder-blade is rotated on its vertical axis, and its spinal border leaves the wall of the chest. This malposition is well shown in our Plate, and is the most conspicuous feature. It will be seen, however, that, in addition, the lower angle of the bone has risen, and has approached the middle line, whilst, of course, at the same time the upper and outer part is depressed. In extreme cases the scapula may project like a wing from the chest, and the skin may be tucked under its border so as to form what has been described as a gutter. These features are easily explained when we remember that the action of the muscle is, when the chest-wall is fixed, to draw the scapula forwards, and thus favour extension of the extremity, and that its lower portion, acting with the trapezius, rotates the bone. In the early stage of the affection the patient experiences but little inconvenience, but the extension and elevation of the extremity are always in some degree impeded.

Amongst the occasional causes of this paralysis is violent over-exertion of the muscle in those in whom it is not usually much employed. Thus, straining at a rope during parturition was the cause alleged by a young woman whose photograph is now before us. In her case the deformity exactly resembled that shown in the Plate. In the subject of the latter there was a history of accident attended by a blow. It is possible, however, that the cause of the paralysis was not so much contusion as a spasmodic over-exertion of the muscle during the fall.

The following are the particulars of the case, as furnished to us by Dr. Scot Skirving, of Sydney, to whom we are indebted for the photograph:—

"The photograph is of the back of a man, in whom there was complete paralysis of the right serratus magnus. He has his right arm abducted and raised to a right angle with his trunk. The condition had been suddenly discovered, when one morning he was unable to hold a lamp as high as was required of him.

"The patient gave a history of an injury, sustained three weeks before he became aware of his disability, the injury being a blow which he referred to the region of the right supraspinous fossa, but which he said caused him no particular pain, and which left no mark. The blow was due to a heavy fall backwards, the part mentioned coming into contact with the corner (blunt) of a furnace-door.

"Dr. Scot Skirving, who saw the patient at the St. Vincent's Hospital, Sydney, pointed out the cause of the condition. On examination the digitations of the serratus magnus, which could be easily felt on the sound side, could not be detected on the affected side.

"After six weeks' observation and treatment, blistering over the roots of the external respiratory nerve, there was no improvement. No history of syphilis could be obtained."

Duchene has warned us that "a complex affection in which many muscles are implicated has been comprised under or confounded with paralysis of the serratus magnus."

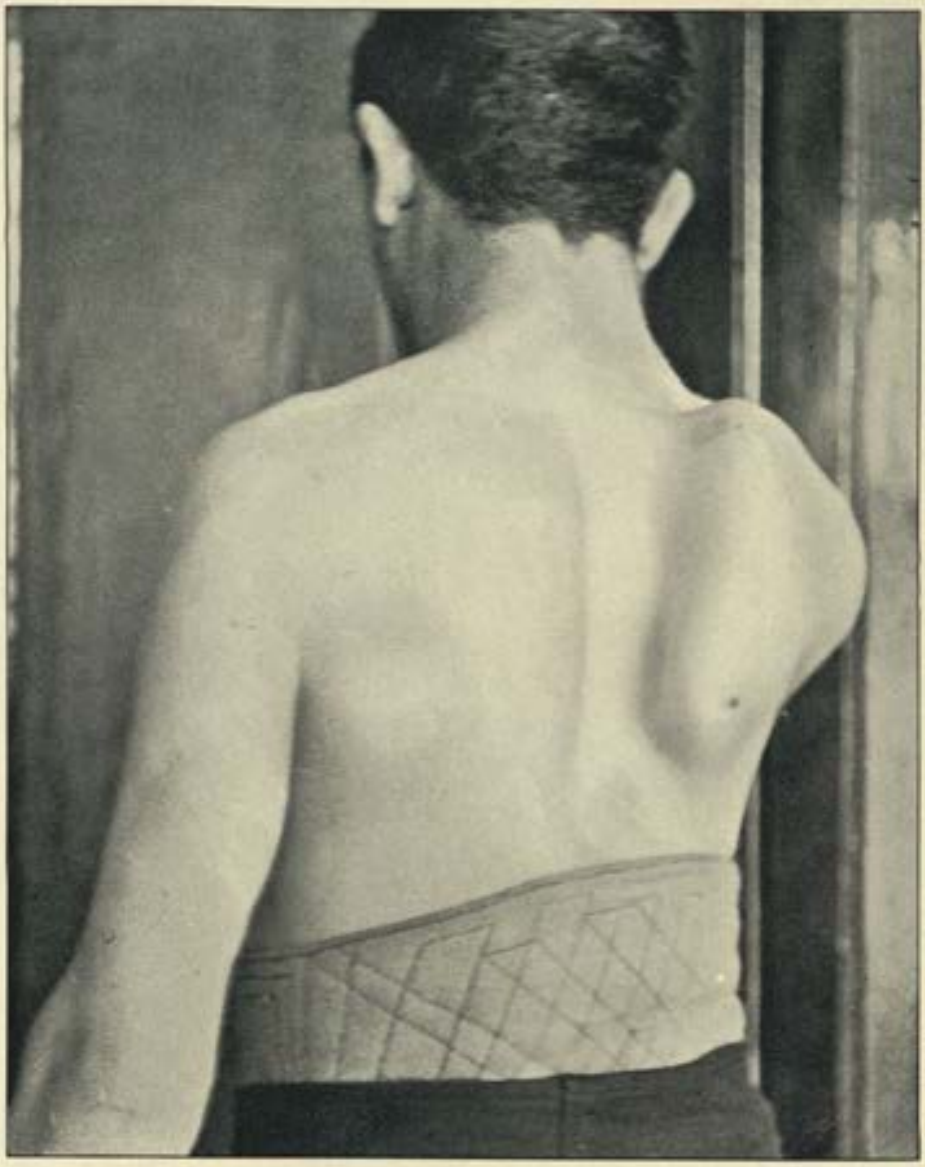

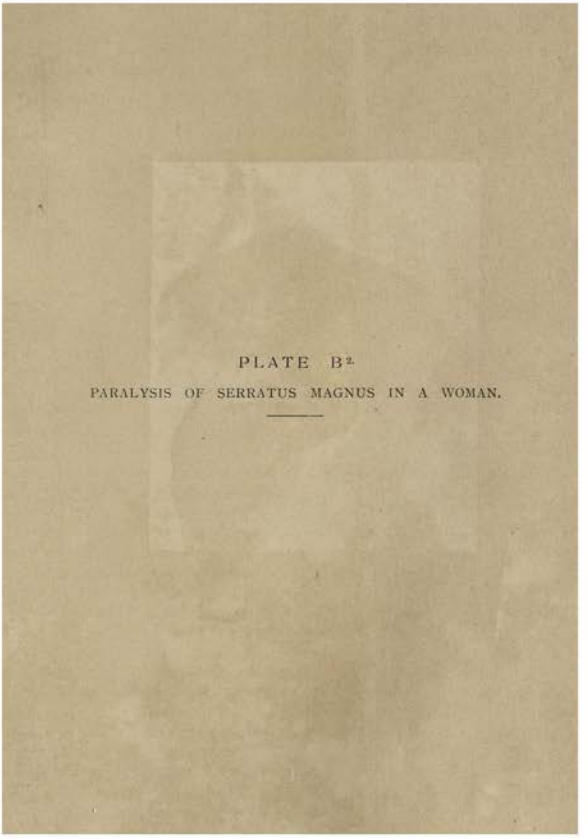

PLATE B².

PARALYSIS OF SERRATUS MAGNUS IN A WOMAN.

PLATE C.

ENGLISH CRETINISM.

This illustration is taken from a photograph of a group of inmates of an Asylum. At first sight they might be taken for children, but in point of fact all were adults. All had had the benefit of treatment by means of the now well-known specific, the thyroid extract, but not until too late. They had, however, experienced great improvement from it.

There is sometimes a great advantage in seeing things in bulk rather than by samples, and this group may serve well to impress upon the memory the peculiar features of English cretinism. It is to be observed, in the first place, that none of the individuals represented are really children. In all there has been an arrest both of mental development and physical growth. They have remained dwarfs in stature and semi-idiots as regards intellect. It would also appear that the sex characteristics have been suppressed. Dr. Ridley, to whom we are indebted for the photograph, tells us that at one time his cretinoid patients had numbered ten, but that no fewer than five had died of pulmonary phthisis.

It is now common knowledge that the diseases known as cretinism, myxœdema, and cachexia strumipriva, are all phases of the same malady. They all depend upon defective supply to the blood of the secretion of the thyroid gland. This defective supply may be dependent upon either atrophy or disease of structure in association with hypertrophy. In the cases which we see in English children the condition is usually, as in Dr. Ridley's patients, one of extreme atrophy, or even absence, of the thyroid. The great difference between cretinism and the myxœdema of adults concerns the age at which the gland fails in its function. If the failure is present from the earliest periods of childhood, there is general arrest of development; whereas, if it does not occur till adult life, we encounter only the evidences of myxœdema. This it is easy to understand, and it comes into line with many other chronic maladies in which very great peculiarities are produced if the causes come into play before full growth has been attained. For the principal advances in our knowledge of these questions we have been indebted to the Swiss surgeons, Reverdin and Kocher, and to Gull, Ord, Horsley, Semon, and last, but by no means least, to Dr. George Murray, of Newcastle.

A problem of great interest for us is the explanation of sporadic cretinism in England. Why should it happen that every now and then a child is born either without a thyroid or with the gland in a state of atrophic inefficiency? We may perhaps gain some light by taking note of the facts as observed in Switzerland. There it is well known that the cretins are usually the offspring of goitrous parents. The water of certain wells produces enlargements of the thyroid. These enlargements are often of very great size, but are not associated with any pronounced tendency to myxœdema. Yet the children of those who have suffered from them are liable to be born with glands defective in function, and thus to develop the myxœdema of childhood, that is, to become cretins. Now, in England, goitres are comparatively rare, and very seldom of large size. We are not aware whether any collection of facts has as yet been made in England which would enable us to connect sporadic cretinism with parental bronchocele. There are many facts, however, which give support to the belief that there must be a connection between the two. Amongst the laws of hereditary transmission there is probably one under which disease of any viscus, whether structural or functional, occurring in a person about to become a parent, may lead to defective development or even absence of that viscus in a child.

A Narrative illustrating the occurrence of Congenital Bronchocele by Inheritance, and also the sequence of Myxœdema to Bronchocele.

The following brief narrative may be of interest, not only to enquirers as to the remote causes of Myxœdema, but also to students of the laws of inheritance:—

A married woman, aged 32, was the subject of Myxœdema. Her tongue was swollen, deeply fissured at its sides, and was liable to present occasionally little transitory sores. Her history was that she had been twice married, and that her first husband had died of phthisis. By him she had borne two children, both now living and in good health. Her second marriage was three years ago to a very healthy man. This marriage had produced one child, a fine boy, who was born, however, with an enormous bronchocele, and died in the course of a few hours, unable to breathe. She herself had suffered from goitre in childhood, but after long treatment by iodine externally and internally, she had got quite rid of it. Several of her near relatives had also had goitres. In one (an aunt) the tumour was very large. Her own mother had one. They all lived at a village in Lincolnshire, where the disease was believed to be not uncommon. During her married life she had resided in Hampshire and South Africa.

It is no new fact that goitres may be congenital, and may be very large at the time of birth, and that when they are so they are usually inherited. Mr. Berry, in his able Monograph on "Diseases of the Thyroid," writes: "The mother of a child with congenital goitre has usually herself a goitre." Usually the goitre is of small size in congenital cases, and disappears after a time; but Mr. Berry mentions fatal cases. On the authority of Mr. Maidlow, of Ilminster, he records one in which the child died in asphyxia ten hours after birth; and a second in which "the dyspnœa was very bad for about thirty hours, but then subsided after vigorous treatment with iodine and arsenic."

Although at first sight the occurrence of congenital goitres in children born to goitrous mothers may seem to prove inheritance, the facts are exposed to a fallacy. It is generally admitted to be probable that the germs which cause bronchoceles are present in the water of certain wells. It is always possible, if during her pregnancy the mother were still drinking of the water which had caused her own bronchocele, that the germs might find their way directly to the fœtus. This suggestion might fit well with the fact that congenital enlargements of the thyroid are frequently seen in districts where endemic goitre is common, and where, presumably, many wells are contaminated. In the present instance it is of interest to record that the mother—who, it is to be noted, had previously borne two healthy children whilst resident elsewhere—had been staying for some time at her native village just prior to her conception of the child born with bronchocele. Thus she might have had freshly obtained germs in her blood at the very time of her conception. We mention the fact merely as a possibility, fully admitting that it is more probable that the infant born with bronchocele inherited it, in the strict sense of the words, from its mother, who had suffered in former years.

PLATE D.

FAMILY ALBINISM. (CONGENITAL FAILURE OF PIGMENT FORMATION.)

If we allow the term Leucopathia to comprise all affections in which there is defect of normal pigmentation, we have that of Albinism left us as applicable to its congenital form. In this there is absence of pigment from the skin, hair, eyes, and probably from all viscera. An albino is one whose skin and hair are white, and whose eyes are pink or red. The condition may be complete or incomplete, but in all cases the eyes as well as the skin and hair must be involved. All persons in whom the eyes are so lightly tinted as to be intolerant of light must be counted as partial albinos. In them usually the skin is also liable to blister if exposed to the sun. Examples of whiteness of the skin and hair with well-pigmented eyes are not to be counted as in any degree albinos; but this condition, although common in many of the lower animals, is almost unknown in the human race. The nature of its relationship to Albinism is doubtful, but it would appear probable that those animals which have established a tendency to it show but little liability to the latter. We have plenty of white oxen, horses, cats, dogs, birds, &c., but red-eyed albinos are hardly known amongst these animals. On the other hand, in many rodents Albinism is common, whilst white skins with dark eyes are scarcely ever seen.

Albinism is usually a family disease in the technical sense—that is, if one child in a family is so affected, there will, if the family be numerous, generally be others. Conforming to what is true of most other family disorders, it is but rarely hereditary. Our illustration exemplifies these two statements, for both parents are seen to be well pigmented, whilst two of their children are complete albinos. Thus we have in Albinism a most instructive demonstration that it is possible for the physiological production of one element of the normal tissues to be wholly omitted, whilst the general development of the body in other respects is satisfactory.

Albinism occurs in all countries and in all races. It has been supposed to be more frequent in the dark races than in others, and there is a certain amount of evidence in support of the belief that it is so; but, on the other hand, we must beware of the fallacy which its extreme conspicuousness amongst dark populations offers. It occurs also in the vegetable world, more especially amongst endogens.

Certain complications are not infrequently observed as concomitants of Albinism; thus the skin is usually somewhat harsh and defectively lubricated, and the hair lacks brilliancy. In a few instances (as seen in the Plate) the hair may be wanting, or there may be indications of absence of skin-glands.

In sunny regions great inconvenience is entailed by this condition. The patient is so dazzled by light that he can scarcely leave shelter until the sun has gone down, and his skin is liable to blister on any slight exposure.

Amongst subjects of much interest for future enquiry respecting albinos we have the following:—

Are any other peculiarities to be observed—idiosyncracies as to digestion, or the effects of drugs, &c., &c.?

Are the functions of hearing, taste, or smell in any degree impaired?

Is there ever any evidence of hereditary transmission?

Is it ever the result (apparently) of consanguineous marriages?

What is the longevity of its subjects?

PLATE E.

INDURATED ERYTHEMA OF THE SCROFULOUS (BAZIN'S MALADY).

The conditions illustrated in this Plate are those of what was described by Bazin under the name of Indurated Erythema of the Scrofulous, and which has since been designated "Bazin's malady," or, more familiarly, "Bazin's legs." Its general features are now well known, and great clinical importance attaches to it on account of its close resemblance to certain syphilitic lesions, and the consequent risk of erroneous diagnosis. The first stage is the formation of dusky or livid indurations in the skin and subcutaneous tissue of the legs. These might be mistaken for Erythema nodosum, but it is only at this stage that the designation of Erythema is at all applicable. The subsequent stages are characterized rather by ulceration. The dusky nodules soften and ulcerate, and others are produced in their neighbourhood, evidently by an infective process which causes spreading in the cellular tissue. The edges of the ulcers are usually ragged and undermined, and appearances are thus produced which closely resemble those of ulcerated gummata.

The patient from whom the photograph here copied was taken was a girl of 17, under the care of Dr. Arthur Hall at the Sheffield Infirmary. The disease had been present three or four years, usually better in summer and relapsing in winter. Both legs were, as is usual, affected. The first stage was the formation of small deeply-placed painful nodules, which tended to ulcerate. After ulceration there was little or no pain. Dr. Hall did not succeed in discovering the tubercle bacillus in the discharges, &c., nor was any history of family tuberculosis established. The effect of treatment by rest, &c., was beneficial for a time; but relapses occurred, and the disease was not cured when the patient was lost sight of.

The following general statements respecting this malady may be of interest:—

The tubercle bacillus has been but very rarely identified in connection with the lesions.

There is in most cases a clear history of tuberculous ailments in other members of the family.

The subjects are usually young, and often obviously delicate. Enlargements of glands in the neck and liability to phlyctenular ophthalmia and other indications of Scrofula are not unfrequently present.

The sores are almost invariably confined to the legs, occurring almost exclusively between the ankle and knee. They may, however, be met with sparingly above the knee, and sometimes on the backs of the upper arms.

Although often very intractable at first, a cure is usually effected after some years, to which, possibly, advancing age contributes somewhat.

The best treatment of the disease is that of Scrofula;—residence at the sea, abundant fresh air, liberal diet, with cod-liver oil, &c., &c. Local measures are of great importance, and the unguentum metallorum, iodoform, xeroform, chinosol, and iodol should be tried in succession, if necessary, and one or other of them should be persevered with. The results of scraping and of the application of caustics are often very disappointing. It is not, as a rule, desirable to confine the patient to bed. Prolonged residence in a tropical climate would probably be found very beneficial. As is the case with common lupus, the disease is always worse in cold weather.

[Other portraits, some with colour, illustrating this affection, are in course of preparation for this Atlas.]

PLATE F.

ACCESSORY OR SUPPLEMENTARY THYROIDS.

The subject of this case was a young woman of 25, and was under the care of Mr. Thelwall Thomas, of Liverpool. Eight years ago she had noticed painless lumps under her right ear. At intervals others had appeared and spread down the neck. On various occasions, under another surgeon, single lumps had been excised (Nov. 1894 and Feb. 1895). On the latter occasion the spinal accessory nerve was injured. On these occasions the masses removed were supposed to represent lymphatic glands.

The patient subsequently came under the care of Mr. Thomas, by whom on May 1st, 1895, several masses were removed which proved on examination to be composed of thyroid tissue.

Fig. 1.—Portrait of patient.

Fig. 2.—Portions of thyroid tissue removed (three-fourths actual size).

Fig. 3.—Photo-microscopic, with low power.

We are indebted to Mr. Thelwall Thomas for the photographs which are here reproduced. They were exhibited in the Annual Museum of the British Medical Association two years ago.

The thyroid gland, in common with the spleen and other glandular viscera, is prone to have in association with it one or more accessory but distinct growths. From Mr. Berry's Monograph on Diseases of the Thyroid we extract the following:—

"Accessory thyroids form another class of congenital malformations of the gland. When enlarged by disease, they may form tumours which are difficult to diagnose. They have sometimes been of the greatest service to patients from whom total extirpation of the thyroid gland has been performed. By undergoing compensatory hypertrophy, and assuming the functions of the extirpated gland, they have saved such patients from cachexia strumapriva" (page 15).

This latter statement of Mr. Berry's would appear to imply that accessory thyroids are by no means very rare.

FIG. 1.

FIG. 2.

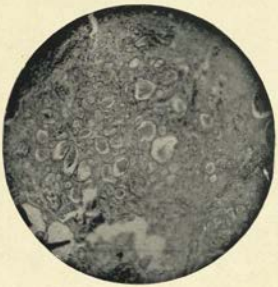

FIG. 3.

PLATE G.

CASE OF TUBEROUS LEPROSY (OCCURRING IN GIBRALTAR).

In this portrait we have a good example of the ulcerating tubercular form of leprosy. In this form the nerve symptoms are often ill-marked, although never wholly absent. Although the ulcerations may be extensive they are often but little painful, and do not disable the hands. The portrait is copied from a photograph kindly supplied to us by Staff-Surgeon John Henry Thomas, R.N.

The patient was a Spaniard, aged 49, a gardener, working in Gibraltar, but living with his wife in a small town, La Zinca, just over the frontier. He had a son, aged 9, who was the subject of tubercular disease of the knee-joint. His wife remained healthy. The man stated that he had eaten fish all his life, and very frequently; very often it was the salt cod imported from Newfoundland. His usual health was good, but he had lost flesh somewhat of late. His ulnar nerves were thickened. It will be seen that the bridge of the nose is sunken.

It is obvious that, as risking the contamination of food, this is, socially, the most dangerous form of leprosy. It is also the most severe, and runs the shortest course; but it is not irremediable. Under suitable treatment the ulcers will heal, and the tuberous folds of skin will thin down. The case of recovery recorded in the Medico-Chirurgical Society's 'Transactions,' vol. 62, 1879, was that of a patient whose condition was at one time much like that which is here represented.

This was the only case which had come under Mr. Thomas's notice during his residence in Gibraltar. It is estimated that there are fifteen hundred lepers in Spain. The disease is never met with far inland, but is more common in agricultural districts near to the coast than on the coast itself. Large quantities of salted cod, under the name of Bacalhao, are eaten by the Catholic population of Spain and Portugal. It is imported from Norway and Newfoundland. Dr. Donnet, in a Report on Leprosy in Portugal, tells us that all classes eat this fish, where obtainable, on two days of every week.

PLATE H.

MALIGNANT SYPHILIS.

Syphilis Maligna is a term which some authors apply to cases in which the late secondary stage of syphilis is of very exceptional severity. The eruption is suppurative, and tends to the production of rupial crusts or of spreading ulcerations, and is attended by emaciation and failure of strength. In a few cases even death may result.

In former times, when the characters which distinguish secondary from tertiary phenomena were less well understood than at present, these cases were spoken of as "precocious syphilis"; and it was supposed that the disease ran a rapid course, and that tertiary symptoms supervened on secondary without any interval. We now recognize that for the most part there is no foundation for such a creed, that the special features of the tertiary stage—large gummata, visceral and bone disease, &c.—are wanting, and that those present usually belong exclusively to the secondary group. It is a mistake to believe that ulceration, however severe, is any indication of stage, since it may attend even the very earliest. This correction of a misapprehension is of great practical importance, since in almost all cases of malignant syphilis it is the specific for the secondary stage, and not that for the tertiary, which is chiefly required.

In not a few cases of malignant syphilis it is the timorous neglect of mercury, or the attempt to substitnte the iodides for it, which has led to the abnormal development.

The case which has been selected as an illustration (see Plate H) well exemplifies what has just been said. Mercury had previously been neglected, and the patient was cured when subsequently it was judiciously pushed. In the course of a few months the man regained excellent health, and got fat. The disease had been contracted from a native woman.

He was under the care of Dr. Martin Doyle, of Newcastle, New South Wales.

It may be safely believed that in the majority of cases it is idiosyncracy on the part of the patient which influences the severity of syphilis, and determines the special characters, not alone of the secondary eruption, but also of the primary sore. We can no more assign the cause of malignant secondary eruptions than we can that of petechial or hæmorrhagic Variola. The poison in both diseases is the same in all cases; but in some cases its effects run a benign course, and in another a malignant one. The proclivity is often a matter of family or racial inheritance, and that is about as far as our knowledge extends. Respecting syphilis, however, we know also this further, that idiosyncracy as regards the two specifics often also exercises an important influence. In not a few cases the history given is that early occurrence of profuse ptyalism had made the suspension of the mercury seem necessary. If in all cases of early syphilis mercury were given in small doses at first, and then gradually increased with cautious avoidance of salivation, it is probable that "malignant syphilis" would become unknown. The combination of quinine and opium with the mercury is often of great benefit in these cases, but it is essential that the mercury be not omitted. The precise mode of its administration is not, perhaps, of great importance so long as it be efficiently given.

PLATE H 2.

RUPIAL ERUPTION IN SECONDARY STAGE OF SYPHILIS.

Dr. Arthur Hall, to whom we are indebted for the photographs, writes :—

"Each spot consisted of a circular deep ulcer, with straight cut sides, about ¼ to ½ inch wide; the central part had healed, so that the ulceration formed a kind of moat around the scar. When first seen these spots were covered with heaped-up rupial crusts."

The man had been a heavy drinker. Under treatment by iodide of potassium internally, and black wash to the sores, the latter all healed. The stage was the late secondary, but the precise date of the primary sore was not recorded.

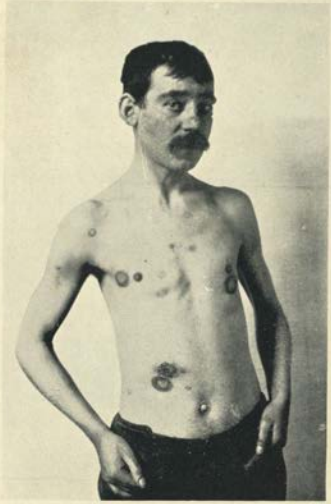

PLATE H[3].

MALIGNANT SYPHILIS OF FRAMBŒSIAL TYPE.

It has been conjectured—and the suggestion is not without plausibility—that Syphilis is especially prone to run a severe or malignant course when it is contracted from a person of different race from that of the recipient. Thus it is thought that Europeans having intercourse with coloured women are in especial danger of contracting a severe type of disease. This supposition may be held to derive confirmation from the case which supplied Plate H., for in that instance the patient, a sailor, contracted his disease from a native black woman. It is, however, very certain that some of the worst cases may be met with in European practice, and where giver and receiver have belonged to the same race.

That the disease is, in the dark races, often of a severe and ulcerative type is well known. Of this our present Plate affords a good illustration. It will be seen that the body and limbs are covered almost symmetrically by an eruption very similar to that shown in Plates H. and H[2]. Everywhere the eruption had fungated, ulcerated, and formed crusts.

The photographs which have been copied in this Plate are from the collection of Dr. Murray, the Professor of Surgery in the Calcutta Medical College. There was never any doubt that the disease was true Syphilis, since the man had had a hard chancre on the penis. It is important to note this, because the type of eruption is in part frambœsial, and closely resembles those which have been described under the names of "Yaws" and "Frambœsia tropica."

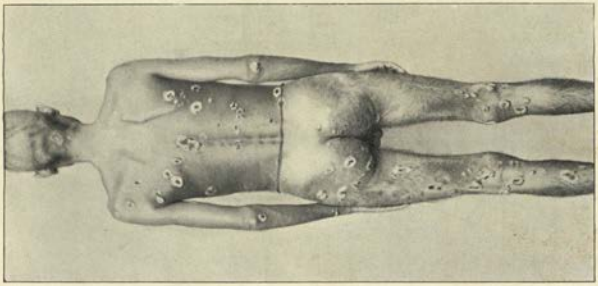

PLATE H[4]

SYPHILIS MALIGNA OF FRAMBŒSIAL TYPE.

In this Plate and the next, which are taken from the same patient, we have another illustration of the occasional severity of the secondary eruption in members of the dark races. Here not only has the eruption ulcerated, but fungating granulation-masses have sprung up. In some instances these granulation masses are produced on the surface of ulcers, and in others they appear to develop without any very obvious destruction of tissue having preceded them.

In the present instance, the patient, who came under the personal observation of the writer in Colombo, Ceylon, had an indurated chancre still present on his penis. There could, therefore, be no question that his eruption was that of secondary syphilis. Yet the frambœsial eruption was exactly similar to those which, when met with independently of any recognized chancre, are diagnosed as "Yaws" in the West Indies, or in Ceylon as "Parangi," these terms being applied to eruptions resulting from non-venereal syphilis, the chancre having occurred on some part of the body other than the genitals.

Although frambœsial eruptions in Syphilis are generally indicative of a severe type, they are not invariably so, and the term Malignant Syphilis is by no means always applicable. Ulceration without papillary growth is a yet more serious condition, and implies yet more definitely that the patient has peculiar susceptibilities in reference either to the virus or the specifics needed for its cure. Between rupial eruptions and those of frambœsial type there are, however, various gradations, and no strong line of demarcation can be drawn. Both alike require specifics, local and humoral, for their cure.

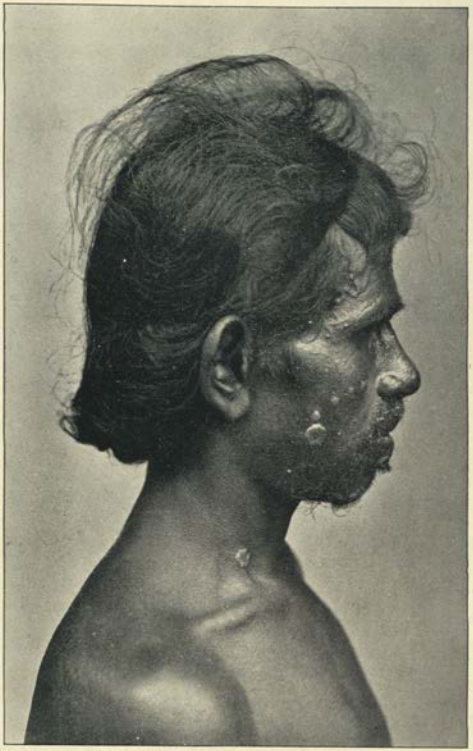

PLATE H5.

SYPHILIS MALIGNA OF FRAMBŒSIAL TYPE (A CINGALESE).

This portrait is from the same case as that described in the preceeding Plate.

PLATE I.

PRIMARY CHANCRES ON THE HAND OF A MIDWIFE.

This plate is copied from a photograph exhibited by Dr. Arthur Hall, of Sheffield, at the Annual Museum of the British Medical Association in 1892.

The portrait is of interest as showing that the primary sore, when occurring on the naked skin, may display no very distinctive features.

There were two sores which had appeared at the same time. Dr. Hall describes them as having hard bases.

Secondary symptoms followed.

PLATE J.

SYPHILITIC SERPIGINOUS LUPUS.

The portrait given in this Plate is from a photograph supplied to us by Dr. Arthur Hull, of Sheffield. It represents a very common condition in the tertiary stages of Syphilis, in which serpiginous cutaneous gummata simulate Lupus Vulgaris. The simulation is often very close, so that in the absence of history it may be almost impossible to make a diagnosis. As a rule, however, the syphilitic simulation may be distinguished from its prototype by certain features which to the skilled observer at once suggest suspicion. In the syphilitic form the progress is more rapid; there is more of crust formation and less of hypertrophic infiltration than in true Lupus. As the invasion-processes are more rapid, so also are those of cicatrization, and the scar left is much thinner and more supple than is the dense veal-like or leather-like cicatrix which, for a time at least, usually follows the healing of Tubercular Lupus. This proneness to spread rapidly and to heal quickly often gives peculiarity of form to the patches of Syphilitic Lupus. They may become mixed with round scars in the centre, or, what is more common, they may break at one part of their borders, whilst continuous at others, and thus produce the well-known horse-shoe form. Equally in the syphilitic as in the tubercular form, it is very evident that an infective material is produced in the borders of the patch, and that the spreading is by the contagion of continuity of tissue. In neither does the process ever again attack the scar which has been left, and both invariably leave a scar. It has been plausibly suggested—and the clinical history of the case often supports the suggestion—that syphilitic lupoid affections of the skin often occur to those who, being the subjects of latent tuberculosis, have had the misfortune to contract syphilis. On this supposition the morbid processes result from a partnership of the toxine of syphilis with the tubercle bacillus, and the term "Syphilitic Lupus" becomes justified.

Syphilitic lupoid affections belong to the late stages of the disease, and may occur to those who are quite free from any other manifestations. They are rarely seen until two or more years have elapsed since the date of contagion, but a few exceptions to this do undoubtedly occur. The patches may be single or numerous, and in some instances may involve almost the entire surface of the body. They may last for many years and be still aggressive, if not treated; as a rule, they are amenable to treatment, and, although perhaps resisting the internal administration both of mercury and iodides, will yield to the persevering application of such remedies as iodoform, xeroform or chinosol. Of these the first-named is the most generally effectual. In many instances cauterization of the patches —just as in Tubercular Lupus—very much expedites the cure. Destruction of the contagious materies is in both instances the necessary step towards cure.

PLATE K.

CORYMBIFORM SYPHILITIC ERUPTION.

Amongst the very various forms which secondary syphilitic eruptions may assume, is one which has been named Corymbiform. Its patches have been supposed to resemble the corymb of an umbellate flower-stalk when seen from above. The term *en cocade* is applied by French surgeons to conditions not very dissimilar, but in which more definite appearances of concentric arrangement are present. The condition is that of a number of tufts of dilated capillaries placed in juxtaposition, and coalescing by their edges. The patch may be as large as a watch-face. They are not usually very numerous. They occur chiefly on the trunk.

Corymbiform eruptions are not often seen early in the secondary stage, and have usually been preceded by one of roseolous or macular type. There is, however, no reason to suspect that they are due to any modification effected by the treatment. They must be regarded as implying a severe attack, and it is thought to have been observed that they are more frequently than other eruptions followed by iritis. They are, however, rare, and it is not safe to formulate opinions respecting them with much definiteness. They are to be treated, like others, by mercury.

The Plate is from a photograph in the collection of Dr. Arthur Hall, of Sheffield.

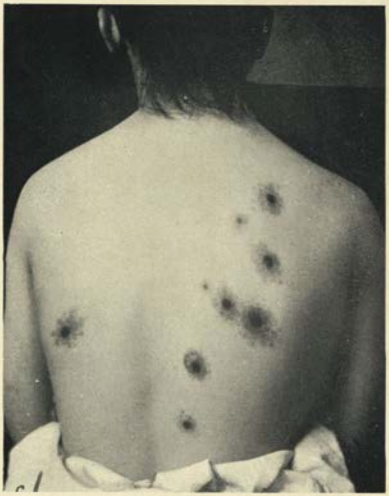

PLATE L.

DETACHMENT OF THE UPPER EPIPHYSIS OF THE HUMERUS.

The upper end of the humerus constitutes a large almost globular epiphysis, in which ossification begins at the end of the first year, and is not quite complete until the twentieth. There is a separate centre (sometimes two) for the tuberosities, but at the end of the fifth year these are united with that for the head of the bone. Some latitude must be allowed for individual peculiarities as regards the date of completed bony union of the whole epiphysis with the shaft. At the date of puberty the layer of epiphysial cartilage which intervenes between shaft and epiphysis is very thin, and after that period it is gradually obliterated. During the early years of childhood, whilst the epiphysis consists in the main of cartilage, it is very seldom that violence causes anything approaching to fracture or detachment. The somewhat buffer-like elasticity of the part probably contributes to prevent such occurrence. So soon, however, as the head has well advanced in ossification, the risk of its detachment as a whole commences, and it probably increases with time until the junction is complete. During this period—that is, from 8 to 18—the line of epiphysial union is the weakest part of the upper third of the shaft, and neither dislocation at the joint nor fractures through the bony part of the shaft are frequent. The same kinds of violence which in the adult would produce either a dislocation or a fracture through the surgical neck will during these years very probably detach the epiphysis. The detachment is often—as shown in the two illustrations now given—complete and uncomplicated, and attended by a certain amount of displacement. The direction of the displacement will vary with that of the violence which produced it, but, owing to the large area of the surfaces involved, it will seldom or never be such as to allow the bones to entirely lose apposition and to overlap. Thus the symptoms of shortening can seldom be present in any demonstrable degree. The only possible exceptions to this occur when the upper end of the shaft is carried into the axilla, and the epiphysis tilted outwards by the muscles attached to the tuberosities. In the great majority of cases the displacement is, as represented in these Plates, only partial, and all that can be detected by the finger is a projecting ridge or ledge (by some described even as "a table"), which consists of the upper surface of the end of the detached shaft.

A very common complication of these accidents is the detachment of small fragments of bone from the borders of the end of the shaft. These are attached to the sleeve of thick periosteum which always remains united with the epiphysis. The upper end of the shaft is often denuded of periosteum for a length of one, two, or three inches. In rare cases this denudation is followed by suppuration and necrosis.

Although there is probably never any degree of penetration, yet the detached shaft is usually firmly impacted by its large and uneven surface against that of the epiphysis; the bone moves as if unbroken, and crepitus cannot be elicited unless undue force be used. It happens from what has just been said that these cases are but seldom diagnosed in the first instance. Neither the symptoms of dislocation nor those of fracture are present, and the swelling of the parts conceals the unevenness of the surface of the bone. It is usually only at a later period when all swelling of the soft parts has disappeared that the nature of the injury becomes apparent. At this period attempts at reduction would offer no promise of benefit, and the case must be left to the reparative processes of nature, which are usually very efficient.

Some interference with the subsequent growth of the bone must be expected. It will, of course, be in inverse relationship with the age of the patient at the time of the accident.

Of the two radiographs which we have selected to illustrate these detachments, one shows the shaft displaced towards the axilla, and the other outwards. In both there has been some splintering of the upper end of the shaft, which has the effect of making the under surface of the epiphysis constitute a cup for the reception of the end of the shaft. In each case the patient was a young man of eighteen years of age.

It will be obvious that in neither case was there much to be hoped for as to rectification of position, but in both the shaft is fairly well in line with the epiphysis, and no material deformity could result. In Plate M the displacement of the shaft outwards would in the end give to the united bone a thick oblique neck approximating in form to that of the femur. This alteration of form is occasionally encountered after detachments of the epiphysis and fractures of the surgical neck. Remotely it brings about a displacement of the head downwards, and causes a hollow under the acromion, which may lead to suspicion of an overlooked dislocation. From this mistake—in former years not uncommon—resort to the rays may be expected to save us in future.

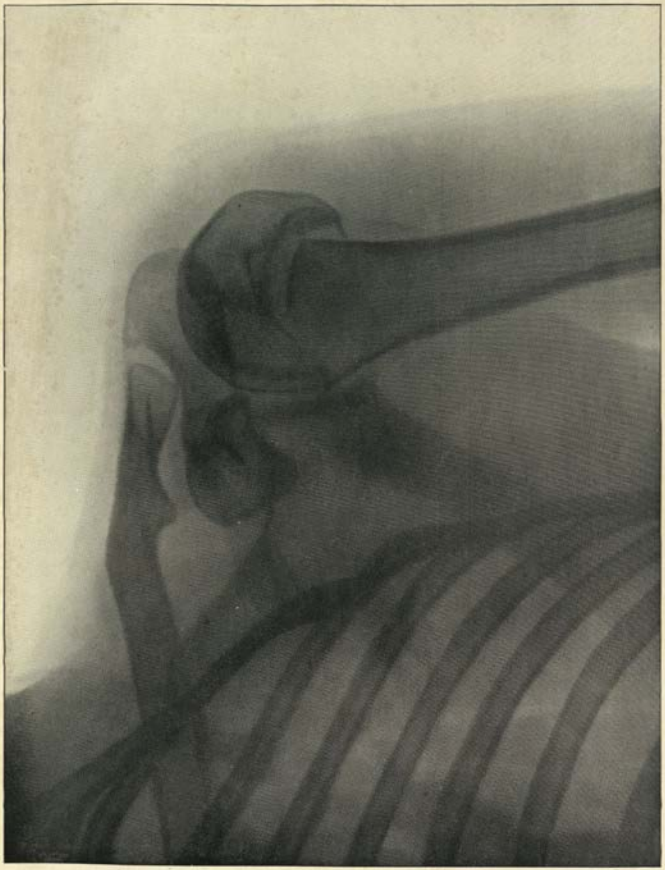

PLATE M.

SEPARATION OF UPPER EPIPHYSIS OF HUMERUS.

See description of previous Plate.

We append anatomical illustrations showing (1) the line of the epiphysis in a section of the bone, and (2) the condition of the fragments in a complete experimental detachment.

FIG. 1.

FIG. 2.

PLATE N.

FRACTURE OF THE GREATER TUBEROSITY OF HEAD OF HUMERUS.

The patient in this case was a man of 56. He had been thrown violently from a bicycle, striking his shoulder on hard ground. Some weeks had elapsed since the accident, and the fragment was firmly united by bone.

It will be seen that the greater tuberosity has been detached by an almost vertical fracture through its base, and that it is somewhat displaced upwards.

(From the Jones-Morgan Collection.)

PLATE O.

VERTICAL FRACTURE OF CARPAL EXTREMITY OF RADIUS, WITH DISPLACEMENT.

The injury in this case was caused by a fall from a trap twelve weeks before the radiograph was taken. The man was supposed to have fallen with the left side of his palm to the ground. There was some limitation of both flexion and extension, but it was not sufficient to induce the patient to submit to the treatment which was recommended. It will be seen that the styloid process of the radius, with a considerable portion of the bone at its base, has been detached by an almost vertical fracture which passes upwards an inch and a half, and has been displaced upwards so as to rest against the side of the shaft. With it the carpus and hand have been displaced outwards. The os magnum has been dislocated, and rests in front of the radio-ulnar articulation.

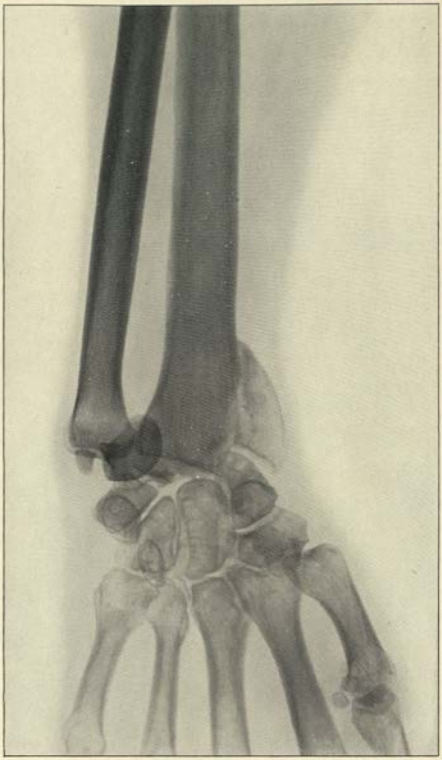

PLATE P.

TRANSVERSE FRACTURE OF BOTH BONES OF FORE-ARM.

In this instance both bones of the fore-arm have been broken almost transversely across at the junction of their middle with lower thirds. They are in apposition end to end in the case of the ulna, without any displacement, and with but little in that of the radius. Bony union has already occurred, with, in the case of the radius, some evidences of ensheathing callus, due to detachment of periosteum. In the ulna a dark line is the only evidence of fracture, and probably the periosteum was not in the least torn. Hence the entire absence of callus. In such a case it is clear that there could be little or no deformity, and that nothing more than a straight, well-cushioned splint could have been needed.

(*From the Jones-Morgan Collection.*)

PLATE Q.

TRANSVERSE FRACTURE OF SHAFT OF RADIUS.

This Plate exhibits an almost transverse fracture of the shaft of the radius, at the junction of the lower with the middle third, by direct violence. The end of the lower fragment is seen to be displaced towards the ulna, but not so much so as to lose apposition with the upper one. Thus there is no overlapping, although there may have been a little shortening. The displacement may be attributed in part to the action of the pronator quadratus, though more probably it was in the first instance due to the direction in which the violence was applied.

This radiograph well exhibits the usefulness of the Rays in the diagnosis of fractures, since it might have been very difficult without their aid to have recognized the exact relations of the bones. Vigorous extension under an anæsthetic, with lateral pressure on the lower part of the upper fragment, would be the measures suitable for reduction. It is probable that if the bones were once brought accurately end to end, they would be so locked together that no further displacement need be feared, and the action of muscles might be wholly disregarded. On the question as to whether or no such re-apposition had been attained, the aid of the rays would, however, be requisite.

(From the Jones-Morgan Collection.)

PLATE R.

COMMINUTED FRACTURE OF THE RADIUS IN THE MIDDLE OF ITS SHAFT.

In this instance we have the results of a fracture by direct violence. The radius is broken near its middle, but without material displacement, although there is comminution and detachment of a fragment nearly an inch in length. It is somewhat difficult to realize from the position of the fractured surface how perfect re-apposition could be effected. Probably the line of fracture was more or less spiral. Fortunately the axis of the bone is almost normal, and, as the ulna is not broken, there could be but little difficulty in the treatment; a well-cushioned straight splint would be all that was needed.

(From the Jones-Morgan Collection.)

PLATE S.

FRACTURE OF SHAFT OF RADIUS UNITED WITH DISPLACEMENT.

The radius is seen to have been fractured a little below the middle of its shaft. There is overlapping of the broken ends to the extent of nearly an inch. The end of the upper fragment is displaced towards the ulna, and that of the lower one backwards, where it must have projected immediately beneath the skin. The patient was an adult, and the fracture had occurred some months before the patient came under Mr. Jones' observation. It will be seen that a broad thin bridge of new bone connects the fragments, and that a long splint of new bone has been formed on the outer border of the upper fragment and the inner side of the lower one. At these positions no doubt the periosteum had been torn up. There must have been some considerable displacement of the hand, and the carpal end of the ulna must have projected strongly (see next Plate). The defect in treatment has been deficient extension. Had the X-rays been employed in the first instance, no such displacement could have been overlooked.

(From the Jones-Morgan Collection.)

PLATE S²

FRACTURE OF RADIUS UNITED WITH OVERLAPPING.

This radiograph is from the same case as the preceding. Note the displacement of the extremity of ulna.

(From the Jones-Morgan Collection.)

PLATE T.

FRACTURE OF THE SHAFT OF THE ULNA.

In this instance a fracture of the ulna has occurred in the lower part of its upper third. It is not transverse, and thus, without any real overlapping, considerable displacement has been permitted. The lower end of the upper fragment projects strongly under the skin, whilst the upper end of the lower one has passed towards the radius. The action of the triceps may have contributed to this malposition, aided by a *movement en totalité* of the fore-arm forcing upwards the lower fragment between the radius and the upper fragment. Efficient extension is clearly the measure of treatment required. The radiograph well illustrates the value of the Rays in revealing the exact position of the broken bones, and thus suggesting the necessary measures for reduction.

(*From the Jones-Morgan Collection.*)

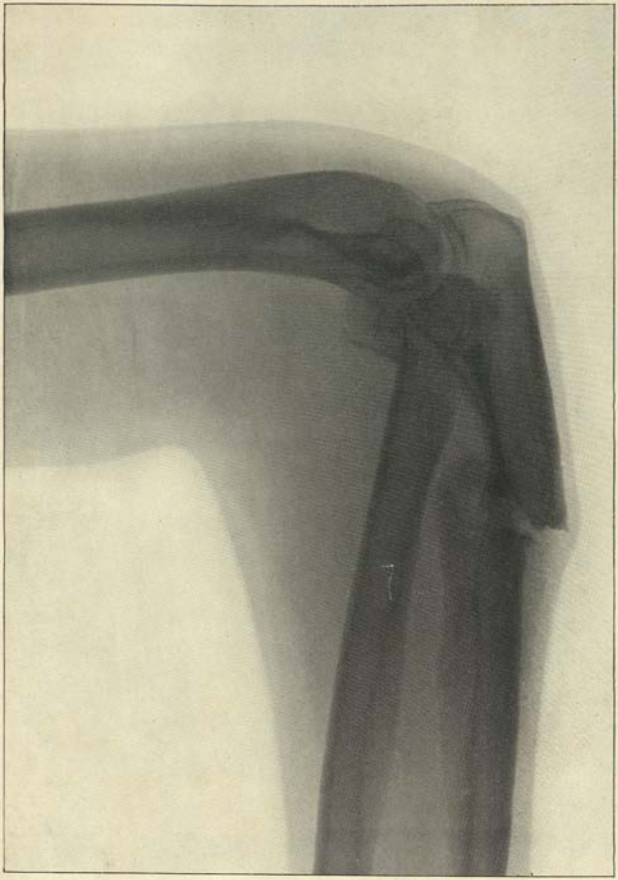

PLATE U.

FRACTURE OF THE OLECRANON.

In this Plate we have shown a fracture of the olecranon in the right elbow of a man aged 27. The injury had been received, three weeks previously, from a fall on the elbow, striking it on the edge of a kerbstone. The radiograph was taken with internal surface of the arm down. It will be seen that there is a wide gap at the site of fracture. The latter is accurately transverse, and without splintering. Inability to straighten the arm completely was one of the symptoms. Wiring of the fragments, and a position of the limb as nearly straight as possible (for a time), were clearly the measures indicated. The Plate may be regarded as illustrating the most usual form of this fracture.

(From the Jones-Morgan Collection.)

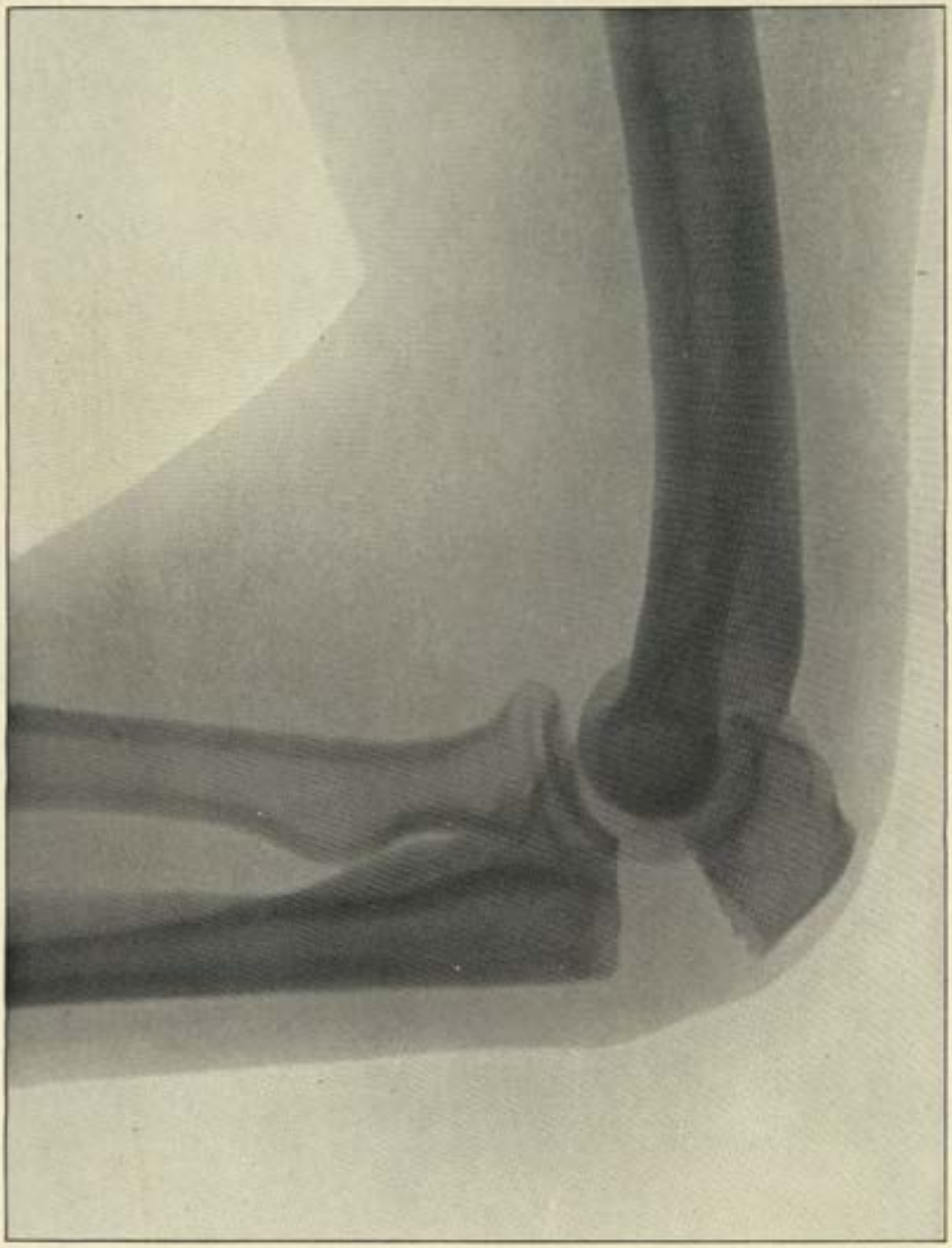

PLATE V.

FORWARD DISLOCATION OF THE RADIUS AT ELBOW, WITH FRACTURE IN LOWER THIRD OF ULNA.

This radiograph (taken many years after the accident) shows an ununited fracture of the ulna, with considerable overlapping, in association with a dislocation forwards of the radius at the elbow. There are other compensating changes. The articular surfaces of the radius and ulna are no longer on the same level at the wrist-joint. The ulna has passed downwards with the carpus, and the articular face of the radius slopes to the ulnar side. The head of the radius (the shaft of which is curved) at the elbow has passed upwards and forwards, and has also undergone some alteration in form. There are also changes in form in the lower end of the humerus and of the coronoid and ulna. At the site of fracture the ends of the broken bone overlap considerably, and, although pointed, their edges have become rounded off. The shortening may have been to the extent of an inch or more.

A moment's consideration will make it clear that in the case of the fore-arm, if either bone is implicated, whether by dislocation or fracture, in such a manner as to involve shortening, there must be some corresponding displacement of the other. Otherwise the one bone serves as a splint for the other, and the normal length is maintained. Thus in dislocation forwards of radius at the elbow it is almost a matter of necessity that the shaft of the ulna must be broken. This association of injuries is well illustrated in the Plate before us.

(*From the Jones-Morgan Collection.*)

PLATE W.

UNITED FRACTURE OF BOTH BONES OF FORE-ARM.

In this instance both bones of the fore-arm have been broken across at the junction of the lower with middle third. The fracture of the ulna has been almost transverse, that of the radius somewhat oblique. The ulnar fragments are end to end, but those of the radius overlap somewhat. The axis of the limb is definitely bent towards the ulnar side, and it is evident that the surgeon in whose hands the case had been had not been successful in securing good apposition. It may be doubted whether the wiring has secured any better result than might have been obtained by straight splints and efficient extension. The fracture was by direct violence.

(From the Jones-Morgan Collection.)

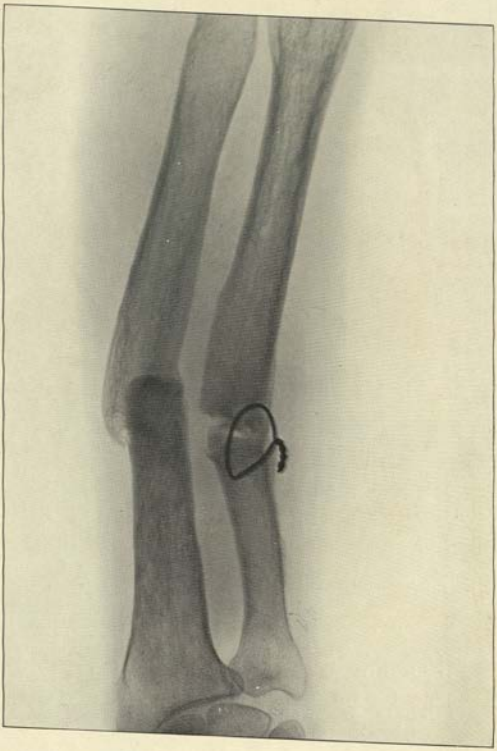

PLATE X.

MULTIPLE FRACTURES OF BONES OF UPPER EXTREMITY, WITH NON-UNION.

The fractures represented in this Plate were caused by the arm being caught and twisted round in machinery. The subject of the accident was a man aged 26, and the radiograph was taken ten weeks subsequent to its occurrence. Several of the fractures were still ununited.

The humerus was broken in the middle of its shaft almost transversely, but with complete detachment of one fragment, which had become fixed on the end of the distal portion. At the commencement of the lower third of the forearm both bones had been broken across almost at the same level, with some splintering and much displacement. The ends of the broken radius are seen to be united, but with much displacement, whilst between those of the ulna there is no union whatever; a fragment which had been detached is, however, seen to be united to the lower portion of shaft. The styloid process of the ulna has been pulled off, and there is a transverse facture (now united) of the radius an inch above the articulation, with very slight displacement.

The ends of the bones where non-union has occurred are somewhat rounded. The whole shows tendency to union wherever the broken ends of bones have come into contact.

(From the Jones-Morgan Collection.)

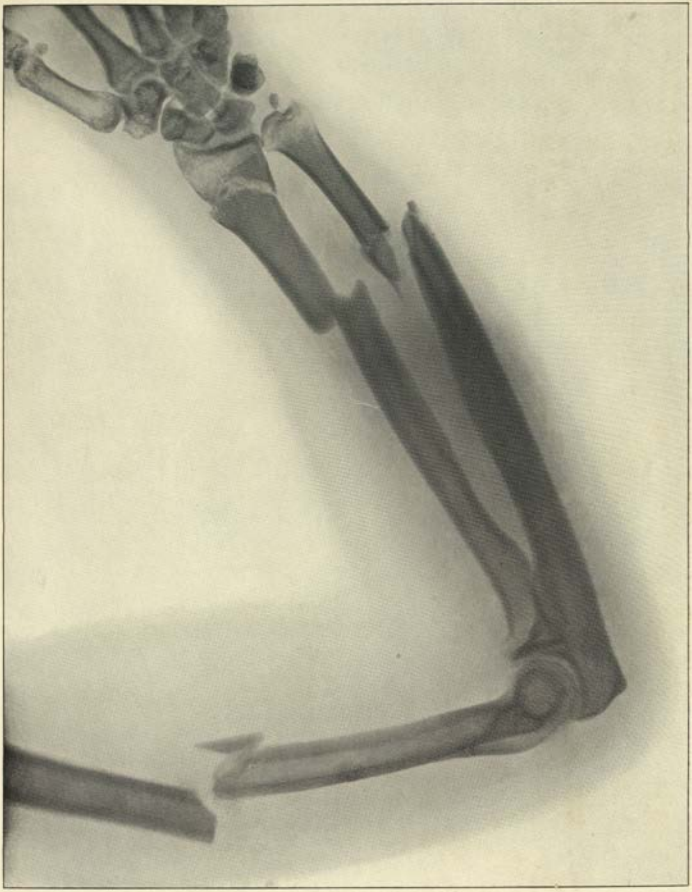

PLATE V.

DISLOCATION OF BOTH BONES OF FORE-ARM BACKWARDS AND OUTWARDS AT THE ELBOW.

The right elbow of a woman, aged 46. Four weeks had elapsed since the accident, which was a fall amongst rough stones, striking the elbow. The projection backwards of the olecranon and the empty sigmoid notch are conspicuously shown, but it is not possible in this view of the bones to appreciate the forward projection of the inner condyle. A cursory inspection might seem to suggest an inward displacement. This impression is at once removed by inspection of back view, which is given in the next Plate. The tip of the coronoid process rests against the extremity of the humerus, and is not in the olecranon fossa.

(From the Jones-Morgan Collection.)

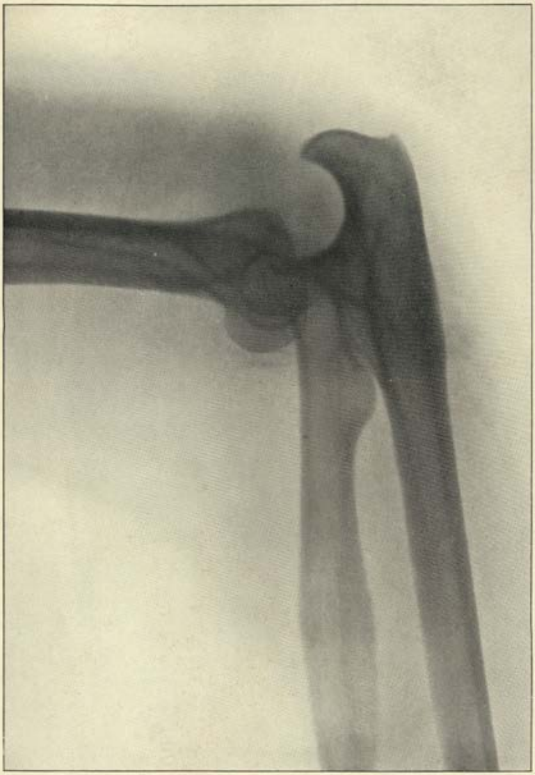

PLATE Y2.

DISLOCATION OF BOTH BONES OF FORE-ARM BACKWARDS AND OUTWARDS.

A view from behind, from the same case as that illustrated in the previous Plate. (Back surface down.) The relation of the ulna to the olecranon fossa is well shown.

(From the Jones-Morgan Collection.)

PLATE Z.

HYSTERIA.—INTRODUCTION OF NEEDLES INTO THE KNEE-JOINT.

One amongst the well-known and multiform tricks which may be perpetrated by hysterical young women is that of introducing needles into various parts of their bodies. The knee-joint has been selected in more than a few instances. The habit once commenced seems to acquire a certain fascination, and its victim, to her own great discomfort, goes on from time to time introducing more and more. In the case from which our illustration was taken, the patient was a neurotic girl, in whom the knee presented conditions suggestive of tubercular disease of the synovial membrane. It was considerably swollen, painful, and somewhat fixed. There was no material accumulation of synovial fluid. The Rays revealed the condition of things shown in our illustration. Mr. Robert Jones, under whose care she was, opened the joint by a large anterior flap, and with some trouble picked out no fewer than fifty-two needles and parts of needles.

(From the Jones-Morgan Collection.)

PLATE Z²

UNITED FRACTURE OF THE FEMUR IN ITS UPPER THIRD.

Sir Astley Cooper applied the term "horrible deformity" to the condition which is but too often left after fracture of the femur at the junction of its upper third with the middle one. Of this state, and of the exact position of the bones which attend it, we have in this Plate a graphic illustration. The upper fragment is tilted outwards by the action of the powerful muscles inserted into the trochanters, and the lower one, drawn upwards by the "movement en totalité" of the limb, rests against its inner aspect, with shortening of from two to three inches. The bones are united by a thick intervening bridge. Unfortunately, many, perhaps most, of our pathological museums contain specimens which illustrate this condition of things, and no hospital surgeon is without experience—possibly painful—of the extreme difficulty which attends the treatment of fractures at this position. It is to be hoped that the use of the X-rays at the time of adjustment may, by enabling us to ascertain the precise position of the fragments, and by demonstrating the uselessness of all expedients short of wiring, do much towards securing better results in the future.

We append an illustration of this deformity, but one in which the fracture is lower down than in the more characteristic cases.

PLATE Z³.

FRACTURE, BY DIRECT VIOLENCE, OF BOTH BONES OF THE LEG.

This radiograph exhibits the position of the bones after a crush of the leg in its lower third. There is shortening to the extent of nearly two inches, and overlapping of the fragments in corresponding degree. The fibula is broken transversely, and without comminution, but the tibia is shattered. Two considerable fragments are quite detached.

It is worth pointing out that if, under an anæsthetic, reduction could be so effected that the ends of the fibula were in end to end apposition, and the latter were then secured by the wire, the fragments of the tibia must of necessity fall into as good position as the conditions permitted of. There could, at any rate, if the fibula were its proper length and the limb straight, be no overlapping of the fragments of its fellow-bone.

(From the Jones-Morgan Collection.)

PLATE Z4.

FRACTURE OF THE METATARSAL BONE OF LITTLE TOE.

This Plate shows a fracture of the metatarsal bone of the little toe at about an inch from its upper end. The fracture is almost directly transverse, and is attended with some gaping on the outer side, but with no material displacement. The fracture was caused by indirect force, that is, from the weight of the body when standing. Mr. Jones, to whom we are indebted for the photograph, states that he has seen five similar cases, in all of which the fracture was at the same place, and occurred under the same conditions.

(*From the Jones-Morgan Collection.*)

00109545

Digitized with financial assistance from the
Observer Research Foundation
on 25 April, 2019